

A case report of uncommon manifestation of kala-azar with Association of hepatocellular- carcinoma

Dr. Ravishankar, S.N.¹ Dr. Vidyasagar, DUSI.²
Dr. Chandrasekhara, P.³

1 MVJ Medical college &
Research Hospital, Hosakote,
Bangalore
2 Postgraduate.

3 Prof.HOD. .

Correspondencia:

✉ dr.ravishankar.sn@gmail.com

Abstract

A 50 year old male resident of Bihar presented to MVJ Medical college hospital with h/o fever, Upper abdominal pain - on and off from 6 months. He was a known diabetic, on treatment.

Examination revealed Pallor, Icterus, Hepatomegaly, No splenomegaly, No Lymphadenopathy. USG confirmed the findings, Liver and Bone-marrow biopsy showed LD BODIES, with F/S/O Hepato-cellular carcinoma. Patient expired even after appropriate treatment.

Association of malignancy has been reported in literature, more in cutaneous Leishmaniasis, causing basal cell carcinoma and hematological malignancies.

The classical presentation of Kala-azar includes prolonged fever, splenomegaly, hepatomegaly, anaemia, weight loss and sometimes adenopathy. Atypical presentations can be equally challenging to the clinician like in our case.

Point of interest in this case is KALA-AZAR without splenomegaly and association with HEPATO- CELLULAR CARCINOMA.

Key words: visceral leishmaniasis, absence of splenomegaly, hepatocellular carcinoma.



This article is available from:
www.archivesofmedicine.com

Introduction

Leishmaniasis is a major public health problem in North East India, South India, Bangladesh, Nepal and other parts of the world.

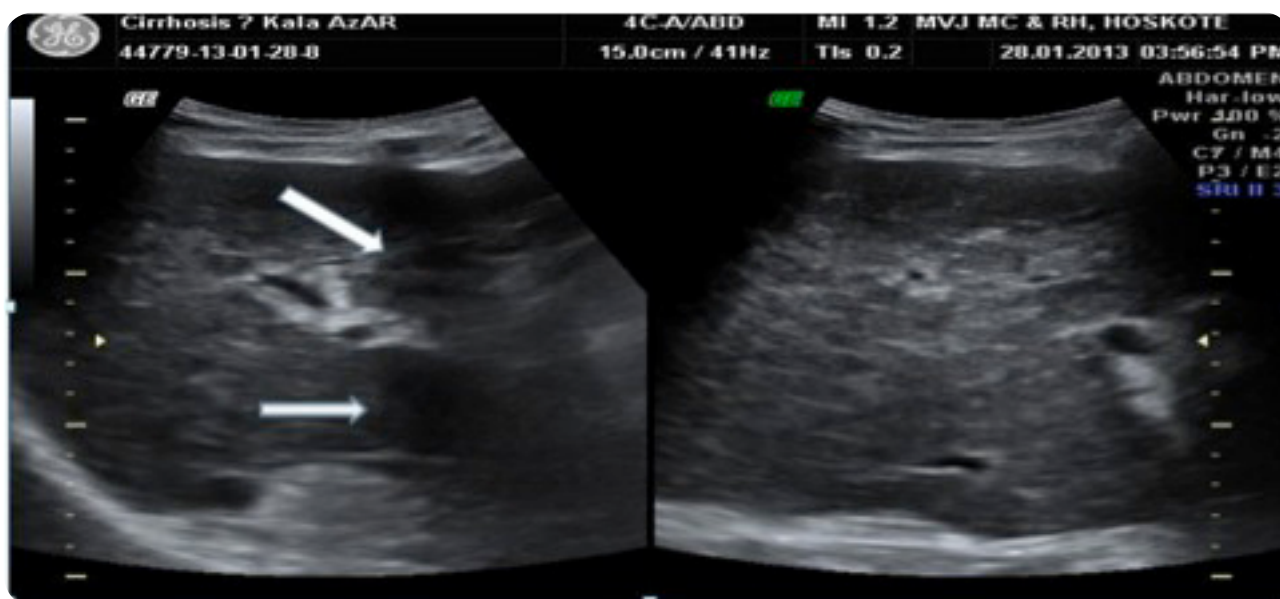
Visceral Leishmaniasis infection can remain subclinical or become symptomatic with an acute, subacute or chronic course. The classical presentation of Kala Azar includes prolonged fever, splenomegaly, hepatomegaly, anaemia, weight loss and sometimes adenopathy. Atypical presentations can be equally challenging to the clinician.

Association of malignancy has been reported in literature, more in cutaneous Leishmaniasis, causing basal cell carcinoma

We report an atypical presentation of kala azar without splenomegaly and only hepatomegaly. Evidence of Hepatocellular carcinoma was diagnosed in our case. Absence of splenomegaly and the association of visceral leishmaniasis with Hepatocellular Carcinoma was the most striking aspect in our patient.

Case report

An elderly T2DM male 50 yr, a resident of Bihar presented with c/o recurrent episodes of fever, recurrent episodes of pain abdomen since and generalized itching since one year. Fever is intermittent, moderate degree, associated with chills and no periodicity. Pain abdomen was continuous, dull aching, non specific. There was history of weight loss around 10kgs



in the last one year. The rest of the relevant history was negative. There were no similar complaints in the family members. Treatment history revealed that patient was regularly on diabetic medications and on analgesics and antipyretics for pain abdomen and fever.

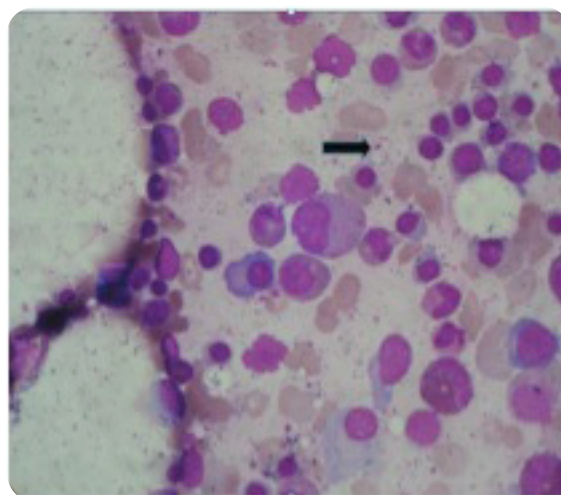
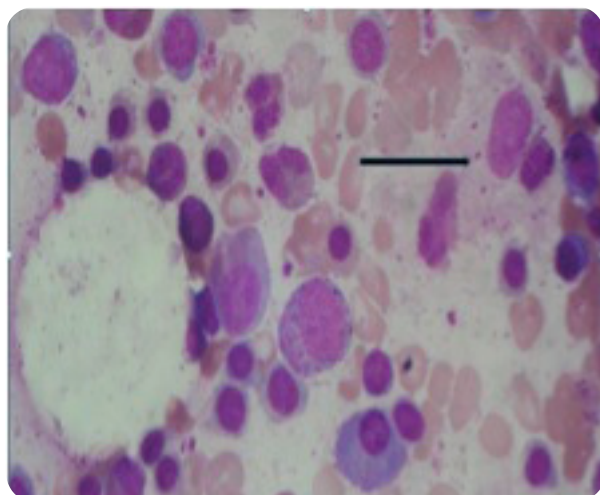
On examination patient was febrile, pallor and Icterus were present, no lymphadenopathy. Skin was dry with scratch marks and there were no signs of liver failure. On Per abdomen examination Liver palpable with a span of 18 cm, firm to hard in consistenc , sharp margins, nodular surface. Left lobe was more enlarged. Spleen was not palpable. Other systems examination was normal.

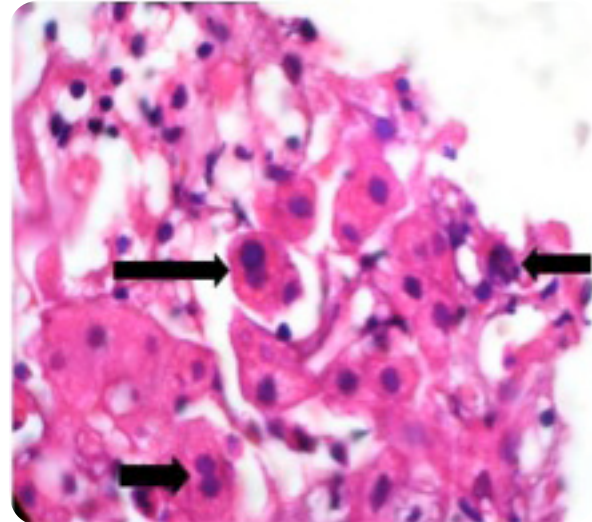
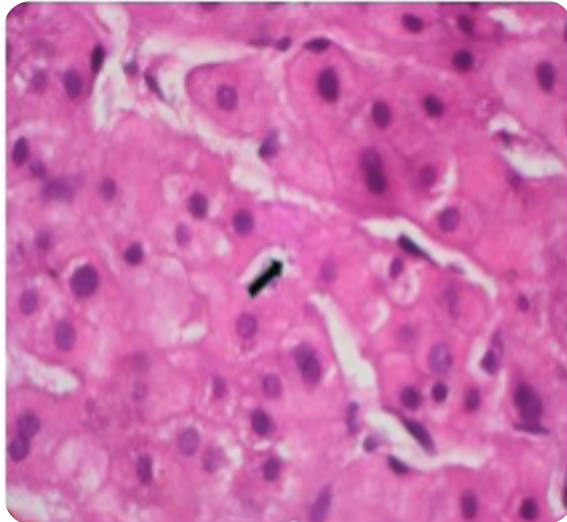
On investigation, heamoglobin was 10.1gm% and peripheral smear showed microcytic hypochromic pictur . The total and differential counts were normal and ESR was raised. Total serum bilirubin was 1.9 mg% and conjugated was 1.0mg%.

The transaminases were raised [SGOT-158 IU, SGPT-172 IU]. The alkaline phosphatase was 444-KAU. Total Serum proteins were 6.4gm% and albumin was 3.0gm%. Tests for enteric fever, leptospirosis, malaria, HIV, viral hepatitis (Band C)ewas inconclusive. Chest X-ray showed a normal study. Ultrasound abdomen showed features suggestive of Hepatomegaly with multiple hypoechoic foci? Multifocal HepatoCellular Carcinoma (HCC).

Bone marrow aspirate showed Intracellular and extracellular amastigotes (Leishmania Donovan bodies). Ultrasound guided liver biopsy demonstrated LD Bodies & increased mitotic figures inside liver cells suggestive of hepatocellular carcinoma.

Patient was started on Amphotericin B. patient showed improvement in the form of increased appetite and being afebrile. After the tenth day, patient had sudden death.





Discussion

Visceral leishmaniasis is a disease of the reticulo-endothelial system, commonly affecting the spleen, liver, lymph nodes and bone marrow. It is caused by the parasite *Leishmania donovani* & *L. infantum*. It is a chronic disease which evolves slowly. Incubation period is 2 to 6 months. The presence of amastigotes (*Leishmania* Donovan bodies) within macrophages remains the hallmark of *Leishmania* infection.

The classical presentation of Kala Azar includes fever, asthenia, weight loss, anemia, splenomegaly, hepatomegaly and sometimes adenopathy. Splenomegaly appears early and is almost invariably present. Spleen size increases gradually in relation to the duration of the disease. There was no splenomegaly in this patient both clinically and radiologically.

Badro et al. characterized the subclinical form having mild clinical manifestations lasting for more than three weeks which include fever, cough, diarrhea, malaise, mild hepatomegaly and eventually splenomegaly presenting as fluctuating course. Brandonisio et al, showed that leishmaniasis adversely affects the activation and function of macrophages and dendritic cells. This causes subsequent dysfunction of the immune system and a chance to permit the escape of continuously produced clones of malignant cells from efficient immune destruction resulting in malignancy.

Visceral leishmaniasis has been found in association with hematological malignancies in the literature, but the association with hepatocellular carcinoma which was seen in our case is not reported earlier.

References

1. Badaro, R., Jones, TC., Carvalho, EM., Sampaio, D., Reed, SG., Barral, A, et al. New perspectives on a subclinical form of visceral leishmaniasis. J Infect Dis. 1986; 154: 1003-11.
2. Sarker, CP. et al., Clinical profile of Kala-azar in adults: as seen in Mymensingh Medical College Hospital, Mymensingh, Bangladesh.
3. Quazi Tarikul, MI., Ahsan Habib, A., Haque, E. et al., Clinical And Infective Outcome of Parasitologically Confirmed Kalaazar Patients Treated With Sodium Antimony Gluconate. J Medicine 2010; 1 : 12-16
4. Badaro, R., Jones, TC., Carvalho, EM., Sampaio, D., Reed, SG., Barral, . et al. New perspectives on a subclinical form of visceral leishmaniasis. J Infect Dis. 1986; 154: 1003-11.
5. Brandonisio, O. et al, Dendritic cells in Leishmania infection. Microbes and Infection(200 ; 6: 1402-1409.
6. Ahasan, H.A.M.N. et al, Deaths in Visceral Leishmaniasis {Kala-azar} During Treatment. Med J Malaysia 1996; 51 (16).

Follow us:



Medicalia.org

Where Doctors exchange clinical experiences, review their cases and share clinical knowledge. You can also access lots of medical publications for free. Join Now!

<http://medicalia.ning.com/>

Publish with iMedPub

<http://www.imedpub.com>

- ✓ Archives of Medicine encompasses all aspects of medical science and clinical practice and cooperates closely with
- ✓ Archivos de Medicina, a Spanish-language open access journal.

Submit your manuscript here:

Archives of Medicine

<http://www.archivesofmedicine.com>

Archivos de Medicina

<http://www.archivosdemedicina.com>