

Cross Sectional Study of Clinical Profile and Treatment of Clubfoot by Ponseti Method among Infants at a Tertiary Care Hospital

Israr Ahmad^{1*}, Asad Ullah Mehmood¹, Kanwar Wasif Ali¹ and Hafiz Usman Jameel²

1 FCPS Orthopedics, Nishtar Hospital, Multan, Pakistan

2 PGR Orthopedics, Nishtar Hospital, Multan, Pakistan

*Corresponding author:
Israr Ahmad

✉ irfanravian51@gmail.com

Tel: +923113773799

FCPS orthopedics, Nishtar Hospital, Multan, Pakistan

Citation: Ahmad I, Mehmood AU, Ali KW, Jameel HU (2020) Cross Sectional Study of Clinical Profile and Treatment of Clubfoot by Ponseti Method among Infants at a Tertiary Care Hospital. Health Sci J. 14 No. 4: 726.

Abstract

Congenital Talipes Equinovarus (clubfoot) is the most common abnormality of foot. Mostly, clubfoot is idiopathic but various environmental and epidemiological factors have influenced the etiology of it. The aim of study was to access clinical profile and efficacy of Ponseti method of treatment in infants.

Methodology: It is a cross-sectional study conducted at orthopedic department, Nishtar medical university and hospital, Multan. Duration of study was 3 years, from 10th January 2016 to 10th January 2019. We included 58 (88 clubfeet) infants with age ranges from 2-12 months. Patients suffering from Arthrogryposis multiplex congenita, Meningomyelocele, spina bifida and had past surgical manipulation were excluded.

Results: There were 68.9% male and 31% female patients in our study. There were Bilateral 30 (51.7%) children with bilateral TEV while 28 (48.3%) patients with unilateral clubfoot. In our study, 70 percent of the feet were corrected with six serial casting. Achilles tenotomy was needed in 68 (77.2%) feet. We observed pre-treatment Pirani score 5.51 ± 0.62 while post treatment Pirani score was <0.5 . Excellent outcome was reported in 80 (91%) while remaining 9% left the treatment and didn't come for follow up. After evaluating birth history we found that 40 (68%) patients were born through spontaneous vertex delivery, 8 (13.7%) needed Caesarian section and 10 (17%) needed episiotomy to facilitate their births. In fifty (56.8%) patients the calf muscles were normal and among 38 (43.1%) were thin. There was no major complication noted.

Conclusion: Clubfoot among male is more common than female. There were equal number of cases with bilateral and unilateral clubfoot. Mode of delivery and positive family history had significant association with clubfoot. Patients with early presentation and low pretreatment Pirani score showed excellent outcome as compare to patient presented with high Pirani scoring. Ponseti technique showed excellent outcome in majority of patients in our study. Effective awareness campaigns and counselling of parents can show good compliance to treatment. Training of primary and secondary healthcare professionals should be done in order to calvefacilitate people and share burden of tertiary care hospitals.

Keywords: Talipes Equinovarus; Clubfoot; Pirani scoring; Ponseti treatment; Family history; SVD; Neglected

Received with Revision July 10, 2020, Accepted: July 23, 2020, Published: July 29, 2020

Introduction

Talipes Equinovarus is one the most common congenital musculoskeletal deformity that presents to the pediatric orthopedic surgeon [1,2]. Basically it involves all component of

musculoskeletal system i.e. bones, muscle, joints, tendon and ligaments. The primary deformities in club foot are Cavus (curve at medial arch), Adduction of forefoot, varus at hindfoot and Equinus at ankle joint [3,4]. There is abnormal relationship between Talus

and Tarsal bones, i.e. Tarsal bones adopt the position of flexion, medial rotation and inversion, while Talus is planter flexed [5]. These changes leads to equinus and varus of heel [6]. Soft tissues below the knee are shortened and contracted.

The exact causative factor for clubfoot is not fully elucidated yet, but there are many theories that favors both genetic and environmental factors are responsible [7]. Recent studies acknowledge the fact that illiteracy and poverty are some reasons due to which some affected children may remain neglected and it becomes more difficult to treat the deformity [8]. Other risk factors include oligohydramnios, family history, male baby, first baby, twin pregnancy. As clubfoot is an obvious deformity, no special investigation or screening program is required for its detection although it can be diagnosed prenatally by high resolution ultrasound during second trimester [6].

There are a number of classifications used to assess the severity of clubfeet, the most popular of them is Pirani scoring [9,10]. It gives 0-6 numbers i.e. six represents severe clubfoot and zero representing a normal foot. It is good because of inter-observer reliability and reproducibility [11]. Clubfoot in 90% to 98% of cases was successfully treated with nonsurgical technique i.e. Ponseti method [12,13]. Ponseti method of treatment is considered gold standard for clubfoot deformity [5]. Dr. Ponseti in 1950's first described this method and treated hundreds of children successfully. He treated patients with above-knee casting because it prevents the ankle and talus rotation and published his literature on clubfoot treatment by this method [14]. Before this literature was published, clubfoot was treated by complex surgical procedures which had a lot of complications like joint stiffness, pain, overcorrection along with high rates of recurrence [15]. This method has very less complications as compare to other surgical treatments [16]. Treatment should be started immediately as early treatment is simple and bears excellent results [17]. Treatment when started within 3 month of life, results are excellent, when started within six months of life, results are good and when started before walking age i.e. 12 to 15 months results are fair. After 9 months it becomes difficult to apply the cast as the children resist the cast, also the deformity becomes more and more rigid, so more casts are needed and the chances of residual deformity and additional treatment increases.

Ponseti treatment is made up of two phases

Treatment phase: The sequence of correction is first cavus second forefoot adduction and supination and in the last equinus and varus. Residual equinus is corrected with percutaneous tenotomy of tendoachilles [18].

Maintenance phase: In this step foot brace is used for 3-4 years in order to prevent reoccurrence [19].

Counsel to parents regarding the cast application is important and how many casts are needed depends on the severity of deformity [6]. The cast numbers required to achieve correction vary from three to nine and are changed weekly. Majority of patients may not get access to the treatment and those who do start treatment, miss their appointments, leave the treatment in casting phase or maintenance phase.

Sometimes manipulation and serial casting requires several months of treatment and often leads to incomplete or incorrect results [20]. Consequently, extensive corrective surgery is often indicated with problematic failures and complications [21]. Untreated or neglected clubfeet is defined as a clubfoot which has not received any form of (surgical and non-surgical) treatment upto 2 years of age [22]. Neglected clubfeet cause a lot of problems to the child include limping gait, unable to participate in certain activities especially sports, abnormal callosities, skin problems (repeated ulcers) leading to infection, pain resulting from early arthritis, problems in society, employment and cosmetic. It is therefore very important to treat this deformity in order to lead a normal life. There are certain psychological problems, which may arise due to structural differences in the children, they feel themselves handicap and inferior to other children. Otherwise, it causes heavy economic burden not only on the family but on the country as well. To facilitate parents we started club foot clinic in our hospital where all children of clubfoot are managed with Ponseti serial casting free of cost. Our study aimed toward evaluating the clinical profile and efficacy of the Ponseti approach to deal with congenital idiopathic clubfoot in our set-up.

Methodology

It is a cross-sectional study performed at orthopedic department of Nishtar Hospital, Multan. Duration of study was 3 years, from 10th January 2016 to 10th January 2019. This study was conducted after taking ethical Approval from Ethical review committee of our institution. We targeted all the patient upto 1 year of age came with Talipes Equinovarus in OPD of Orthopedics department. We included 58 patients with 88 clubfeet after explaining purpose of research, treatment course and schedule, including possibility of doing Achille's tendon tenotomy. Written consent was taken from all the parents and guardians. The details regarding antenatal care, previous abnormal child history, mode of delivery, parity, gender of the baby and history of consanguinity etc. were noted on proforma. Photographs and X-rays were taken in necessary situation. All infants were examined for any other associated deformity. Children with TEV were treated with Ponseti casting and foot abduction brace was recommended to all the patients after serial casting. Pre and post-casting Pirani score for all patients with clubfoot was calculated. Two days in a week were fixed for cast application in OPD so that patient's families could also interact with each other and share their experience.

Inclusion criteria

All new cases under 12 month of age were included in the study.

All patients with a minimum follow-up of three month were included.

Exclusion criteria

Patients presented after 1 year of age were excluded from this study.

Patients suffering from arthrogryposis multiplex congenita, Meningomyelocele and spina bifida were excluded.

Patients with past surgical intervention were excluded.

Frequencies and percentages of results were noted and later analyzed on Microsoft Excel.

Results

There are 58 patients with 88 clubfeet in our study. We included patients with age ranges from 2 to 11 months (mean age of 3.2 months). Most of the children were male 40 (68.9%) while female were 18 (31%) (Table 1). There were 30 (51.7%) children with bilateral TEV while unilateral right and left foot was affected in 12 (20.6%) and 16 (27.5%) respectively (Table 2). In our study 62 (70.4%) of the feet were corrected with six serial casting. Only 13 (14.7%) feet needed nine serial casts for clubfoot rectification (Tables 3-7). Achilles tenotomy was needed in 68 (77.2%) feet

Table 1. Gender distribution among 58 patients.

Gender	Frequency	Percentage
Male	40	69%
Female	18	31%

Table 2. Distribution of foot involvement.

	Male	Female	Total
Unilateral right foot	9 (15.5%)	3 (5%)	12 (20.6%)
Unilateral left foot	10 (17.2%)	6 (10.3%)	16 (27.3%)
Bilateral	21 (36.2%)	9 (15.5%)	30 (51.7%)
Total	40 (68.9%)	18 (3%)	58 (100%)

Table 3. Age at which patients presented for treatment.

Age of presentation	Frequency	Percentage
0-4 month	40	69%
5-8 month	12	20.6%
9-12 month	6	10.4%

Table 4. Mode of birth.

	Frequency	Percentage
Spontaneous vertex presentation	40	68%
C-section	8	13%
Normal delivery with episiotomy	10	17.2%

Table 5. Showing outcome as determined by Pirani score.

Pirani score	Frequency	Percentage
Excellent result	80	91%

Table 6. Results of some other important variables.

Percutaneous tenotomy of Achille's tendon	68	77.2%
Patients with calf abnormality (thin) n=88	50	56.8%
Patients with positive family history	10	17.2%
Pirani score before treatment	Range	Mean
	(3-6)	5.51±0.62
Pirani score after treatment i.e. < 0.5	Frequency	Percentage
	80	91%

Table 7. Number of cast required for correction in 88 feet.

No. of cast required	Frequency	Percentage
6	62	70.4%
7	8	9%
8	5	5.6%
9	13	14.7%

(Table 6). We observed pre-treatment Pirani score 5.51 ± 0.62 while post treatment Pirani score was <0.5 . Excellent outcome was reported in 80 (91%) while remaining 9% left the treatment and didn't come for follow up. After evaluating birth history we found that 40 (68%) patients were born through spontaneous vertex delivery, 8 (13.7%) needed Caesarian section and 10 (17%) needed episiotomy to facilitate their births. Fifty (56.8%) calf muscles were normal and 38 (43.1%) were thin. There was no major complication noted (Figures 1-7).

Discussion

It has been observed that approximately 250,000 infants born with foot disabilities each year worldwide, 80 % of such cases reported from developing countries and if these newborn remain untreated, it causes permanent disability, humiliation. Among such disabilities clubfoot can be easily and cheaply treated



Figure 1 Patient with bilateral clubfoot before treatment.

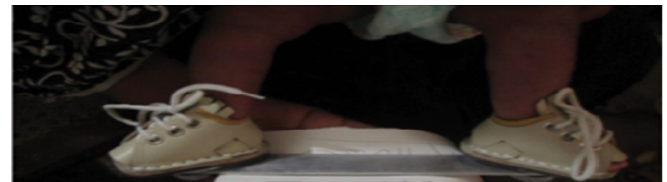


Figure 2 Patient with clubfoot after treatment.

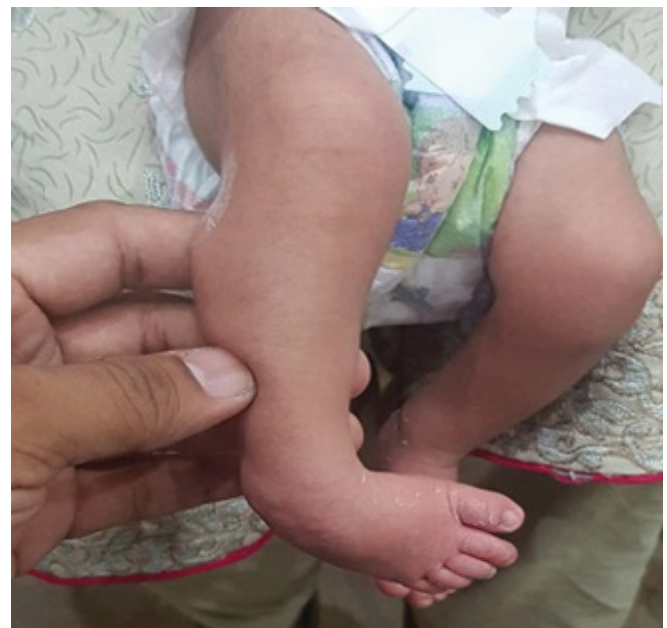

Figure 3 Infant with unilateral clubfoot.

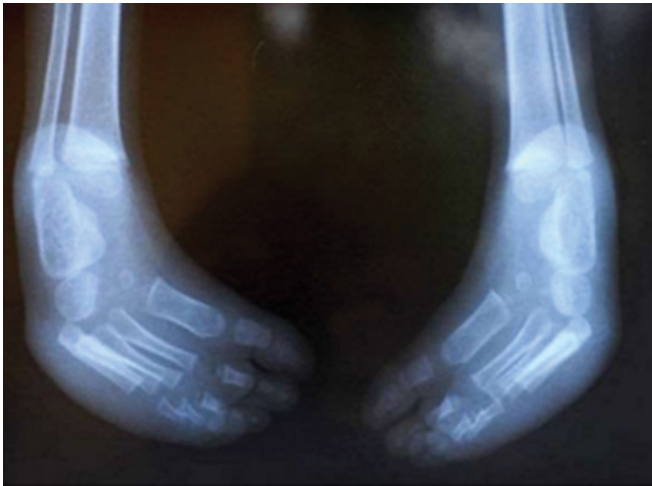

Figure 4 X-ray of infant with bilateral TEV.

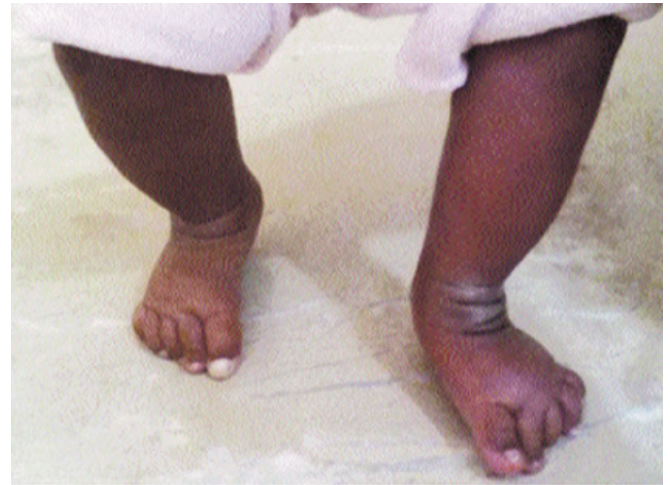

Figure 7 After completion of treatment with full correction of deformity.

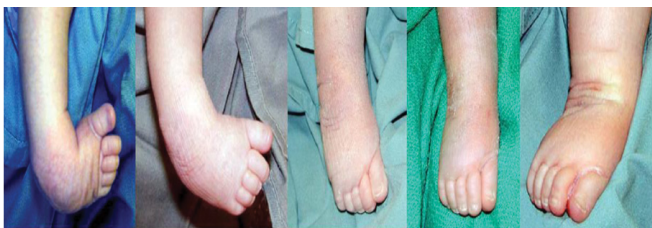

Figure 5 Ponseti method involves manipulation of foot from being adducted, inverted and flexed to being abducted and extended.

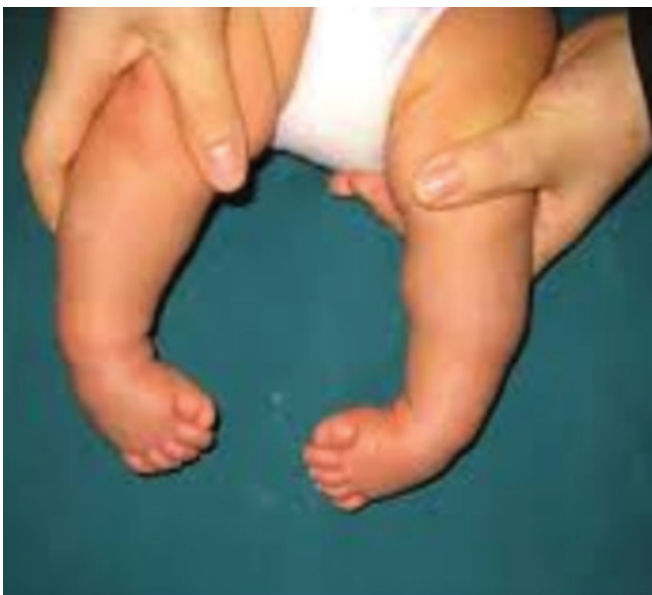

Figure 6 Bilateral clubfeet.

without surgery with the help of dedicated surgeons and parents [23]. But it is difficult for the parents to get treatment at their

doorstep as few orthopedic surgeons serve in rural areas and tertiary hospitals are a bit too far away. In Pakistan, a national program for the correction of TEV is there, but has not developed at district levels yet. In past, there is no study available which had discussed clubfeet specifically in infant in Pakistan. In our study the age of presentation for the treatment was 2 months to 1 year. It was possible due to systemized treatment facility available at our center and awareness among parents early treatment shows excellent results. Hussain et al [24] studied 220 patients with age ranges from 6 weeks to 3 years.

From different studies it was discovered that club foot is more common in males. Wynne-Davis (England) in his study reported male to female ratio of 2.17:1 among 635 patients [25]. Morokawa from Japan observed more male to female with ratio of 2.2:1 [26]. Our study shows almost similar results to past studies with more male as compared to female i.e. 2.2:1. However, a national review of clubfoot management from Scotland observed more female to male with ratio of 5:2 [27].

In this study positive family history was present in 10 (17.2%) patients. Similarly, Sami A.L recorded positive family history in 11% patients [28]. Hussain SA from Pakistan reported 57.14% patients having positive family history [24]. Many studies recorded a substantial number of patients have previous family history of TEV which varies between different populations.

By comparing mode delivery in our study with other studies, we found that mode of delivery is an important factor in etiology of clubfoot. Chesney D et al reported method of delivery in 198 patients with clubfoot and noted 123 (62.2%) were delivered through SVD and 38 (19.2%) through caesarean section [27]. Sami A.L reported mode of delivery among 104 patients with Talipes Equinovarus and observed 73 patients presented through SVD, 14 required caesarean section and 17 required episiotomy to facilitate their births [28].

Talipes Equinovarus may present unilaterally or bilaterally. Different studies showed different results. A study from Japan reported bilateral and unilateral case of club foot deformity in

equal numbers [29]. Chesney D from United Kingdom in 2002 reported unilateral (55%) clubfoot was more common than bilateral clubfeet 45% [27]. Hussain SA studied 70 patients with Talipes Equinovarus from KPK, among them 23 (32.8%) patients had bilateral and 47 (67.2%) had unilateral clubfoot [24]. But Cardy AH in 2007 reported 51% bilateral and 49% unilateral club foot deformity [30]. In current study of 58 patients with TEV, there were almost equal number of unilateral and bilateral clubfoot i.e. 28 and 30 respectively.

In our study Achilles tenotomy was performed in 68 (77.2%) feet which is less as compare to some other studies [31]. It was observed that patient having high pretreatment Pirani scores were more likely to undergo Achilles tenotomy. Gupta [31] did tenotomy in 95% of his clubfeet and Dobbs [15] in 91% of his patients. Bor [32] is of the opinion that clubfeet requiring more casts for correction are more likely to be needing some surgical intervention in future.

Mean number of casts required in our study was 6.21 ± 1.43 (Range 6-9) which was similar to other studies [16,31]. We were able to achieve correction of the deformity in 80 (91%) feet out of 88. Similar results have been shown by Kampa et al [33] and Morcuende et al [34].

We had very less noncompliant patient in our study because of totally free treatment, friendly environment and better counselling of parents so that maintain compliance. Therefore, 91% of our children had fully corrected feet and they are still in rehabilitation phase using the Dennis Brown splint. Noncompliance has been widely reported to be the main factor causing failure of the treatment [15].

Ponseti method has now become the gold standard for the treatment of clubfoot globally, because it is non-surgical, easy, effective, inexpensive and having successful correction rate of 90-98% [4]. Ponseti method has low rate of complication and chances of recurrence. Grimes et al found Ponseti casting for TEV patient as an inexpensive method of treatment that is less than 10th of the cost of other treatment methods [12,13]. A study conducted in India had 356 cases with 402 feet with congenital TEV who were treated by Ponseti method and showed good functional outcome in 95.45% cases [35]. Ponseti clubfoot management techniques have reduced the need for extensive soft tissue release and major clubfoot surgery. In this method serial casting is required to correct deformity which is easy to learn by allied health professionals. It can be carried out in small health units so that their respective local population may also get benefit from this procedure. Several workshops by senior orthopedic consultant have been carried out in order to train other doctors. Different researchers have different opinions regarding the age at which treatment should be initiated but majority of them suggest starting as soon after birth as possible to get better results [36,37]. Most of the clinicians, and research shows good results in children up to age 2 years. Most of neonates in our study were less than 2 months of age and this can be attributed

to better awareness of public through electronic and print media made by our department in our locality and hospital. We included children up to 1 years of age in our study and all of the children had equivalent chances of the successful treatment. The Pirani score before and after correction was similar to previously reported studies i.e. 3-5 and <0.5 respectively [16,38]. Every clinician should keep few points while treating clubfoot i.e. do not apply counter-pressure on the calcaneocuboidal joint, which may be the main reason behind the failure of the treatment or recurrence of the deformity. This prevents the movement of calcaneus under the talus, which is a fundamental motion for the correction of deformity. As the three tarsal bones move together, the pressure on calcaneocuboidal joint in turn prohibits the motion of talonavicular joint. This makes it impossible to rectify the clubfoot. Similarly, application of extra force to treat the deformity also leads to failure in achieving the desired results. This extra force leads to pain and crying, which causes muscle stress in lower extremities, making manipulation and casting difficult. The main objective is no doubt to achieve a plantigrade, painless foot and normal gait, so that child can be relieved from pain, easy fatigability, psychological, social, cosmetic, sports, and sometimes failure to find an appropriate job [31]. To make all this possible, it is very important to rule out causes and address them such as, lack of screening programs, home deliveries, lack of resources and infrastructure, poor means of transport, non-availability of orthopedic doctor who may screen child for clubfoot and lack of awareness in pediatricians, general physicians and also parents of the babies. We recommend a series of workshops and awareness campaign throughout Pakistan to improve the treatment of this condition. These campaigns and workshops will expected to bring a very positive change in the treatment of clubfeet, and not only parents will be ready to accept and start casting soon after birth but the medical personnel will have adequate knowledge and skill to treat this condition safely.

Conclusion

Clubfoot among male is more common than female. There were equal number of cases with bilateral and unilateral clubfoot. Mode of delivery and positive family history had significant association with clubfoot. Patients with early presentation and low pretreatment Pirani score showed excellent outcome as compare to patient who presented with high Pirani score. Ponseti technique showed excellent outcome in majority of patients in our study. It is an easy and cost effective technique and usually has no complications as compare to extensive surgical techniques. Effective awareness campaigns and counselling of parents can show good compliance to treatment. We recommend that primary and secondary healthcare professionals should be trained in this method so that burden of tertiary care could be shared and maximum people may get benefit from their local healthcare centers.

Conflict of Interest: None.

Sources of Funding: None.

References

- 1 Herring JA (2014) Tachdjian's pediatric orthopedics (5th edn). Philadelphia, PA: Saunders Elsevier.
- 2 Jowett CR, Morcuende JA, Ramachandran M (2011) Management of congenital talipes equinovarus using the Ponseti method: a systemic review. *J Bone Joint Surg Br* 93: 1160-1164.
- 3 Manaster BJ (1996) Congenital foot anomalies. In hand book of skeletal radiology 1996: 338-349.
- 4 Miedzybrodzka Z (2003) Congenital Talipes equino-varus (club foot) a disorder of the foot but not the hand. *J Anat* 202: 37-42.
- 5 Mahan ST, Spencer SA, May CJ, Prete VI, Kasser JR (2017) Club foot relapse: does presentation differ based on age at initial relapse? *J Child Orthop* 11: 367-372.
- 6 Staheli L (2009) Clubfoot: ponseti management. Global HELP Organization.
- 7 Chesney D, Barker S, Miedzybrodzka Z, Haites N, Maffulli N (1999) Epidemiology and genetic theories in the etiology of congenital talipes equinovarus. *Bull Hosp Joint Dis* 58: 59-64.
- 8 Evans AM, Chowdhury MM, Kabir MH, Rahman MF (2016) Walk for life-the National Clubfoot Project of Bangladesh: the four-year outcomes of 150 congenital clubfoot cases following Ponseti method. *J Foot Ankle Res* 9: 42.
- 9 Dyer PJ, Davis N (2006) The role of the Pirani scoring system in the management of club foot by the Ponseti method. *J Bone Joint Surg Br* 88: 1082-1084.
- 10 Pirani S, Outerbridge HK, Sawatzky B, Stothers K (1999) A reliable method of clinically evaluating a virgin clubfoot evaluation. In: Proceedings of the 21st SICOT conference.
- 11 Siapkara A, Duncan R (2007) Congenital talipes equinovarus: a review of current management. *J Bone Joint Surg Br* 89: 995-1000.
- 12 Cooper DM, Dietz FR (1995) Treatment of idiopathic clubfoot. a thirty-year follow-up note. *J Bone Joint Surg Am* 1995;77:1477-89.
- 13 Maripuri SN, Gallacher PD, Bridgens J, Kuiper JH, Kiely NT (2013) Ponseti casting for club foot - above- or below-knee? A prospective randomised clinical trial. *Bone Joint J* 95B: 1570-1574.
- 14 Ponseti IV, Smoley EN (1963) Congenital club foot; the results of treatment. *J Bone Joint Surg Am* 45: 261-344.
- 15 Dobbs MB, Nunley R, Schoenecker PL (2006) Long-term follow-up of patients with clubfeet treated with extensive soft-tissue release. *J Bone Joint Surg Am* 88: 986-996.
- 16 Porecha MM, Parmar DS, Chavda HR (2011) Mid-term results of Ponseti method for the treatment of congenital idiopathic clubfoot- (a study of 67 clubfeet with mean five year follow-up). *J Orthop Surg Res* 6: 3.
- 17 Morcuende JA, Dolan LA, Dietz FR, Ponseti IV (2004) Radical reduction in the rate of extensive corrective surgery for clubfoot using the Ponseti method. *Pediatrics* 113: 376-380
- 18 Kampa R, Binks K, Dunkley M, Coates C (2008) Multidisciplinary management of club feet using the Ponseti method in a district general hospital setting. *J Child Orthop* 2: 463-467.
- 19 Gerlach DJ, Gurnett CA, Limpaphayom N, Alaei F, Zhang Z (2009) Early results of the Ponseti method for the treatment of clubfoot associated with myelomeningocele. *J Bone Joint Surg Am* 91: 1350-1359.
- 20 Dimeglio A, Bonnet F, Mazeau P, de Rosa V (1996) Orthopaedic treatment and passive motion machine: consequences for the surgical treatment of clubfoot. *J Pediatr Orthop B* 5:173-180.
- 21 Ponseti IV (1992) Treatment of congenital club foot. *J Bone Joint Surg Am* 74: 448-454.
- 22 Sengupta A (1987) The management of congenital talipes equinovarus in developing countries. *Int Orthop* 11: 183-187.
- 23 Beaty JH (2007) Congenital anomalies of the lower extremity. In: Canale T, Beaty JH (editors) Campbells operative Orthopaedics (11th edn). Philadelphia, Pennsylvania: Mosby Elsevier, pp: 1079-1100.
- 24 Hussain SA, Khan MS, Ali MA, Shahabuddin (2008) Modified turco's postero-medial release for congenital talipes equino-varus. *J Ayub Med Coll Abbotabad* 20: 78-80.
- 25 Wynne-Davis R (1964) Family studies and the cause of club foot. Talipes Equinovarus, Talipes Calcaneo-Valgus And Metatarsus Varus. *J Bone Joint Surg Br* 46: 445-463.
- 26 Gen M, Hisater N, Rehnburg L (2001) Epidemiology of congenital club foot in Japan and Sweden. *Journal of Japanese Orthopaedic Association* 10: 198-205.
- 27 Chesney DJ, Barker SL, Macnicol MF, Porter RW, Maffulli N (2004) Management of Congenital Talipes Equino varus in Scotland: A Nationwide Audit. *The Surgeon* 47-51.
- 28 Sami AL, Hanif A, Massod F, Awais SM (2010) Cross sectional study of club foot at tertiary care hospital. *Annals of King Edward Medical University* 16: 20.
- 29 Yamamoto H (1979) A Clinical, genetic and epidemiological study of congenital club foot. *J Hum Genet* 24: 37-44.
- 30 Cardy AH, Barker S, Chesney D, Sharp L, Maffulli N, et al. (2007) Pedigree analysis and epidemiological features of Idiopathic congenital Talipes Equinovarus in United Kingdom. *BMC Musculoskeletal Disord* 8: 62.
- 31 Gupta A, Singh S, Patel P, Patel J, Varshney MK (2008) Evaluation of the utility of the Ponseti method of correction of clubfoot deformity in a developing nation. *Int Orthop* 32: 75-79.
- 32 Bor N, Coplan JA, Herzenberg JE (2009) Ponseti treatment for idiopathic clubfoot: Minimum 5- year followup. *Clin Orthop Relat Res* 467: 1263-1270.
- 33 Kampa R, Binks K, Dunkley M, Coates C (2008) Multidisciplinary management of clubfeet using the Ponseti method in a district general hospital setting. *J Child Orthop* 2: 463-467.
- 34 Morcuende JA, Dolan LA, Dietz FR, Ponseti IV (2004) Radical reduction in the rate of extensive corrective surgery for clubfoot using the Ponseti method. *Pediatrics* 113: 376-380.
- 35 Malhotra R, Mohapatra A, Arora G, Choudhury P, Joshi H, et al. (2018) Ponseti technique for the management of congenital Talipes equinovarus in a rural set-up in India: experience of 356 patients. *Children (Basel)* 5: 49.
- 36 Spiegel DA, Shrestha OP, Sitoula P, Rajbhandary T, Bijukachhe B, et al. (2009) Ponseti method for untreated idiopathic clubfeet in Nepalese patients from 1 to 6 years of age. *Clin Orthop Relat Res* 467: 1164-1170.
- 37 Dyer PJ, Davis N (2006) The role of the Pirani scoring system in the management of club foot by the Ponseti method. *J Bone Joint Surg Br* 88: 1082-1084.
- 38 Jaqueto PA, Martins GS, Mennucci FS, Bittar CK, Zabeu JLA (2016) Functional and clinical results achieved in congenital club foot patients treated by Ponseti's technique. *Rev Bras Ortop* 51: 657- 661.