

# Evisceration of Small Intestine through the Vagina: A Rare Surgical Cause of Acute Intestinal Obstruction

**Bendjaballah A\*, Taieb M, Haidar A, Khiali R, Ammari S, Khetra Z and Nait Slimane M**

Department of General Surgery, Ain Taya Hospital, Algiers, Algeria

\*Corresponding author: Bendjaballah A, Department of General Surgery, Ain Taya Hospital, Algiers, Algeria, Tel: +213 551 764 640; E-mail: ali\_bendjaballah@yahoo.fr

Received date: April 03, 2020; Accepted date: May 20, 2020; Published date: May 27, 2020

Citation: Bendjaballah A, Taieb M, Haidar A, Khiali R, Ammari S, et al. (2020) Evisceration of Small Intestine through the Vagina: A Rare Surgical Cause of Acute Intestinal Obstruction. J Univer Surg. Vol.8 No.3: 1

## Abstract

In emergency surgical admissions, acute bowel obstruction is a very common problem. The causes of bowel obstruction are numerous but the most frequently identified are adhesions and post-operative bands, hernias, tumours and congenital bands. Evisceration of the small intestine through the vagina is a rare surgical emergency that requires urgent surgery because of the risk of developing acute small bowel obstruction and ischemia. We report a very rare and unusual case of an acute abdomen with bowel obstruction in a 70-year-old non-hysterectomized woman, with the majority of the small bowel visible outside the vagina, which has become strangulated and gangrenous. An exploratory laparotomy was performed urgently with resection and anastomosis of the small bowel and closure of the breach in the Douglas pouch. Multiple approaches to surgical management have been described, including laparoscopy, laparotomy, transvaginal route, and combined approaches. Perineal hernia should be considered in the differential diagnosis in elderly post-hysterectomy patients with sudden onset of abdominal pain where urgent surgical intervention is advised.

## Keywords

Surgical emergency; Acute bowel obstruction; Trans vaginal evisceration; Resection and anastomosis; Breach in the Douglas pouch

## Introduction

In elderly women, transvaginal evisceration of the small intestine is a rare but potentially fatal emergency that requires urgent surgical intervention to reduce morbidity and mortality. Risk factors for this event include advanced age, enterococcal disease, and prior transvaginal surgery. Prolapse of the uterus with or without cystocele or rectocele is a frequent observation, but patients with very significant anterior and posterior vaginal enterocele without uterine prolapse or a history of hysterectomy are rare and exceptional. Cystocele,

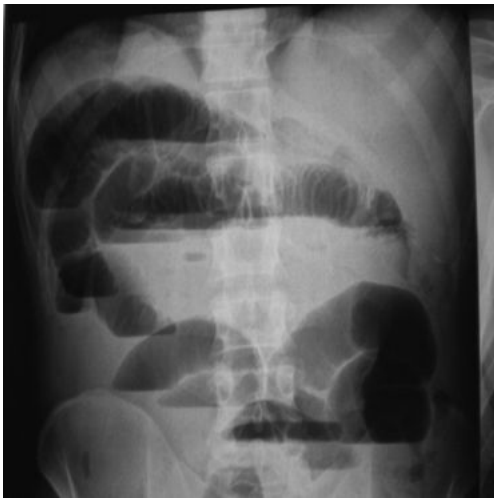
rectocele, uterine prolapse, and enterocele occur as a result of pelvic floor weakness or defect, mainly in postpartum or after pelvic surgery. They usually present as small bowel obstruction on imaging or diagnostic laparotomy showing small bowel herniation in the vagina [1]. Rarely, it presents dramatically with large loops of small intestine prolapsing into the vagina, causing significant abdominal discomfort and an acute risk of intestinal strangulation [2].

## Case Presentation

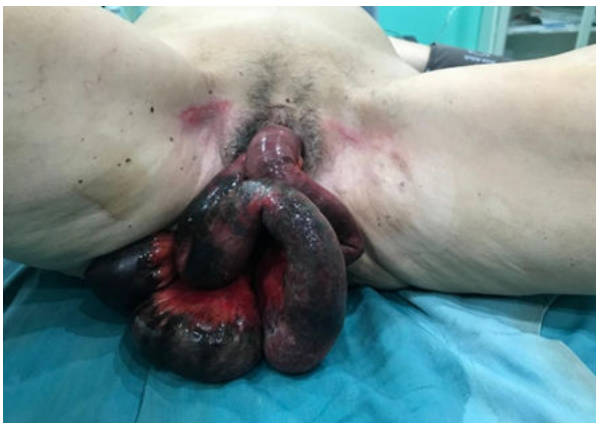A 70-year-old female patient with history of hypertension who presented with sudden onset of severe abdominal pain described as sharp and at an intensity that she had never experienced before. The patient did not report any notion of constipation or a coughing episode that might have increased intra-abdominal pressure. On admission her General condition was very poor, febrile, dehydrated, anemic, pulse 104/min and BP 100/70 mm, chest, cardio vascular system, central nervous system normal. Per abdominal examination revealed gross distention of abdomen, tenderness, guarding, rigidity all over abdomen and bowel sounds were absent. Perineal examination shown a large anterior enterocele (misdiagnosed by gynecologists as cystocele) and posterior enterocele. Her blood investigations: Hb was 10,9 g%, WBC 12800 /cmm, blood urea 52 mg/L serum creatinine 12 mg/L serum electrolytes Na<sup>+</sup> 125 mEq/L., K<sup>+</sup> 2.5 mEq/L, while ECG showed sinus tachycardia changes. X-ray abdomen showing multiple air fluid levels (**Figure 1**).

Examination of the perineum revealed significant prolapse of the small intestine with at least 100 cm of small intestine protruding through the vagina, the loops appearing edematous and the mesentery was ecchymotic with signs of necrosis (**Figure 2**). It was impossible to insert a urinary catheter (Foley catheter) and perform a rectal examination due to the amount of bowel covering the perineal area. After a short resuscitation and rapid anesthetic evaluation she was operated on in emergency. A midline laparotomy was performed and the bladder was found to be distended. The small bowel loops were reduced, several bowel loops were gangrenous and necrotic and required resection with terminal anastomosis (60 cm of the small bowel was resected). A defect

in the retro uterine region (Douglas pouch) was found and closed. It was the cause of this condition.



**Figure 1:** Abdominal X-ray showing multiple air-fluid levels.



**Figure 2:** Edematous loops of small bowel hanging outside the vagina with dusky appearing mesentery.

## Discussion

Transvaginal intestinal prolapse is a rare surgical condition that was first described by Hypernaux et al in 1864. There are 100 cases reported in the literature. Vaginal prolapse frequently occurs at the same time as posterior vaginal enterocele [3]. About 70% of patients are postmenopausal women. 73% have had previous vaginal surgery and 63% have developed enterocele. This increased incidence in postmenopausal women has been associated with decreased vascularization and vaginal wall atrophy. In pre-menopausal women, it is related to sexual activity and vaginal trauma [4,5].

Special attention must be made to distinguish between a prolapse of the vaginal cavity and an anterior vaginal prolapse, i.e., cystocele, cysto-urethrocele, or posterior prolapse, i.e., rectocele. In addition, loss of the upper suspensory fibres of the paracolpium and parametrium has been observed to result

in uterine and vaginal prolapse after hysterectomy [6], whereas in non-hysterectomized women, stretching of the utero-sacral ligaments due to natural connective tissue weakness is observed. Transverse or longitudinal rupture of the fascia at the vaginal apex may result in prolapse of the vaginal cavity. In the enterocele, the parietal peritoneum comes into direct contact with the vaginal epithelium without intermediate fascia [7] and occasionally uterine prolapse is observed after hysterectomy known as drive enterocele [8]. The risk factors encountered in older women are vaginal surgery, enterocele repair, increased intra-abdominal pressure with ascites, constipation and increased coughing attacks. Other risk factors include perineal proctectomy and previous pelvic radiotherapy [9]. In post-radiation lesions, there is evidence of inflammation and pain. After radiation therapy, there are changes in progressive obliterative endarteritis manifested by hypoxia and hypocellularity in the tissues. Patients with gynecological malignancies due to dehiscence of the vaginal cuff are also at increased risk [2]. Many cases of acute small bowel obstruction with vaginal cavity prolapse or evisceration after hysterectomy were reported in the literature. However, these cases are rare (as in our patient), since there is no history of hysterectomy and there was a rare anterior and posterior enterocele with obstruction and strangulation of the small bowel, gangrene, and perforating peritonitis. In the literature, a number of cases of obstructed eviscerated enterocele with or without gangrene have been reported although gangrene not including evisceration of the small bowel in the anterior and posterior enterocele has not been well known to date [10]. In a series of 490 cases of prolapse, there were 193 cases of enterocele, of which only 3 were anterior enterocele [11]. Many patients have stress urinary incontinence, dyspareunia, constipation, or symptoms of bowel obstruction. They may require investigations such as defecography, cystoproctography or MRI to confirm the clinical diagnosis, but these patients are often seen in emergencies and require immediate management. [12,13]. Patients usually complain of pelvic or vaginal pain, vaginal bleeding, and a feeling of a mass in the vaginal vault. The terminal ileum is most often the protruding viscera, although other organs, such as the omentum, salpinx and epiploid appendices, have also been described [1]. Transvaginal evisceration of the small intestine is an absolute surgical emergency and is generally associated with a 6-8% mortality rate. Urgent reduction and reintroduction of the small bowel must be undertaken and in rare cases, if the small bowel is not compromised, the reduction procedure may be performed through transvaginal approach [6]. The high morbidity associated with this complication is about 15% and 20% of patients which require bowel resection. The treatment of choice is to reduce evisceration, if intestinal vascularity is compromised, resection and anastomosis with suspension of the vault and closure of the Douglas' pouch defect. Different strategies have been chosen for the colporrhaphy (obliteration of the Douglas pouch) these are-

- Trans-abdominal [10,15]
- Trans-vaginal [6,7,10,14,15]
- Laparoscopic [7].

In all the different approaches, the value of using colporrhaphy to prevent recurrences and for the correct repair of the pelvic fascia during any vaginal or pelvic operation has been stressed. [16].

If the bowel is easily reducible, has not been previously irradiated and there are no signs of an acute abdomen, a vaginal approach may be a possible option [17]. In general, both vaginal and abdominal procedures have equivalent recurrence and complication rates. Therefore, either approach may be used depending on the patient's presentation [9].

## Conclusion

Early detection and surgical management of this rare surgical emergency is absolutely necessary to prevent the occurrence of small bowel ischemia requiring resection. In elderly and at-risk patients, uterine prolapse, prolapse of the vaginal vault, cystocele, rectocele, and a combination of two or more of these are often observed. There are also patients with herniation of the small bowel in the pelvic floor, called posterior enterocele, or in patients who have had a hysterectomy. All of these patients require prior reduction of evisceration, and especially repair of the pelvic floor and obliteration of the Douglas pouch or in some cases a vaginal closure in order to prevent recurrences. A pelvic floor hernia through the anterior vagina called anterior enterocele is very rare, and having anterior and posterior enterocele in the same patient is an exceptional type of pelvic hernia, which is also present in non-hysterectomized patients.

## References

- Kang WD, Kim SM, Choi HO (2009) Vaginal evisceration after radical hysterectomy and adjuvant radiation. *J Gynecol Oncol* 20:63-64.
- Narducci F, Sonoda Y, Lambaudie E, Leblanc E, Querleu D (2003) Vaginal evisceration after hysterectomy: The repair by a laparoscopic and vaginal approach with a omental flap. *Gynecol Oncol* 89:549-551.
- Holley RL (1994) Enterocele review. *Obstetrics Gynecol Surv* 49:284-293.
- Laalim SA, Tourghai I, Ibnmejdoub K, Mazaz K, Raghy S, et al. (2013) Primary vaginal adenocarcinoma of intestinal type: Case report and review of literature. *Pan Afr Med J* 15:10.
- Parra RS, Rocha JJ, Feres O (2010) Spontaneous transvaginal small bowel evisceration: A case report. *Clinics* 65:10.
- Carter JE (2000) Enterocele repair and vaginal vault suspension. *Curr Opin Obstet gynecol* 12:547.
- Miklos JR, Moore RD, Kohli N (2004) Laparoscopic pelvic floor repair. *Obstet Gynecol Clin North Am* 31:551-565
- Zacharin RF, Hamilton NT (1980) Pulsion enterocele, longterm result of an abdominoperineal technique. *Obst Gynecol* 55:141-148.
- Ramirez PT, Klemer DP (2002) Vaginal evisceration after hysterectomy: A literature review. *Obstet Gynecol Surv* 57:462-467.
- Kowalski LD, Seski JC, Timmins PF, Kanbour AI, Kunschner AJ, et al. (1996) Vaginal evisceration: Presentation and management in postmenopausal women. *J Am Coll Surg* 183:225-229.
- Tulikangas PK, Lukban JC, Walters MD (2004) Anterior enterocele: A report of three cases. *Int urogynecol J Pelvic Floor Dysfunction* 15:350-352.
- Tulikangas PK, Walters MD, Brainard JA, Weber AM (2001). Enterocele: Is there a histologic defect ?. *Obstet Gynecol* 98:634-637.
- O'Brien LM, Bellin LS, Isenberg GA, Goldstein SD (2002) Spontaneous transvaginal small-bowel evisceration after perineal proctectomy: Report of a case and review of the literature. *Dis Colon Rectum* 45:698-699.
- Eilber KS, Rosenblum N, Gore J, Raz S, Rodríguez LV (2006) Perineocele: Symptom complex, description of anatomic defect, and surgical technique for repair. *Urology* 67: 265-268.
- Maher C, Baessler K, Glazener CM, Adams EJ, Hagen S (2008) Surgical management of pelvic organ prolapse in women: A short version Cochrane review. *Neurourol Urodyn* 27:3-12.
- Mehta D, Shaam MB, Yadav JK (2010) Rare cause of intestinal obstruction—Vaginal enterocele. *Indian J Surg* 72:104-106.
- Rana AM, Rana A, Salama Y (2019) Small bowel visceration through the vaginal vault: A rare surgical emergency. *Cureus* 11: e5947.