

Hereditary Hemorrhagic Telangiectasia: Presenting with Epistaxis. A Case Report

Sandeep Kumar Kar¹,
Manasij Mitra²,
Tanmoy Ganguly³,
Manabendra Sarkar⁴,
Chaitali Sen Dasgupta⁵ and
Anupam Goswami⁶

Introduction

Osler-Weber-Rendu disease (OWRD) or Hereditary Hemorrhagic Telangiectasia (HHT) is a rare autosomal dominant disorder that causes muco-cutaneous and visceral vascular dysplasia and results in increased tendency for bleeding [1-4]. Patients with HHT may present with variety of symptoms and management differs accordingly. Epistaxis is the most common symptom of HHT and mucocutaneous telangiectasia the most common sign [5]. Here we describe the anesthesia management of a patient presenting with epistaxis in emergency suffering from this syndrome.

Case Report

A 50 year old male patient of Indian origin came to the emergency with severe epistaxis. Past history and records revealed recurrent epistaxis with definitive positive family history and telangiectasia over nasal mucosa and paranasal sinuses. He had been diagnosed previously as HHT due to presence of vascular malformation in the nose and paranasal sinuses by endoscopy and stomach by upper GI endoscopy. After admission his blood pressure was 90/60 mm Hg, pulse 124/minute, room air SaO₂ 96%. Investigation revealed Hb 6.5 gm/dl, PCV 16 gm/dl. Chest auscultation revealed no crepitation and bilateral vesicular breath sound was present. He was stabilised with 500 ml hydroxyl-ethyl starch till blood products were made available, followed by 3 unit packed cell and 4 unit FFP transfusion. Patient received tranexamic acid 1 gm slow I.V infusion to control the bleeding, glycopyrrolate to reduce secretions, pantoprazole as antiulcer prophylaxis and Ondansetron to reduce reflux. Along with resuscitation, surgical exploration with control of bleeding under general anesthesia was planned. As blood in stomach was a possibility and patient's fasting status was unknown, rapid sequence induction was carried out with thiopentone 5 mg/kg and succinylcholine 2 mg/kg and trachea was intubated with a 8.5 mm I.D. cuffed portex endotracheal tube. A urinary catheter was inserted and orogastric tube aspiration was done. Maintenance of anesthesia was done with sevoflurane, nitrous oxide and oxygen, and atracurium as a muscle relaxant. Several telangectasias were found over the anterior part of the nasal septum which was thoroughly cauterized with diathermy under endoscopic guidance. This was followed by septo-dermoplasty to stop the bleeding. Intraoperatively tranexamic acid was given (1 gm) along with local packing with lignocaine and adrenaline mixture. Intraoperatively controlled hypotension was induced with sevoflurane and propofol boluses to maintain systolic blood pressure between 90 to 100 mmHg.

- 1 Assistant Professor, Department of Cardiac Anaesthesiology Institute of Postgraduate Medical Education & Research, Kolkata, India
- 2 Assistant Professor, Department of Anaesthesiology, Kishanganj Medical College, Kolkata, India
- 3 PDT Department of Cardiac Anaesthesiology Institute of Postgraduate Medical Education & Research, Kolkata
- 4 Professor Department of Anaesthesiology, N.R.S Medical College, Kolkata, India
- 5 Professor Department of Cardiac Anaesthesiology Institute of Postgraduate Medical Education & Research, Kolkata, India
- 6 Professor & Head, Department of Cardiac Anaesthesiology Institute of Postgraduate Medical Education & Research, Kolkata, India

Corresponding Author: Sandeep Kumar Kar

✉ sndpkar@yahoo.co.in

Assistant Professor, Department of Cardiac Anaesthesiology Institute of Postgraduate Medical Education & Research, Kolkata, India

Patient was reversed by using standard reversal techniques with neostigmine and glycopyrrolate. Postoperative period was uneventful (**Figure 1**).

Discussion

HHT is a rare systemic fibro vascular dysplasia [6] with incidence varying from 1 in 5,000 to 10,000 [7] to 1 to 2 in 1,00,000. Sutton [8] in 1864 first described this syndrome in a man with a vascular malformation and recurrent epistaxis. In 1896 Rendu [9] first noted

the association between hereditary epistaxis and telangiectasia in a 52 years old man. Osler [10] in 1901 and Weber [11] in 1907 further elaborated the association between hemorrhagic lesions in skin and mucous membranes and its familial inheritance. Although the disease is popularly known as Osler-Weber-Rendu syndrome, the name 'hereditary hemorrhagic telangiectasia' suggested by Hanes [12] in 1909, recognizes the characteristics that define the disease.

HHT is manifested by mucocutaneous telangiectases and arteriovenous malformations (AVMs) in different parts of body. Lesions can affect the nasopharynx, central nervous system (CNS), lung, liver, and spleen, as well as the urinary tract, gastrointestinal (GI) tract, conjunctiva, trunk, arms, and fingers [12,13]. Impaired signalling of transforming growth factor- β /bone morphogenesis protein (TGF- β /BMP) [14-17] as well as vascular endothelial growth factor (VEGF) [18,19] has been attributed as the primary cause of HHT (Table 1). The gene mutations found to be responsible are as follows:

The diagnosis of HHT is made clinically on the basis of the Curaçao criteria³, established in June 1999 by the Scientific Advisory Board of the HHT Foundation International, Inc. (Table 2) The 4 clinical diagnostic criteria are as follows:

“definite” if 3 or more criteria are present, “possible or suspected” if 2 criteria are present, and “unlikely” if 0 or 1 criterion is present.

HHT Foundation International - Guidelines Working Group [33] has recommended diagnosis of HHT using the Curaçao Criteria (Table 2) or by identification of a causative mutation.

Histopathology of HHT lesions show many layers of smooth muscle cells without elastic fibers and very frequently arterioles directly communicating with smooth muscle cells. As a result telangiectases are very sensitive to slight trauma and friction. HHT may present in children as bleeding but usual age of presentation in adulthood⁴. Male and females are equally affected [34]. Classic triad of presentation include telangiectases of the skin and mucous membranes, epistaxis, and a positive family history. Epistaxis may be present in upto 95% cases^{4,35} whereas skin lesions account for 75-90% of presentations [35,36]. Skin telangiectasias rarely cause bleeding [4]. Gastrointestinal

telangiectasia may occur in 10-33% patients [37] most commonly in the stomach and upper duodenum [37]. Significant bleeding from gastrointestinal tract may occur in 25% patients older than 60 years and may increase with age [38]. Pulmonary involvement in the form of arteriovenous malformations (AVMs) may be present in 75% HHT1 and 44% HHT2 patients [39]. Patients with pulmonary involvement are at high risk of developing cerebral thrombotic and embolic events including stroke, brain abscess, or transient ischemic attacks due to right-to-left shunting [14,37]. Cerebral AVMs may be present 15-20% HHT1 and 1-2% HHT2 patients [39-43], and may present with seizure, headache or intracranial haemorrhages [4,44]. Hepatic AVMs may be present upto 74% cases [45] but usually asymptomatic [4]. Management strategies for AVMs associated with HHT may differ with location and presentation and depicted in Table 3.

Patients with HHT presenting with continuous bleeding pose a serious problem to the anaesthesiologists. Pre-existing anemia due to recurrent bleeding is common and sudden decompensation may lead to heart failure. Uncontrolled bleeding may occur from skin lesions during patient positioning and transport. Epistaxis may lead to aspiration of blood into trachea causing pulmonary edema. Intravenous access may be difficult. Sudden change in blood pressure may cause bleeding from AVMs anywhere in the body, most serious of which is from cerebral AVM. Gastric distension may occur from ingested blood and may cause reflux and aspiration during induction. Any instrumentation including laryngoscopy and intubation, nasogastric tube insertion, urinary catheterisation should be carried out with utmost caution as bleeding may occur from undetected lesions (Figure 2).

Table 1 Types of HHT and genetic basis.

HHT types	Mutated genes	Gene location
HHT1	ENG [20]	Long arm of chromosome 9 [21-23]
HHT2	ALK1 (Activin receptor-like kinase 1), also called ACVRL1 [24,25]	Long arm of chromosome 12
hereditary benign telangiectasia (HBT), HHT3	RASA1 [26]	chromosome 5q14
HHT4		Chromosome 7p14 [27]
HHT+ Juvenile polyposis coli	SMAD4/MADH4 [28-30]	18q21.2
HHT2+ primary pulmonary hypertension	BMPRII [31,32]	2q33

Table 2 Curaçao criteria.

Criteria	Description
Epistaxis	Spontaneous and recurrent
Telangiectases	Multiple, at characteristic sites: lips, oral cavity, fingers, nose
Visceral lesions	GI Telangiectasia, pulmonary, hepatic, cerebral or spinal AVMs
Family history	A first degree relative with HHT according to these criteria

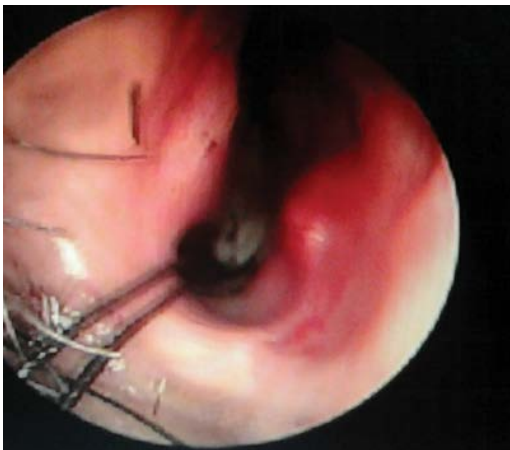

Figure 1 Endoscopic view of the angiofibroma

Table 3 Management strategy of HHT according to site of involvement.

Location	Lesions	Indications of management	Management
Nose	Telangectasia, AVMs	Recurrent epistaxis	Sclerotherapy with sodium tetradecyl sulphate [46], submucosal radiofrequency [47], Bevacizumab [48], Septal mucosal dermoplasty [39,49], Embolisation of external carotid artery branches [50],
Skin	Telangiectasia	Pain [2], cosmesis [4]	Cauterization, hypertonic saline sclerotherapy, dye laser treatment [51]. Pulsed Nd:YAG laser [52],
Gastro intestinal tracts	AVMs, Angio-dysplasia [4]	Chronic anemia, <u>malaena</u>	Diagnosis: Endoscopy, Angiography [4] Management: Bipolar electrocoagulation [4], Laser [4], estrogen-progesteron therapy [53], interferon α [54]
Lungs	AVMs,	exercise intolerance, cyanosis, migraine headaches, polycythemia and clubbing CNS events [14,40] During pregnancy [55]	Feeder vessel >3 mm: Transcatheter embolization [56], Smaller lesion: Follow up [14] Antibiotic prophylaxis to prevent brain abscess
	Diffuse pulmonary AVM	Severe hypoxia	Lung transplantation [4]
CNS	Cerebral and spinal AVMs		transcatheter embolization, resection, stereotactic radiosurgery [57,58]
Liver	AVMs,	Life threatening portosystemic shunts	Liver transplant [59-61] Bevacizumab [62]

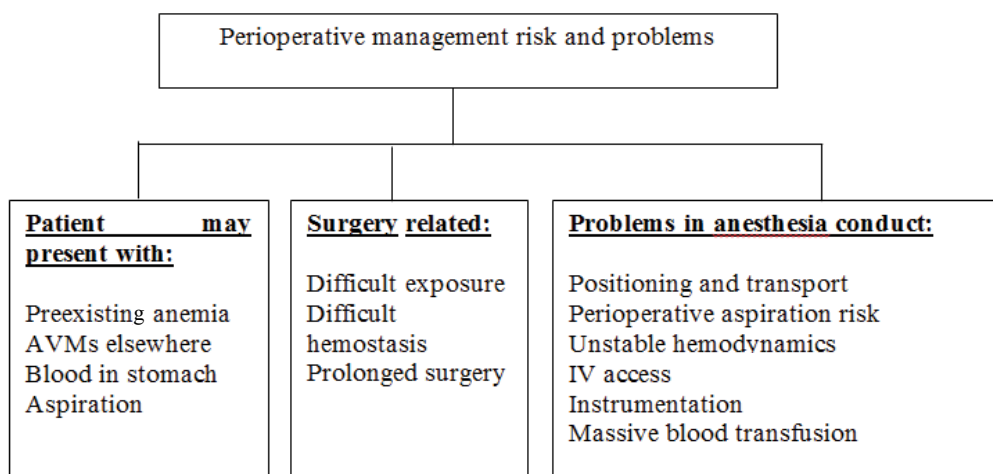


Figure 2 Perioperative management problems in HHT patient.

In Stable patients, posted for elective surgery, preoperative optimization with oral or parenteral iron and if necessary erythropoiesis-stimulating agent [63] should be considered. Preoperatively angiogenesis inhibitor or hormone therapy should be considered in selected patients to reduce perioperative bleeding. Careful history and physical examination may indicate any systemic involvement and standard radiological imaging with angiography may be performed to search for hemangiomas in brain, lung, gastrointestinal tract, nose and paranasal sinuses. In unstable patient presenting with severe bleeding focus should be directed to simultaneous resuscitation and hemostasis. Blood transfusion forms the mainstay of volume resuscitation in severely volume depleted patient. Epistaxis should be controlled with tight nasal packing immediately followed by cauterisation of bleeding vessels and dermoplasty if required. Since bleeding does not result from a defect in coagulation cascade, but from the malformed vascular structures, platelet or plasma

transfusions are of no use and reserved only to supplement the loss. Antifibrinolytics including tranexamic acid [64,65] and aminocaproic acid [66] have been used with success to control epistaxis. In addition to antifibrinolytic effects, tranexamic acid also stimulates the expression of ALK-1 and endoglin, as well as the activity of the ALK-1/endoglin pathway [67]. Intraoperatively controlled hypotension should be used to reduce bleeding.

Conclusion

Patients with Osler-Weber-Rendu disease (OWRD) or Hereditary Hemorrhagic Telangiectasia (HHT) may present with uncontrolled bleeding. Resuscitation alongwith hemostasis forms the cornerstone of treatment. As the bleeding occurs from malformed vessels standard coagulation tests will reveal no abnormality. Management include blood transfusion, antifibrinolytics and surgical hemostasis. Anesthesia strategy should include rapid sequence induction and controlled hypotension.

References

1. Peery, W.H. Clinical spectrum of hereditary hemorrhagic telangiectasia (Osler-Weber-Rendu disease). *Am J Med* 1987; 82: 989-997.
2. Guttmacher, A.E., Marchuk, D.A., White, R.I Jr. Hereditary hemorrhagic telangiectasia. *N Engl J Med* 1995; 333: 918-924.
3. Shovlin, C.L., Guttmacher AE., Buscarini E., Faughnan ME., Hyland RH., et al. Diagnostic criteria for hereditary hemorrhagic telangiectasia (Rendu-Osler-Weber syndrome). *Am J Med Genet* 2000; 91: 66-67.
4. Sharathkumar, A.A., Shapiro, A. Hereditary haemorrhagic telangiectasia. *Haemophilia* 2008; 14: 1269-1280.
5. Porteous, M.E., Burn, J., Proctor, S.J. Hereditary haemorrhagic telangiectasia: a clinical analysis. *J Med Genet* 1992; 29: 527-530.
6. Goulart, A.P., Moro, E.T., Guasti, V.M., Colares, R.F. Anesthetic management of a patient with hereditary hemorrhagic telangiectasia (Rendu-Osler-Weber syndrome). *Case report. Rev Bras Anesthesiol* 2009; 59: 74-78.
7. Kjeldsen, A.D., Vase, P., Green, A. Hereditary haemorrhagic telangiectasia: a population-based study of prevalence and mortality in Danish patients. *J Intern Med* 1999; 245: 31-39.
8. Sutton, H. Epistaxis as an indication of impaired nutrition, and of degeneration of the vascular system. *Med Mirror* 1864; 1: 768-769.
9. Rendu, H. Epistaxis repetees chez un sujet porteur de petits angiomes cutanes et muquez. *Gazette des Hopitaux Civils et Militaires (Paris)* 1896; 135:1322-1323.
10. Osler, W. On a family form of recurring epistaxis, associated with multiple telangiectases of the skin and mucous membranes. *Bull Johns Hopkins Hosp* 1901; 12: 333-337.
11. Weber, F. Multiple hereditary developmental angiomas (telangiectases) of the skin and mucous membranes associated with recurring haemorrhages. *Lancet* 1907; 2: 160-162.
12. Hanes, F. Multiple hereditary telangiectases causing hemorrhage (hereditary hemorrhagic telangiectasia). *Bull Johns Hopkins Hosp* 1909; 20: 63-73.
13. Nanda, S., Bhatt, S.P. Hereditary hemorrhagic telangiectasia: epistaxis and hemoptysis. *CMAJ* 2009; 180: 838.
14. Shovlin, C.L., Letarte, M. Hereditary haemorrhagic telangiectasia and pulmonary arteriovenous malformations: issues in clinical management and review of pathogenic mechanisms. *Thorax* 1999; 54(8):714-729.
15. Ten Dijke, P., Hill, C.S. New insights into TGF-beta-Smad signalling. *Trends Biochem Sci* 2004; 29: 265-273.
16. Wrana, J.L., Attisano, L., Wieser, R., Ventura, F., Massagué, J. Mechanism of activation of the TGF-beta receptor. *Nature* 1994; 370: 341-347.
17. Schmierer, B., Hill, C.S. TGFbeta-SMAD signal transduction: molecular specificity and functional flexibility. *Nat Rev Mol Cell Biol* 2007; 8: 970-982.
18. Cirulli, A., Liso, A., D'Ovidio, F., Mestice, A., Pasculli, G., et al. Vascular endothelial growth factor serum levels are elevated in patients with hereditary hemorrhagic telangiectasia. *Acta Haematol* 2003; 110: 29-32.
19. Xu, B., Wu, Y.Q., Huey, M., Arthur, H.M., Marchuk, D.A., et al. Vascular endothelial growth factor induces abnormal microvasculature in the endoglin heterozygous mouse brain. *J Cereb Blood Flow Metab.* 2004; 24(2): 237-244.
20. McAllister, K.A., Grogg, K.M., Johnson, D.W., Gallione, C.J., Baldwin, M.A., et al. Endoglin, a TGF-beta binding protein of endothelial cells, is the gene for hereditary haemorrhagic telangiectasia type 1. *Nat Genet* 1994; 8: 345-35.
21. Abdalla, S.A., Letarte, M. Hereditary haemorrhagic telangiectasia: current views on genetics and mechanisms of disease. *J Med Genet* 2006; 43: 97-110.
22. McDonald, M.T., Papenberg, K.A., Ghosh, S., Glatfelter, A.A., Biesecker, B.B., et al. A disease locus for hereditary haemorrhagic telangiectasia maps to chromosome 9q33-34. *Nat Genet* 1994; 6: 197-204.
23. Shovlin, C.L., Hughes, J.M., Tuddenham, E.G., Temperley, I., Perembelon, Y.F., et al. A gene for hereditary haemorrhagic telangiectasia maps to chromosome 9q3. *Nat Genet* 1994; 6: 205-209.
24. Johnson, D.W., Berg, J.N., Baldwin, M.A., Gallione, C.J., Marondel, I., et al. Mutations in the activin receptor-like kinase 1 gene in hereditary haemorrhagic telangiectasia type 2. *Nat Genet* 1996; 13: 189-195.
25. Johnson, D.W., Berg, J.N., Gallione, C.J., McAllister, K.A., Warner, J.P., et al. A second locus for hereditary hemorrhagic telangiectasia maps to chromosome 12. *Genome Res* 1995; 5: 21-28.
26. Cole, S.G., Begbie, M.E., Wallace, G.M., Shovlin, C.L. A new locus for hereditary haemorrhagic telangiectasia (HHT3) maps to chromosome 5. *J Med Genet* 2005; 42: 577-582.
27. Bayrak-Toydemir, P., McDonald, J., Akarsu, N., Toydemir, R.M., Calderon, F., et al. A fourth locus for hereditary hemorrhagic telangiectasia maps to chromosome 7. *Am J Med Genet A* 2006; 140: 2155-2162.
28. Gallione, C.J., Repetto, G.M., Legius, E., Rustgi, A.K., Schelley, S.L., et al. A combined syndrome of juvenile polyposis and hereditary haemorrhagic telangiectasia associated with mutations in MADH4 (SMAD4). *Lancet.* 2004; 364: 852-859.
29. Gallione, C., Aylsworth, A.S., Beis, J., Berk, T., Bernhardt, B., et al. Overlapping spectra of SMAD4 mutations in juvenile polyposis (JP) and JP-HHT syndrome. *Am J Med Genet A* 2010; 152A: 333-339.
30. Iyer, N.K., Burke, C.A., Leach, B.H., Parambil, J.G. SMAD4 mutation and the combined syndrome of juvenile polyposis syndrome and hereditary haemorrhagic telangiectasia.

- Thorax 2010; 65: 745-746.
31. Harrison, R.E., Flanagan, J.A., Sankelo, M., Abdalla, S.A., Rowell, J., Machado, R.D., et al. Molecular and functional analysis identifies ALK-1 as the predominant cause of pulmonary hypertension related to hereditary haemorrhagic telangiectasia. *J Med Genet.* 2003; 40(12): 865-867.
 32. Trembath, R.C., Thomson, J.R., Machado, R.D., Morgan, N.V., Atkinson, C., et al. Clinical and molecular genetic features of pulmonary hypertension in patients with hereditary hemorrhagic telangiectasia. *N Engl J Med* 2001; 345: 325-334.
 33. Faughnan, M.E., Palda, V.A., Garcia-Tsao, G., Geisthoff, U.W., McDonald, J et al. HHT Foundation International - Guidelines Working Group. International guidelines for the diagnosis and management of hereditary haemorrhagic telangiectasia. *J Med Genet.* 2011; 48(2):73-87.
 34. Schoen, F.J., Cotran, R.S., Vinay, K., Collins, T. Robbins Pathologic Basis of Disease. 1994.
 35. Plauchu, H., De Chadarévian, J.P., Bideau, A., Robert, J.M. Age-related clinical profile of hereditary hemorrhagic telangiectasia in an epidemiologically recruited population. *Am J Med Genet* 1989; 32: 291-297.
 36. Berg, J., Porteous, M., Reinhardt, D., Gallione, C., Holloway, S., et al. Hereditary haemorrhagic telangiectasia: a questionnaire based study to delineate the different phenotypes caused by endoglin and ALK1 mutations. *J Med Genet* 2003; 40: 585-590.
 37. Ingrosso, M., Sabbà, C., Pisani, A., Principi, M., Gallitelli, M., et al. Evidence of small-bowel involvement in hereditary hemorrhagic telangiectasia: a capsule-endoscopic study. *Endoscopy* 2004; 36: 1074-1079.
 38. Kjeldsen, AD., Kjeldsen, J. Gastrointestinal bleeding in patients with hereditary hemorrhagic telangiectasia. *Am J Gastroenterol* 2000; 95: 415-418.
 39. Sabbà, C., Pasculli, G., Lenato, G.M., Suppressa, P., Lastella, P., et al. Hereditary hemorrhagic telangiectasia: clinical features in ENG and ALK1 mutation carriers. *J Thromb Haemost* 2007; 5: 1149-1157.
 40. Vase, P., Holm, M., Arendrup, H. Pulmonary arteriovenous fistulas in hereditary hemorrhagic telangiectasia. *Acta Med Scand* 1985; 218: 105-109.
 41. Haitjema, T., Disch, F., Overtoom, T.T., Westermann, C.J., Lammers, J.W. Screening family members of patients with hereditary hemorrhagic telangiectasia. *Am J Med* 1995; 99: 519-524.
 42. Fulbright, R.K., Chaloupka, J.C., Putman, C.M., Sze, G.K., Merriam, M.M., et al. White RI Jr. MR of hereditary hemorrhagic telangiectasia: prevalence and spectrum of cerebrovascular malformations. *AJNR Am J Neuroradiol.* 1998; 19(3): 477-484.
 43. Bossler, A.D., Richards, J., George, C., Godmilow, L., Ganguly, A. Novel mutations in ENG and ACVRL1 identified in a series of 200 individuals undergoing clinical genetic testing for hereditary hemorrhagic telangiectasia (HHT): correlation of genotype with phenotype. *Hum Mutat* 2006; 27: 667-675.
 44. Matsubara, S., Mandzia, J.L., Ter Brugge, K., Willinsky, R.A., Faughnan, M.E. Angiographic and clinical characteristics of patients with cerebral arteriovenous malformations associated with hereditary hemorrhagic telangiectasia. *AJNR Am J Neuroradiol* 2000; 21: 1016-1020.
 45. Memeo, M., Stabile Ianora, A.A., Scardapane, A., Buonamico, P., Sabbà C., et al. Hepatic involvement in hereditary hemorrhagic telangiectasia: CT findings. *Abdom Imaging* 2004; 29: 211-220.
 46. Boyer, H., Fernandes, P., Duran, O., Hunter, D., Goding, G. Office-based sclerotherapy for recurrent epistaxis due to hereditary hemorrhagic telangiectasia: a pilot study. *Int Forum Allergy Rhinol.* 2011; 1(4):319-323.
 47. Mortuaire, G., Boute, O., Hatron, P.Y., Chevalier, D. Pilot study of submucosal radiofrequency for epistaxis in hereditary hemorrhagic telangiectasia. *Rhinology* 2013; 51: 355-360.
 48. Dheyauldeen, S., Ostertun Geirdal, A., Osnes, T., Vartdal, L.S., Dollner, R. Bevacizumab in hereditary hemorrhagic telangiectasia-associated epistaxis: effectiveness of an injection protocol based on the vascular anatomy of the nose. *Laryngoscope.* 2012; 122(6): 1210-1214. doi: 10.1002/lary.23303. Epub 2012 May 7
 49. Pau, H., Carney, A.S., Murty, G.E. Hereditary haemorrhagic telangiectasia (Osler-Weber-Rendu syndrome): otorhinolaryngological manifestations. *Clin Otolaryngol Allied Sci* 2001; 26: 93-98.
 50. Strother, C.M., Newton, T.H. Percutaneous embolization to control epistaxis in Rendu-Osler-Weber disease. *Arch Otolaryngol* 1976; 102: 58-60.
 51. Harries PG., Brockbank MJ., Shakespeare PG., Carruth JA. Treatment of hereditary haemorrhagic telangiectasia by the pulsed dye laser. *J Laryngol Otol* 1997; 111: 1038-104.
 52. Werner, A., Baumler, W., Zietz, S., Kühnel, T., Hohenleutner, U., et al. Hereditary haemorrhagic telangiectasia treated by pulsed neodymium:yttrium-aluminium-garnet (Nd:YAG) laser (1,064 nm). *Lasers Med Sci.* 2008; 23(4): 385-389.
 53. Van Cutsem, E., Rutgeerts, P., Vantrappen, G. Treatment of bleeding gastrointestinal vascular malformations with oestrogen-progesterone. *Lancet* 1990; 335: 953-955.
 54. Massoud, O.I., Youssef, W.I., Mullen, K.D. Resolution of hereditary hemorrhagic telangiectasia and anemia with prolonged alpha-interferon therapy for chronic hepatitis C. *J Clin Gastroenterol* 2004; 38: 377-379.
 55. Shovlin, C.L., Winstock, A.R., Peters AM., Jackson JE., Hughes, J.M. Medical complications of pregnancy in hereditary haemorrhagic telangiectasia. *QJM* 1995; 88: 879-887.
 56. White, R.I. Jr., Pollak, J.S., Wirth, J.A. Pulmonary arteriovenous malformations: diagnosis and transcatheter embolotherapy. *J Vasc Interv Radiol* 1996; 7: 787-804.

57. Hadjipanayis, C.G., Levy, E.I., Niranjan, A., Firlik, A.D., Kondziolka, D., et al. Stereotactic radiosurgery for motor cortex region arteriovenous malformations. *Neurosurgery* 2001; 48: 70-76.
58. Levy, E.I., Niranjan, A., Thompson, T.P., Scarrow, A.M., Kondziolka, D., et al. Radiosurgery for childhood intracranial arteriovenous malformations. *Neurosurgery* 2000; 47: 834-84.
59. Dupuis-Girod, S., Chesnais, A.L., Ginon, I., Dumortier, J., Saurin, J.C., et al. Long-term outcome of patients with hereditary hemorrhagic telangiectasia and severe hepatic involvement after orthotopic liver transplantation: a single-center study. *Liver Transpl.* 2010; 16(3): 340-347.
60. Hillert, C., Broering, D.C., Gundlach, M., Knoefel, W.T., Izbicki, J.R., et al. Hepatic involvement in hereditary hemorrhagic telangiectasia: an unusual indication for liver transplantation. *Liver Transpl* 2001; 7: 266-268
61. Lerut, J., Orlando, G., Adam, R., Sabbà, C., Pfitzmann, R., et al. Liver transplantation for hereditary hemorrhagic telangiectasia: Report of the European liver transplant registry. *Ann Surg* 2006; 244: 854-862.
62. Mitchell, A., Adams, L.A., Macquillan, G., Tibballs, J., Vanden Driesen, R., et al. Bevacizumab reverses need for liver transplantation in hereditary hemorrhagic telangiectasia. *Liver Transpl* 2008; 14: 210-213.
63. Cherif, H., Karlsson, T. Combination treatment with an erythropoiesis-stimulating agent and intravenous iron alleviates anaemia in patients with hereditary haemorrhagic telangiectasia. *Ups J Med Sci.* 2014; 119(4): 350-353.
64. Gaillard, S., Dupuis-Girod, S., Boutitie, F., Rivière, S., Morinière, S., et al. Tranexamic acid for epistaxis in hereditary hemorrhagic telangiectasia patients: a European cross-over controlled trial in a rare disease. *J Thromb Haemost.* 2014; 12(9): 1494-1502.
65. Morales-Angulo, C., Pérez del Molino, A., Zarrabeitia, R., Fernández, A., Sanz-Rodríguez, F., et al. Treatment of epistaxes in hereditary haemorrhagic telangiectasia (Rendu-Osler-Weber disease) with tranexamic acid. *Esp* 2007; 58(4): 129-132.
66. Korzenik, J.R., Topazian, M.D., White, R. Treatment of bleeding in hereditary hemorrhagic telangiectasia with aminocaproic acid. *N Engl J Med* 1994; 331: 1236.
67. Fernandez, L.A., Garrido-Martin, E.M., Sanz-Rodríguez, F., Ramirez, J.R., Morales-Angulo, C., et al. Therapeutic action of tranexamic acid in hereditary haemorrhagic telangiectasia (HHT): regulation of ALK-1/endothelin pathway in endothelial cells. *Thromb Haemost.* 2007; 97(2): 254-262.