

DOI: 10.21767/2254-6081.1000146

Rapid Flare of Brain Metastases in ALK-Positive Non-Small Cell Lung Cancer after Stopping Crizotinib

Juengsamarn J, Sirachainan E and Reungwetwattana T*

Division of Medical Oncology, Department of Internal Medicine, Ramathibodi Hospital, Mahidol University, Bangkok, Thailand

*Corresponding author: Reungwetwattana T, Division of Medical Oncology, Department of Internal Medicine, Ramathibodi Hospital, Mahidol University, Bangkok, Thailand, Tel: 66 (0) 2201-1671; Fax: 66 (0) 2643-5648; E-mail: thanyanan.reu@mahidol.ac.th

Received: March 27, 2017; Accepted: July 13, 2017; Published: July 17, 2017

Citation: Thanyanan R (2017) Rapid Flare of Brain Metastases in ALK-Positive Non-Small Cell Lung Cancer after Stopping Crizotinib. Arch Can Res Vol.5 No.3: 146.

Abstract

The prevalence of Anaplastic lymphoma kinase (ALK) rearrangement in NSCLC is about 7-10%. Currently, there are several ALK inhibitors available in treating this group of patients. Brain metastases occur in approximately 30% of patients with ALK-positive non-small-cell lung cancer (NSCLC), and in patients treated with ALK inhibitor, CNS progression occurs in up to 70% of patients. Patients with brain metastases from ALK-positive NSCLC have a distinct natural history compared with patients with wild-type NSCLC. This article describes the rapid flare of brain metastases in ALK-positive non-small cell lung cancer after stopping Crizotinib.

progression on initial TKI and presence of pleural or CNS disease. Not only EGFR mutation has targeted drug in non-small cell lung cancer (NSCLC) but there is about 5% of anaplastic lymphoma kinase (ALK) gene rearrangement in NSCLC [2]. However, only few cases of flare phenomenon after discontinuation of ALK inhibitor was reported [3]. We demonstrate another rapid flare of CNS metastasis event after stopping Crizotinib in ALK-positive NSCLC.

Case Report

A 41-year-old Thai female presented with chronic cough. Right pleural effusion and multiple pulmonary nodules were detected in CXR and CT chest. Pleural biopsy was performed and showed metastatic adenocarcinoma of the lung without EGFR mutation. She was initially treated with 6 cycles of Pemetrexed/Cisplatin until December 2013 with partial response (PR). In May 2014, she developed progressive disease (PD) in pleura and bone. Docetaxel was started as the 2nd line treatment. Unfortunately, after 3 cycles of Docetaxel, she developed PD in lung and brain metastases. She underwent whole brain radiation (30 Gy). At progression, ALK gene rearrangement was detected by both IHC and FISH techniques.

Keywords Brain metastases; Lung cancer; Crizotinib

Introduction

Twenty three percent of disease flare after discontinuation of EGFR-TKI has been reported with the median time to disease flare after EGFR TKI discontinuation was 8 days [1]. Factor associated with disease flare were shorter time to

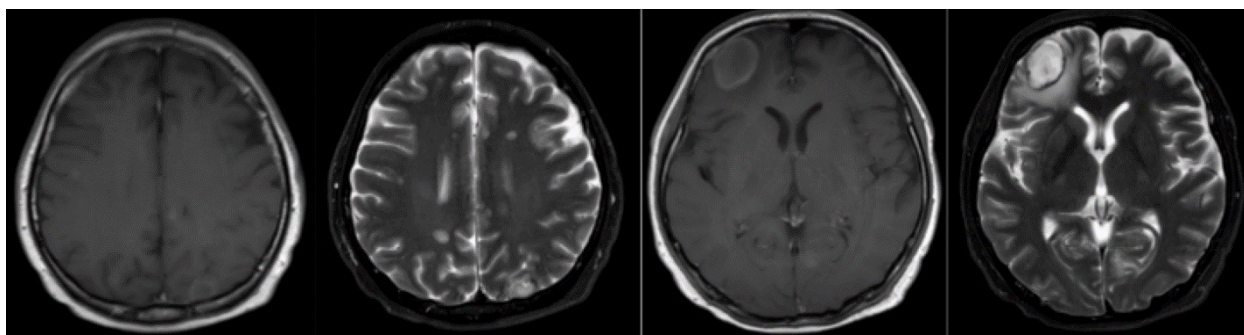


Figure 1 MRI brain on the day of stopping Crizotinib.

Crizotinib was started in September 2014 with dramatic response after 2 weeks of treatment. Unfortunately, she developed systemic progression after 6 months of taking

Crizotinib. Further treatment options were discussed with patient and family with the choice of chemotherapy or clinical trial of second generation ALK inhibitor. Patient chose to enroll

in clinical trial with the requirement of washout period at least 5 half-life of Crizotinib (9 days). MRI brain on the day of stopping Crizotinib showed stable disease (**Figure 1**). Two weeks after stopping Crizotinib, she had worsening of headache and left-sided hemiparesis. CT brain showed obviously increasing in size and number of brain metastases (**Figure 2**). Unfortunately, she passed away from *Klebsiella pneumoniae* septicemia. At that time, her family refused intubation and resuscitation.

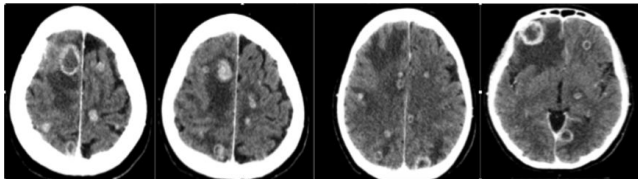


Figure 2 CT brain at 2 weeks after stopping Crizotinib.

Discussion and Conclusion

Flare phenomenon after discontinuation of EGFR TKI is well known. Only few cases were reported of rapid flare after stopping ALK inhibitor. Our case demonstrated another rapid flare of CNS metastases after stopping Crizotinib in ALK-positive NSCLC. Flare phenomenon should be carefully

monitored during washout period in the patients who have oncogenic-driven mutation and patients who are taking tyrosine kinase inhibitors, especially, patients who have a lot of tumor burden at the time of progression. Acquired resistance mutations are probably one of the causes of rapid progression in Crizotinib-resistant patient. However, our patient's disease at the time of progression was not tested for resistant mutation.

References

1. Chaft JE, Oxnard GR, Sima CS, Kris MG, Miller VA, et al. (2011) Disease flare after tyrosine kinase inhibitor discontinuation in patients with EGFR-mutant lung cancer and acquired resistance to erlotinib or gefitinib: implications for clinical trial design. An official Journal of the American Association for Cancer Research. Clin Can Res 17: 6298-6303.
2. Pop O, Pirvu A, Toffart AC, Moro-Sibilot D (2012) Disease flare after treatment discontinuation in a patient with EML4-ALK lung cancer and acquired resistance to crizotinib. Official publication of the International Association for the Study of Lung Cancer. J Thorac Oncol 7: 1-2.
3. Doebele RC, Pilling AB, Aisner DL, Kutateladze TG, Le AT, et al. (2012) Mechanisms of resistance to crizotinib in patients with ALK gene rearranged non-small cell lung cancer. An official Journal of the American Association for Cancer Research Clin Can Res 18: 1472-1482.