

Toxoplasmosis Septicaemia: Don't put the Blame on the Cat

Angel Robles-Marhuenda*

Internal Medicine Division La Paz University Hospital, Madrid, Spain

*Corresponding Author: Dr. Angel Robles-Marhuenda, Internal Medicine Division La Paz University Hospital, Madrid, Spain, Tel: +34626547303; E-mail: aroblesmarhuenda@gmail.com

Rec Date: Dec 18, 2015; Acc Date: Feb 08, 2016; Pub Date: Feb 18, 2016

Copyright: © 2016, Marhuenda AR. This is an open-access article distributed under the terms of the Creative Commons Attribution License, which permits unrestricted use, distribution, and reproduction in any medium, provided the original author and source are credited.

Case Report

A 31-year-old Ecuadorian woman, who arrived in Spain 18 months ago and owned a cat, was admitted in the Emergency Department because of persistent headache, left homonymous hemianopsia and right-leg weakness. Twenty days before, the early symptoms were epigastralgia, fever, non-productive cough and dyspnea. Physical examination: jaundice; blood pressure 105/65 mmHg, heart rate 120 bpm and breathing rate 22 pm. No mucocutaneous candidiasis was present. Abdominal pain in epigastrium and right hypochondrium with positive Murphy's sign was reported. Glasgow Coma Scale was 15/15 although she felt drowsy, with left inferior homonymous quadrantanopsia, muscular balance 4/5 in right inferior limb and increased reflexes, with negative meningeal signs. The chest X-ray did not show infiltration, although calcificated millimetric basal left nodules were noticed. The electrocardiogram was normal. An abdominal ultrasonography showed multiple hypoechoic periaortical, mesenteric and perileal nodules as large adenopathies with

diffuse enlarged circumferential jejunum intestinal wall. In contrast brain CT (picture A) two enhanced heterogeneous lesions were observed in left basal ganglia and right parieto-occipital area. Hemoglobin 12.1 gr/dl, hematocrite 37%, VCM 82.1 fL, white cells 7000/ μ L (69.8% N, 21.3% L, 8.5% M), platelets 405.000/ μ L, prothrombin activity 104%, creatinine 0.7 mg/dl, urea 10 mg/dl, glucose 108 mg/dl, sodium 136 mmol/L, kalemia 3.3 mmol/L, AST-GOT 44 UI/L, ALT-GPT 56 UI/L, GGT 36 UI/L, LDH 216 UI/L, amylase 78 UI/L, total bilirrubine 0.3 mg/dl, C Reactive Protein 22.4 mg/L, pH 7.42, pO₂ 69 mmHg, pCO₂ 32.1 mmHg, bases gap -3.8 mmol/L, HCO₃ 20 mmol/L. LCR test: macroscopically cloudy; exit pressure 40 cm H₂O; glucose LCR 45 mg/dL; proteins 78; white cells 8 / mm³; in Gram, bacterias or cells were not observed. The cryptococcus antigen was negative. Treatment against mycobacteria was performed with four drugs and endovenous steroids, as disseminated tuberculosis was suspected. Lymphomatose or other infectious processes were not ruled out.

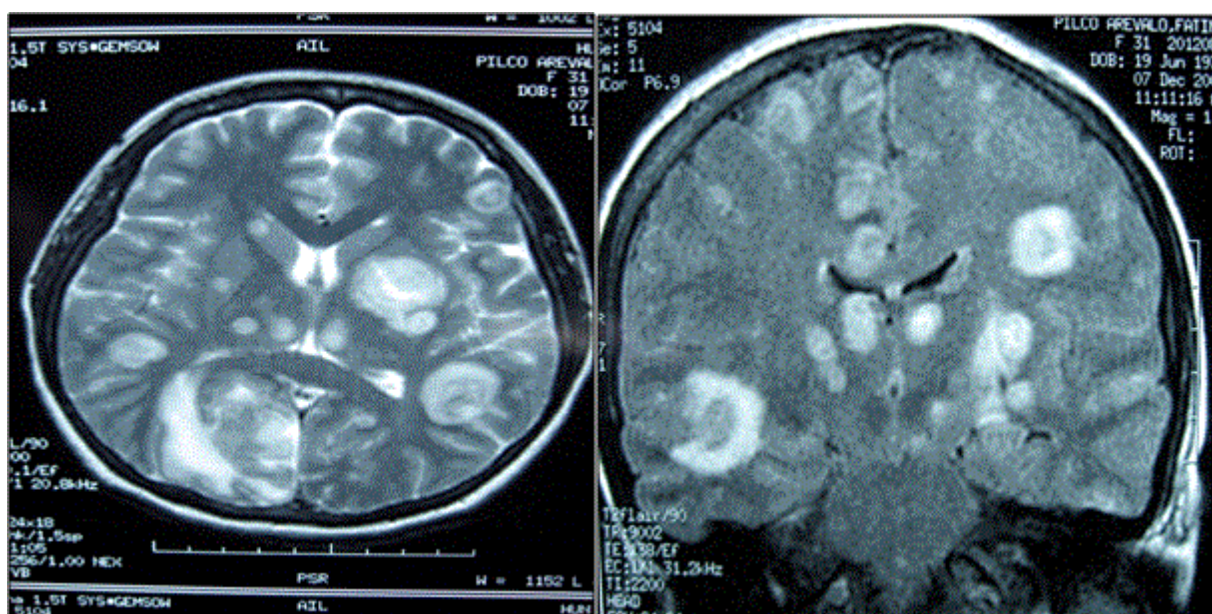


Figure1: A and B CT and MRI brain images

Evolution

The patient worsened with fever and neurological impairment, with right leg paralysis, positive meningeal signs and abdominal pain as a reflection of intestinal obstruction. On the second day after admission, consciousness lowered, she only answered to painful stimuli and showed right mydriasis and low reactive left pupil. In the MRI (picture B) the brain had huge multifocal damage with important vasogenic edema. She was admitted in the ICU because of multiple organ failure and respiratory distress syndrome. Despite endotracheal intubation inotropic drugs and vasogenic brain edema therapy, the patient died.

Diagnosis

HIV positive serology was received after death. Autopsy showed disseminated toxoplasmosis with: necrotizing encephalitis, necrotizing and granulomatose peritonitis, mesenteric necrotizing lymphadenitis, necrotizing oophoritis, myocarditis and granulomatosa pneumonitis.

Discussion

Devastating and disseminated toxoplasmosis is an uncommon disease except in congenital toxoplasmosis or severe cellular immunity disorders [1,2]. Although toxoplasmosis often indicates HIV infection debut, cerebral or ophthalmic manifestations are the most usual. Myocarditis, pneumonitis and polymyositis are less frequent and the devastating form is exceptional [2-5]. So, in a French study, extracranial toxoplasmosis prevalence in non-HIV patients was 1.5-2%. In 199 patients, 26% had pulmonary disease, 11.5% disseminated toxoplasmosis (defined as at least two extracranial organs affected), 3% bone marrow disease, 3% heart disease but 41% showed cerebral disease and 50%

chorioretinitis [6]. Disseminated or extracranial toxoplasmosis prognosis and therapeutic response is worse than in isolated encephalitis [2,6]. Besides, they can come up as devastating or septicemic toxoplasmosis, leading to death in a few hours or days in spite of a proper treatment because of multiorgan failure [6,7].

This is the first case of disseminated toxoplasmosis and devastating or 'sepsis-like' with pathological proof, being the HIV infection debut also bearing in mind the difficulty in diagnosing toxoplasmosis as a lethal disease, disseminated toxoplasmosis must be included in the differential diagnosis of infectious diseases with cerebral damage and multiorgan spreading.

References

1. Montoya JG, Jordan R, Lingamneni S, Berry GB, Remington JS (1997) Toxoplasmic myocarditis and polymyositis in patients with acute acquired toxoplasmosis diagnosed during life. *Clin Infect Dis* 24: 676-683.
2. Montoya JG, Liesenfeld O (2004) Toxoplasmosis. *Lancet* 363: 1965-1976.
3. Mariuz P, Bosler EM, Luft BJ (1997) *Toxoplasma pneumoniae*. *Semin Respir Infect* 12: 40-43.
4. Montoya JG, Remington JS (1996) Toxoplasmic chorioretinitis in the setting of acute acquired toxoplasmosis. *Clin Infect Dis* 23: 277-282.
5. Eza DE, Lucas SB (2006) Fulminant toxoplasmosis causing fatal pneumonitis and myocarditis. *HIV Med* 7: 415-420.
6. Rabaud C, May T, Amiel C, Katlama C, Leport C, et al. (1994) Extracerebral toxoplasmosis in patients infected with HIV: A French National Survey. *Medicine (Baltimore)* 73: 306-314.
7. Lucet JC, Bailly MP, Bedos JP, Wolff M, Gachot B, et al. (1993) Septic shock due to toxoplasmosis in patients infected with the human immunodeficiency virus. *Chest* 104: 1054-1058.