

August 06-07, 2018
Prague, Czech Republic

J Univer Surg 2018, Volume: 6
DOI: 10.21767/2254-6758-C1-003

HOW DOES A CURVED-TIP ENDOSCOPIC STAPLE FACILITATE OUR VIDEOTHORACOSCOPIC SURGERY PRACTICE?

Cagatay Tezel, Serdar Evman, İlker Kolbaş, Levent Alpay and Volkan Baysungur

Süreyyapasa Chest Diseases and Thoracic Surgery Hospital, Istanbul, Turkey

Videothoroscopic lung resection ratio is increasing. Both the incision length and thoracar numbers are decreasing. The evolvement of thoracoscopic instruments has led the minimally invasive operations into another dimension. Enhanced visibility and maneuverability can easily be obtained. Hereby we wish to share our findings and opinion about curved-tip over conventional straight endostaplers for vascular use. Nearly, 350 videothoroscopic lung resections are performed in our thoracic surgical unit, annually. Last year we started using Endo GIA™ 45 mm Curved Tip Articulating Vascular staplers (Covidien-Medtronic Inc., Dublin, Ireland) for vessel stapling through bi-portals videothoracoscopic incisions. 10 patients underwent video assisted thoracic surgery (VATS) lung resections. Those were of five right upper lobectomy, two middle lobectomies, two left upper and one left lower lobectomy. In order to compare with our previous operations, especially during left upper lobectomy, the curved-tip facilitated the vessel dissection by passing the vein in correct direction and avoids injuring the first branch of pulmonary artery right behind. When performing videothoracoscopic lobectomies via subxiphoid approach, middle vein dissection could easily be done, in contrast with the maneuver difficulty in conventional endostaplers (Fig 1). For inferior pulmonary veins, the curved tip helps to elevate the vein, therefore precludes us to come cross with the vertebral body. During arterial dissection, the tip gently manipulates the tissue, allowing for blunt dissection and mobilization. We generally were using a foley catheter as a guide before passing the stapler under the vessel, to facilitate stapler positioning, as seen in Fig 2. However by the guidance of the solid tip, there is no need of additional instruments

mohamed_ali@med.svu.edu.eg

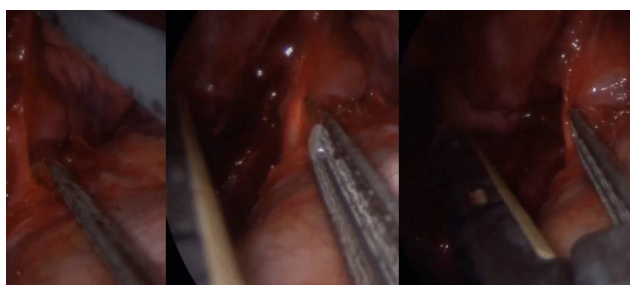


Figure 1: Curved tip staple for easy dissection and staple

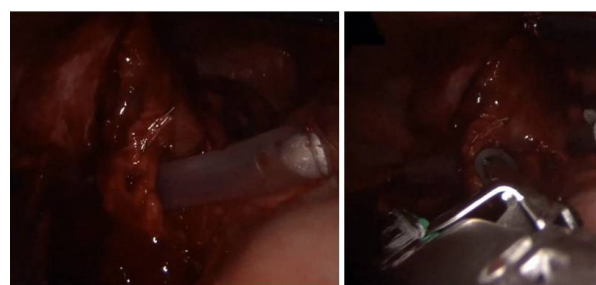

Figure 2: Fig 2. Conventional Foley cathater passing for staple