

DOI: 10.36648/2254-6758.8.3.122

# A Single Stage Procedure without Fecal Diversion for Extraperitoneal Rectovesical Injury: A Case Report

**Sisodiya R\* and Joshi N**

NMC Specialist Hospital, Al Ain, Abu Dhabi, UAE

\*Corresponding author: Rajesh Sisodiya, Specialist General Surgeon, NMC Specialist Hospital, Al Ain, Abu Dhabi, UAE, Tel: +971564837240; E-mail: rajeshnidhi@gmail.com

Received date: April 24, 2020; Accepted date: July 7, 2020; Published date: July 14, 2020

Citation: Sisodiya R, Joshi N (2020) A Single Stage Procedure without Fecal Diversion for Extraperitoneal Rectovesical Injury: A Case Report. J Univer Surg. Vol.8 No.3: 3

## Abstract

Penetrating rectal injuries themselves are associated with a 39–47% incidence of GU injury with the bladder being most frequently injured. Debridement of necrotic rectum with primary repair, proximal diversion, and the placement of an omentum pedicle flap between the rectum and GU injury have been recommended especially in cases of combined posterior bladder and anterior rectal injuries. High rates (24%) of rectovesical and rectourethral fistula are associated with combined GU and rectal injuries. We present a case with mid rectal injury with posterior and anterior urinary bladder wall injury with injury to right ureter managed by single stage resection of injured rectum with primary rectorectal anastomoses, repair of urinary bladder wall injury with right ureteric reimplantation without proximal diversion without any postoperative complications, the first case report of such management of rectovesical injury in the world.

## Keywords

Rectal injuries; Necrosis; Fistula; Injury

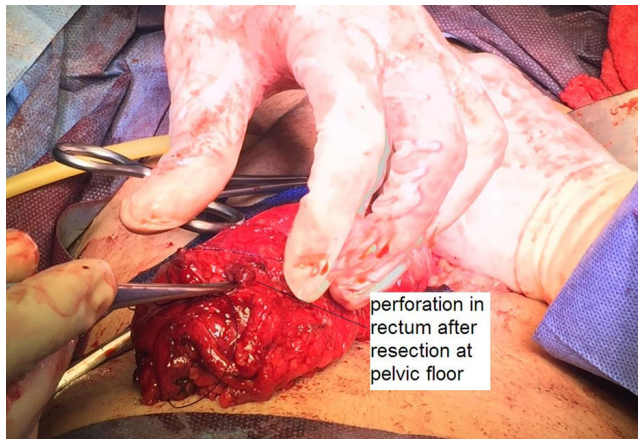
## Introduction

Penetrating colorectal or genitourinary (GU) injuries present a major source of morbidity as they occur in 6% to 18% of all abdominal/pelvic penetrating injuries, with 0% to 18% of these injuries resulting in fistula formation [1-3]. For patients with an inflammatory cause of the fistula, one-stage operative treatment is associated with low morbidity and decreased length of stay compared with operative treatment in more than one stage. In the presence of severe inflammation or inadequate bowel preparation, two-stage operative treatment is safe and effective. Operations in three stages for colovesical fistula are not indicated [4]. We did primary closure of urinary bladder injury with resection of injured rectum with primary rectorectal anastomoses with reimplantation of right ureter in such a case without any proximal diversion with patient discharged without any complications 1 week after surgery.

## Case Presentation

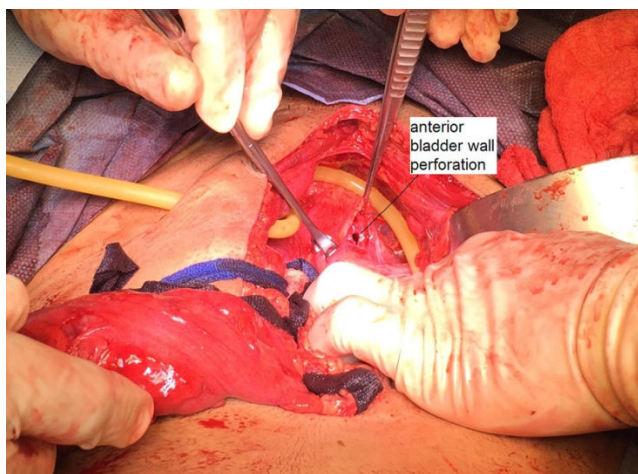
A 32-year-old male patient presented to Emergency Room with history of fall on Iron fence 2 hours back with penetration of pointed end of Iron rod of fence into his anus. He complains of pain lower abdomen with blood in urine since 2 hours. Clinical examination of Abdomen revealed soft, non-distended abdomen with suprapubic tenderness. Per Rectal Examination revealed lacerated wound perianal region 1 cm × 1.5 cm, anal canal examination was avoided as patient was having anal pain. As patient was hemodynamically stable along with routine blood investigations, US abdomen and pelvis and later CT scan abdomen and pelvis was done which showed clots in urinary bladder around 200-300 ml with large defect 1.5 cm in posterior wall of urinary bladder with hematoma around 50-60 ml between urinary bladder and rectum with minimal fluid in peritoneal cavity. With preoperative diagnosis of Rectovesical injury 2 PRBC were arranged and patient was taken to operative room for exploratory laparotomy. Under General anaesthesia Cystoscopy was done which revealed normal urethra, blood in urinary bladder right ureteric opening could not be seen and opening site was congested. Per rectal examination was done which revealed normal anal canal with a perforation in anterior wall of rectum around 6-7 cm from anus approximately 2 to 2.5 cm in dimension. Patient underwent exploratory laparotomy. Intraoperative findings revealed minimal fluid and blood in pelvis. As there was no contamination and patient was hemodynamically stable rectum was mobilized to find perforation in mid and lower rectum junction (**Figure 1**).

As distal rectum and anal canal were normal plan to resect injured rectum, primary rectorectal anastomoses with repair of urinary bladder perforation with re-implantation of right ureter was taken. Posterior urinary bladder wall perforation was closed in two layers.



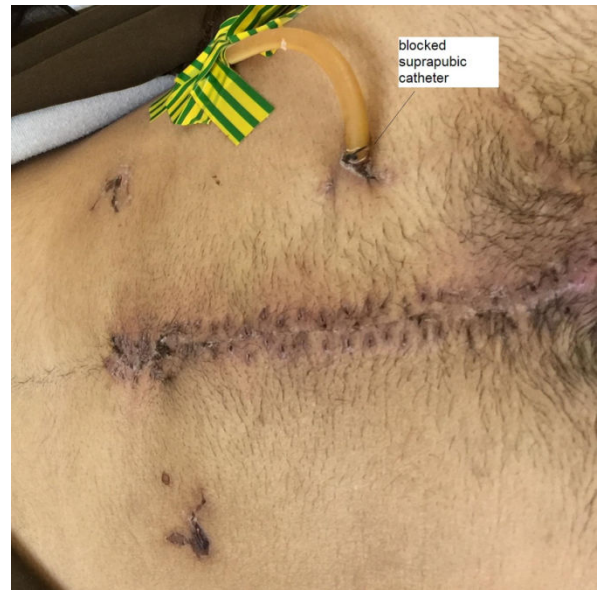**Figure 1:** Perforation in rectum after resection at pelvic floor.

Right ureter was reimplanted as cystoscopy had revealed right ureteric injury. After repair of posterior urinary bladder wall, irrigation of urinary bladder via Foley catheter, revealed perforation in anterior urinary bladder wall (**Figure 2**) which was closed in two layers after placing Foley's as suprapubic drain.



**Figure 2:** Anterior bladder wall perforation.

Resection of injured rectum was done at pelvic floor with primary rectorectal stapled anastomoses with circular stapler no 29. Intraoperative leak test was done which showed no leak from anastomoses and hence diversion stoma was avoided. Vascularized omentum was placed between rectum and bladder. Abdominal drains placed. Patient was started oral liquids on Postoperative day 1. Patient recovered well without complications and was discharge on Postoperative day 7. He was followed up to 1 year after surgery and was asymptomatic (**Figure 3**).



**Figure 3:** Blocked suprapubic catheter.

## Discussion

EVF (Enterovesical Fistula) most frequently occur in a setting of inflammatory bowel disease. Diverticulitis is the commonest aetiology accounting for approximately 65–79% of cases, which are almost exclusively colovesical [4-7].

All EVF can be divided into the following 4 primary categories:

- Colovesical
- Rectovesical (including rectourethral)
- Ileovesical and
- Appendicovesical fistulae

While colovesical fistula is the most common form of vesicointestinal fistula and is most frequently located between the sigmoid colon and the dome of the bladder, rectovesical fistulae are observed in the postoperative setting (i.e., after prostatectomy) [8,9].

The hallmark of enterovesical fistulae may be described as Gouverneur syndrome, namely, suprapubic pain, frequency, dysuria, and tenesmus [10]. Lower urinary tract symptoms, which include pneumaturia (the most common symptom present in 50–70% of cases), fecaluria (reported in up to 51%), frequency, urgency, suprapubic pain, recurrent urinary tract infections (UTIs), and haematuria [7,11-13].

Cystoscopy, with the highest yield in identifying a potential lesion, is an essential component of the entire investigation process; its findings are usually nonspecific and include erythema, oedema, and congestion.

The diagnostic accuracy of CT (computed tomography) for detecting colovesical fistulae is up to 90–100% [7,14,15]. The findings on CT, which are suggestive of enterovesical fistula include:

- Air in the bladder (in the absence of previous lower urinary tract instrumentation).
- Oral contrast medium in the bladder on nonintravenous contrast enhanced scans.
- Presence of colonic diverticula and
- Bladder wall thickening adjacent to a loop of thickened intestine [6,7,14,16].

The pathognomonic finding of air within the urinary bladder contributes to the high diagnostic accuracy of CT in detecting EVF; however, false positives may occur following recent lower urinary tract instrumentation or due to active urinary tract infection with a gas-forming organism.

Closure following urinary and/or fecal diversion alone can occur with 46% of patients, particularly if they have small fistulas that are associated with trauma instead of radiation therapy [8]. Diversion is of particular importance for curtailing or controlling sepsis with major injury or if the patient is in shock. Diversion of the GU system can be accomplished by either Foley catheter or SPT (Suprapubic tube) diversion, with SPT drainage used for complete disruption of the urethra or an inability to pass a Foley [2]. Even if surgical repair is planned on initial evaluation, it is generally recommended that diversion be performed with non-destructive injuries more than 12 hours old, destructive injuries older than 6 hours, or patients needing more than 6 units of packed red blood cells for resuscitation [11].

Repair of either system typically occurs at least 1 month after diversion, particularly if the patient is too unstable to tolerate reanastomosis within 36 hours of injury, with diversion left in place for 6 to 8 weeks after repair [8]. Repair consist of closure with non-overlapping suture lines, ideally with interposed vascularized tissue [1,3]. Following injury patterns of this severity, fistulous connections between the rectum and lower urinary tract can result, posing a challenge for both accurate localization and definitive management. These patients undergo fecal and urinary diversions for few months, followed by repair of rectovesical fistula and 6 weeks later reversal of colostomy.

Primary resection of the colon with simple closure of the bladder has been recommended for chronic colovesical fistula without recurrences. It is not "foolhardy" to save the patient extra time, morbidity, and expense by doing one instead of three procedures [17].

## Conclusion

Primary repair of rectovesical injury without diversion stoma is a feasible, less morbid option for rectovesical injuries after proper assessment in expert hands. Cystoscopy and Per-rectal examination under anaesthesia helps a lot in planning and good outcome of Surgery. Intraoperative leak test should be done and if it is not ultralow anastomoses diverting stoma can be avoided.

## References

1. Najibi S, Tannast M, Latini JM (2010) Civilian gunshot wounds to the genitourinary tract: Incidence, anatomic distribution, associated injuries, and outcomes. *Urology* 76: 977–982.
2. Shewakramani S, Reed KC (2011) Genitourinary trauma. *Emerg Med Clin N Am* 29: 501–518.
3. Crispin PL, Kansas BT, Pieri PG, Fisher C, Gaughan JP, et al. (2007) Immediate postoperative complications of combined penetrating rectal and bladder injuries. *Journal of Trauma and Acute Care Surgery* 62:325–329.
4. Mileski WJ, Joehl RJ, Rege RV, Nahrwold DL (1987) One-stage resection and anastomosis in the management of colovesical fistula. *Am J Surg* 153:75–79.
5. Pollard SG, Macfarlane R, Greatorex R, Everett WG, Hartfall WG (1987) Colovesical fistula. *Ann Roy Coll Surg* 69:163.
6. Daniels IR, Bekdash B, Scott HJ, Marks CG, Donaldson DR (2002) Diagnostic lessons learnt from a series of enterovesical fistulae. *Colorectal Dis* 4:459–462.
7. Najjar SF, Jamal MK, Savas JF, Miller TA (2004) The spectrum of colovesical fistula and diagnostic paradigm. *Am J Surg* 188:617–621.
8. Al-Ali M, Kashmoula D, Saoud IJ (1997) Experience with 30 posttraumatic rectourethral fistulas: presentation of posterior transsphincteric anterior rectal wall advancement. *J Urol* 158:421–424.
9. Tonolini M, Bianco R (2012) Multidetector CT cystography for imaging colovesical fistulas and iatrogenic bladder leaks. *Insights Imaging* 3:181–187.
10. Driver CP, Anderson DN, Findlay K, Keenan RA, Davidson AI (1997) Vesico-colic fistulae in the Grampian region: presentation, assessment, management and outcome. *J R Coll Surg E* 42:182.
11. Choi WJ (2011) Management of colorectal trauma. *J Korean Soc Coloproctol* 27:166.
12. McBeath RB, Schiff Jr M, Allen V, Bottaccini MR, Miller JI, et al. (1994) A 12-year experience with enterovesical fistulas. *Urol* 44:661–665.
13. Melchior S, Cudovic D, Jones J, Thomas C, Gillitzer R, et al. (2009) Diagnosis and surgical management of colovesical fistulas due to sigmoid diverticulitis. *J Urol* 182(3):978–982.
14. Sarr MG, Fishman EK, Goldman SM, Siegelman SS, Cameron JL (1987) Enterovesical fistula. *Surg Gynecol Obstet* 164:41–48.
15. Jarrett TW, Vaughan ED (1995) Accuracy of computerized tomography in the diagnosis of colovesical fistula secondary to diverticular disease. *J Urol* 153:44–46.
16. Labs JD, Sarr MG, Fishman EK, Siegelman SS, Cameron JL (1988) Complications of acute diverticulitis of the colon: improved early diagnosis with computerized tomography. *Am J Surg* 155:331–335.
17. Ray JE, Hughes JP, Gathright JH (1976) Surgical treatment of colovesical fistula: The value of a one-stage procedure. *South Med J* 69:40–45.