

DOI: 10.36648/2254-6758.8.3.124

A Very Rare Cause of Bowel Obstruction in Children: Colocolonic Intussusception

Baykara AS*

Department of Pediatric Surgery, Eskişehir City Hospital, Eskişehir, Turkey

*Corresponding author: Aziz Serhat Baykara, Department of Pediatric Surgery, Eskişehir City Hospital, Eskişehir, Turkey, Tel: +05065048300; E-mail: asbaykara@hotmail.com

Received date: May 17, 2020; Accepted date: July 17, 2020; Published date: July 24, 2020

Citation: Baykara AS (2020) A Very Rare Cause of Bowel Obstruction in Children: Colocolonic Intussusception. J Univer Surg. Vol.8 No.3: 5

Abstract

Intussusception is a serious condition in which part of the intestine slides into an adjacent part of the intestine. This "telescoping" often blocks food or fluid from passing through. Intussusception also cuts off the blood supply to the part of the intestine that's affected, which can lead to a tear in the bowel (perforation), infection and death of bowel tissue. Intussusception is the most common cause of intestinal obstruction in children younger than 3. The cause of most cases of intussusception in children is unknown. The most common type is idiopathic ileocolic intussusception. Colocolonic intussusception is an uncommon cause of intestinal obstruction in children. We present a delayed case of colocolonic intussusception which caused colonic obstruction in a 3-year-old girl.

Initially the pain was accompanied by gradual distension of the abdomen followed by vomiting.

On arrival at our hospital, she was conscious and moderately dehydrated. Physical examination showed distended abdomen and tenderness (**Figure 1**). The child had sunken eyes, dry lips, and dry skin. Digital rectal examination revealed red currant jelly stools, and anal canal was found to be ballooned. Bowel sounds were absent.

Keywords

Intussusception; Colocolonic intussusception; Colocolic intussusception; Bowel obstruction; Children

Introduction

Intussusception is defined as the invagination of one segment of the bowel into an immediately adjacent segment. This condition is seen most commonly in the children occurs within first 3 years of life, about 90% idiopathic [1]. The most common type is idiopathic ileocolic intussusception. The Colocolonic intussusception is an uncommon cause of intestinal obstruction in children [2,3]. On rare occasions, in less than 3% of cases, colocolonic intussusception occurs and is usually associated with no pathologic lead point [4,5]. We present a delayed case of colocolonic intussusception which caused colonic obstruction in a 3-year-old girl.

Case Presentation

A 3-year-old girl was admitted to our center with complaints of abdominal pain for 8 days and repeated episodes vomiting and passing blood in the faeces with abdominal distension.

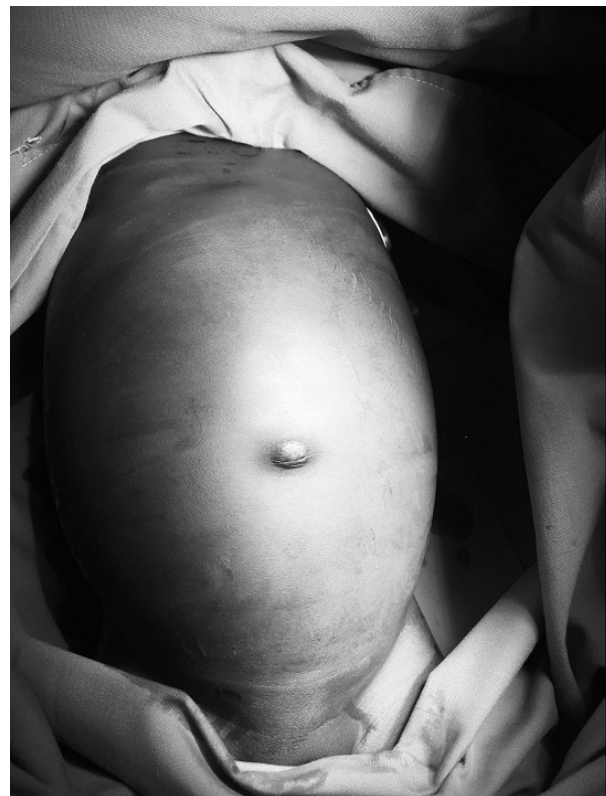

Figure 1: Pre-operative abdominal distention.

A full blood count revealed a moderate anaemia with a haemoglobin count of 7 g/dl, leucocytosis of 22,200 cells/mm³ and a thrombocytosis of 482,000 cells/mm³. An analysis of her serum electrolytes was consistent with mild hyponatremia 130 mmol/l (135–145 mmol/l), mild hypochloreaemia 92 mmol/l

(95–107 mmol/l), marked hypokalaemia 2.6 mmol/l (3.6–5.1 mmol/l) and hypomagnesaemia 12 g/l (18.2–24.3 g/l).

Initial management consisted of oxygen therapy at 2 l/min, rehydration following the WHO plan B for management of dehydration with 75 ml/kg (400 ml) of intravenous (IV) ringer's lactate solution over the next 6 h. Antibiotherapy with ceftriaxone IV injections, 50 mg/kg every 12 h; metronidazole IV injections, 30 mg/kg every 12 h. Paracetamol IV injections, 15 mg/kg (80 mg) every 6 h. Electrolytes, potassium chloride, 0.5 mEq/kg slowly over 2 h, per 12 h. She was transfused 2 boluses of cross matched and compatible erythrocyte suspension. A repeat of the serum electrolytes and haemoglobin concentration were within normal values.

The abdominal X-rays revealed dilated large bowel loops. The ultrasound of the abdomen showed mild interbowel-free fluid, dilated bowel loops and target sign.

Based on these preoperative clinico-radiological findings, a diagnosis of large bowel obstruction was made, and decision was taken to perform a laparotomy. The laparotomy was undertaken using right upper transverse incision, and the following findings were noted (**Figure 2**):

- The transverse colon had been invaginated into the descending colon and sigmoid colon.

- Invaginated colon was viewed necrotic and multiple perforations.

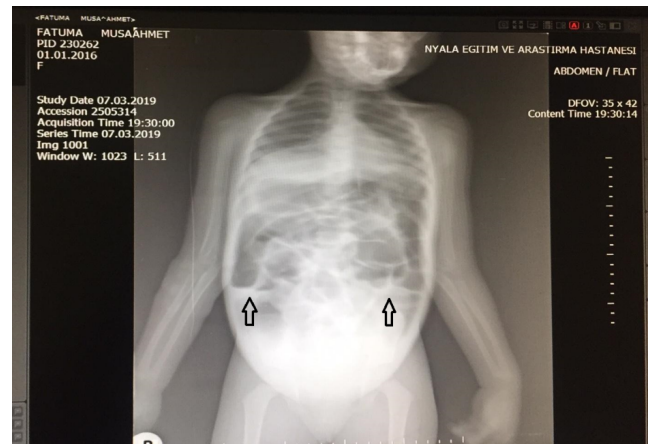


Figure 2: Air fluid levels on x-ray.

The colocolonic intussusception was not reduced manually. We performed left hemicolectomy (**Figure 3**) and the end transverse colostomy. Rectum was closed with Hartmann's procedure because emergency anastomosis was not possible.

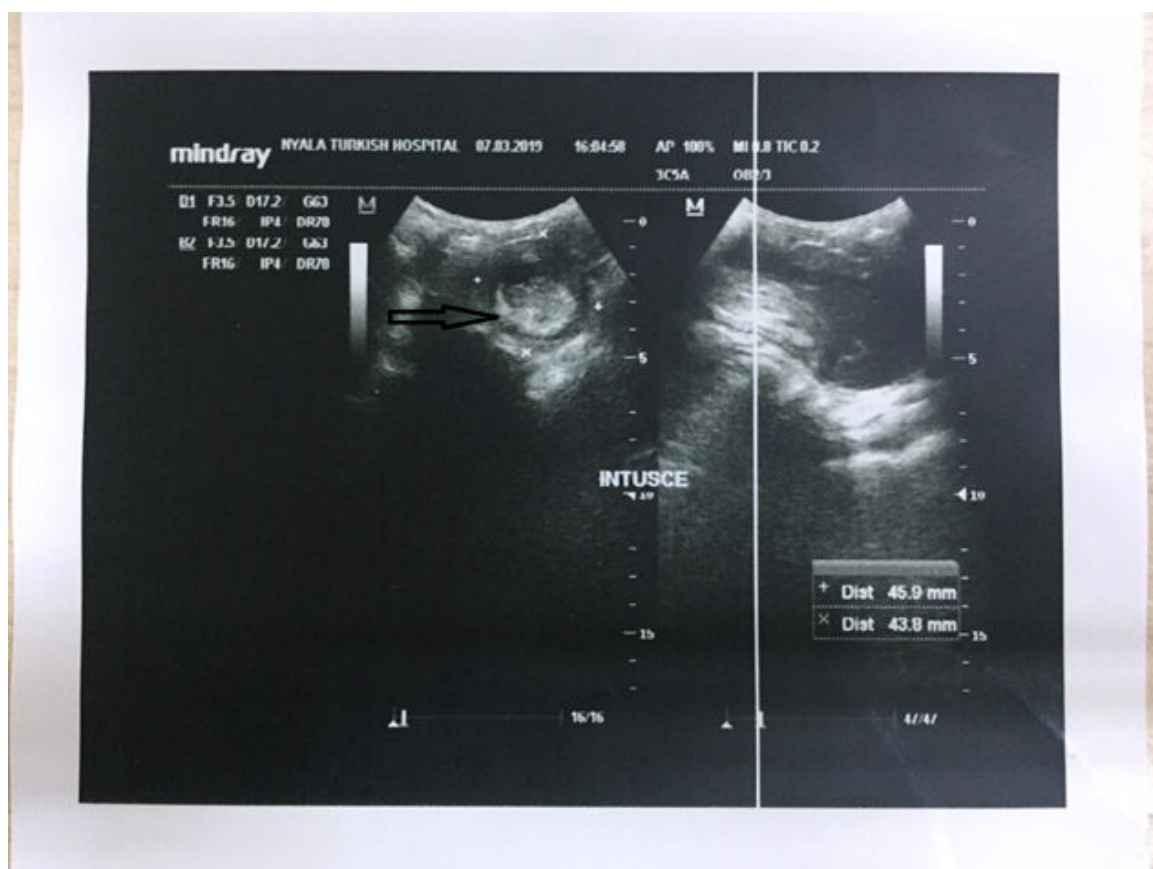


Figure 3: The ultrasound of the abdomen showed mild interbowel-free fluid, dilated bowel loops and target sign.

Post-operatively the patient was allowed oral clear fluids on the first postoperative day and semisolid diet on the second

postoperative day. The patient was discharged from the hospital on the day 6. Post-operative routine follow-up and

colostomy care were performed. After 6 months, primary anastomosis was performed and the colostomy was closed.

Discussion

Intussusception is defined as the invagination of one segment of the bowel into an immediately adjacent segment. In pediatric populations it is one of the most common abdominal emergencies. Although intussusception has been reported in all pediatric age groups, 75% to 90% of the cases occur within the first 2 years of life [3]. Most of the presentations of intussusception are of the idiopathic ileocolic type [3]. In less than 3% of cases, colocolonic intussusception occurs.

The clinical presentation of colocolonic intussusception is generally marked by abdominal pain and signs of bowel obstruction. Children classically present with acute onset colicky abdominal pain, knees drawn to chest, with excessive irritability and crying. The child may return to their usual level of activity between bouts, or they may appear listless and lethargic as the pain becomes progressively more intense. Shortly after the onset of pain, vomiting may occur. Nearly half of cases progress to stool mixed with blood and mucus, giving it a "currant jelly" appearance. Physical exam may reveal a palpable "sausage-shaped mass" in the right upper quadrant or epigastric region of the abdomen, but the mass is only detected in approximately 60% of cases [2,3]. In our case, there was distention in the abdomen, mass palpation with sausage in the abdomen, and strawberry jelly on rectal examination (**Figure 4**).

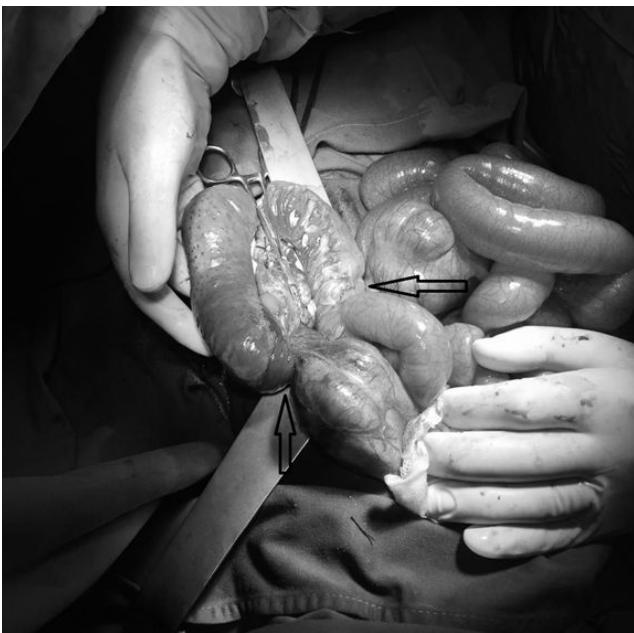

Figure 4: Intra-operative view of colocolonic intussusception.

Evaluation often starts with plain films of the abdomen (acute abdominal series). Plain films will typically reveal signs of intestinal obstruction or perforation, which may include

massively distended loops of bowel with absence of colonic gas, as well as information on the location of the obstruction in the gastrointestinal tract [5,6]. While plain films are deemed useful in the diagnosis of obstruction, they lack sensitivity and specificity for diagnosing intussusception [7,8]. In the case we presented, there were multiple levels of air fluid in the flat abdominal film. There was no air shadow due to mechanical obstruction in the lower abdomen.

Unlike plain films, the sensitivity and specificity of ultrasound in diagnosing intussusception approaches nearly 100% in experienced hands, especially in children [9]. Due to the noninvasive nature of ultrasound, it is the imaging modality of choice for evaluating children, and has been found to be a rapid, sensitive screening procedure in the assessment for intussusception. The classic feature is the target or doughnut sign caused by the edematous intussusceptum forming an external ring around the centrally based intussusceptum [10]. On the transverse view, the pseudokidney appearance is formed by the layers of the intussusception. Pseudokidney was seen on the ultrasound performed in our case (**Figure 5**).

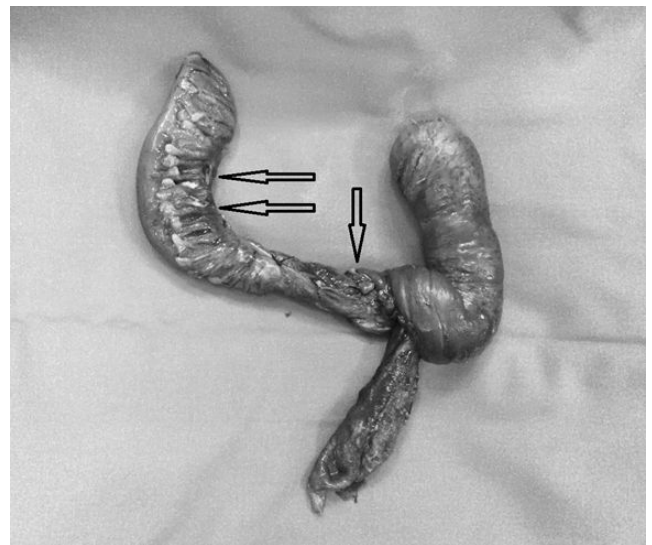


Figure 5: Excised colon segment due to necrosis and multiple perforations.

Symptoms occur due to continued peristaltic contractions of the intussuscepted segment against the obstruction. With continued invagination resulting in edema, eventually the vascular flow to the bowel becomes compromised, resulting in ischemia to the affected segment that, left untreated, can result in necrosis and perforation [3]. In the pediatric population, treatment depends on the type of intussusception. The first approach in treatment requires reduction by ultrasound-guided or fluoroscopic pneumatic or hydrostatic enema, and is successful in 85 to 90% of cases [6]. But surgery is required if there are signs of bowel necrosis [6]. When indicated, surgery may be performed laparoscopically or open, depending on the skill and experience of the surgeon. The surgeon suspects ischemia such that reduction would uncover a gangrenous segment at risk of perforation with even gentle

manipulation, reduction is ill advised and the entire segment should be resected en bloc [6]. Generally, resection of the pathologic and/or ischemic segment of bowel with creation of a primary surgical anastomosis can be performed in entero-enteric intussusceptions and right-sided colocolonic or ileocolic intussusception [6]. In instances of left-sided colonic intussusception with associated obstruction, a resection with Hartmann procedure is the generally recommended approach, although both a primary anastomosis and primary anastomosis with proximal diverting colostomy may be considered depending on the situation and risk factors for anastomotic leak [3,6].

Conclusion

In our case, the intussusceptum was gangrenous and ischemic perforation. We performed left hemicolectomy and the end colostomy. Rectum was closed with Hartman's procedure because emergency anastomosis was not possible. After 6 months, primary anastomosis was performed and the colostomy was closed. Consequently, colocolonic invagination is a very rare condition in children. Rapid evaluation of patients and appropriate surgical approach in delayed cases are life-saving.

References

1. Das A, Ralte L, Chawla AS, Arya SV, Kumar A, et al. (2013) Colocolic intussusception in an older child: A rare case report and a literature review. *Case Rep Surg*.
2. Applegate KE (2009) Intussusception in children: Evidence-based diagnosis and treatment. *Pediatr Radiol* 39: 140-143.
3. Chung JL, Kong MS, Lin JN, Wang KL, Lou CC, et al. (1994) Intussusception in infants and children: Risk factors leading to surgical reduction. *J Formos Med Assoc* 93: 481.
4. Arthur AL, Garvey R, Vaness DG (1990) Colocolic intussusception in a three-year-old child caused by a colonic polyp. *Connecticut Med* 54: 492-494.
5. Chua JH, Chui CH, Jacobsen AS (2006) Role of surgery in the era of highly successful air enema reduction of intussusception. *Asian J Surg* 29: 267-273.
6. Marsicovetere P, Ivatury SJ, White B, Holubar SD (2017) Intestinal intussusception: Etiology, diagnosis, and treatment. *Clin Colon Rect Surg* 30: 30-39.
7. West KW, Stephens B, Vane DW, Grosfeld JL (1987) Intussusception: Current management in infants and children. *Surg* 102: 704-710.
8. Mrak K (2014) Uncommon conditions in surgical oncology: Acute abdomen caused by ileocolic intussusception. *J Gastrointest Oncol* 5: E75.
9. Wiersma F, Allema JH, Holscher HC (2006) Ileoileal intussusception in children: Ultrasonographic differentiation from ileocolic intussusception. *Pediatr Radiol* 36: 1177-1181.
10. Boyle MJ (1993) Ultrasonic diagnosis of adult intussusception. *Am J Gastroenterol* 88: 617-618.