

An Unusual Cause of Tachycardia: Focal Non-convulsive Status Epilepticus Following Acute Head Trauma

Bruce J. Grattan^{1*} and John Leskovan²

- 1 Department of Emergency Medicine, Bon Secours Mercy/St. Vincent Medical Center, Toledo, Ohio, USA
- 2 Department of Trauma Surgery, Bon Secours Mercy/St. Vincent Medical Center, Toledo, Ohio, USA

Abstract

Non-convulsive status epilepticus has traditionally been thought of as a rare condition. There is little data regarding its true incidence but evidence suggests it is far more common than once believed. Non-convulsive status epilepticus can have an array of presentations and can be a diagnostic enigma for those unaware of its existence or those who believe, as it was once taught, that this condition is isolated to critically ill patients in the intensive care unit. Herein, we discuss the case of a patient with a focal traumatic brain injury who was found to be in Non-convulsive status epilepticus. This condition is one that physicians need to consider, especially those physicians caring for patients with traumatic brain injury.

Keywords: Trauma; Focal status epilepticus; Non-convulsive status epilepticus; Traumatic brain injury; Acute head injury

*Corresponding author:

Bruce J. Grattan

✉ bruce.grattan@gmail.com;
bjgrattan@mercy.com

Department of Emergency Medicine, Bon Secours Mercy/St. Vincent Medical Center, Toledo, Ohio, USA.

Tel: +14192514724

Fax: 1-419-251-2698

Citation: Grattan BJ, Leskovan J (2021) An Unusual Cause of Tachycardia: Focal Non-convulsive Status Epilepticus Following Acute Head Trauma. Arch Med Vol.13 No.2:7

Received: January 20, 2021; **Accepted:** February 03, 2021; **Published:** February 10, 2020

Introduction

Non-convulsive Status Epilepticus (NCSE) is defined as a period of ongoing seizure activity which may present as an alteration in behaviour or mental status, albeit in the absence of motor activity [1]. There are two recognized classifications of NCSE including absence status epilepticus (primary generalized) and complex partial (secondary generalized). NCSE has, in years past, been considered a rare condition. This is in large part the result of the fact that there have been very limited data from which to accurately describe the incidence of NCSE. Historically, most data have been drawn from single centre studies with small sample sizes [2]. Nevertheless, the incidence has been estimated to be 15-20/100,000 cases per year [3]. These values may underestimate the true incidence. In one study of patients who presented to the Emergency Department (ED) with Altered Mental Status (AMS) and without convulsions who received EEG studies, 37% were found to have NCSE [4]. Notably, nearly half of patients with NCSE will not have any history of epilepsy [5]. While in years past NCSE was thought to have an incidence of 3%, subsequent studies have shown it to be more common ranging from 16-43% of all status epilepticus cases [6-9]. This is notable as the morbidity and mortality of NCSE is estimated to be 39 and 18% respectively [10].

Case Presentation

Herein, we present a case of a 49-year-old male who presented to the Emergency Department (ED) by Emergency Medical Services (EMS) after being found down outside. The patient was intoxicated with an ethanol level of 459 mg/dl. The patient was unable to clearly recall the preceding events but alleges he may have been kicked and/or struck in the head with a bottle. The patient's chief complaint was rib pain and headache. His GCS was 15 and vitals were normal with blood pressures of 116/74, heart rate of 60 beats per minute, temperature 97.4 degrees F, respiratory rate 14 breaths per minute, SpO₂ 100% on room air. The patient had no significant medical history and specifically no history of seizures. He reported drinking alcohol and smoking tobacco and marijuana daily. On physical exam, there was tenderness to palpation of the left chest wall and generalized abdominal tenderness. His speech was slurred and he appeared clinically intoxicated. His neurological exam is without focality. The patient underwent Computed Tomography (CT) imaging of his head, cervical spine, chest,

abdomen and pelvis with findings of a traumatic subarachnoid hemorrhage in the right frontotemporal region (Hess and Hunt 3, modified Fischer grade 1) with a hyper-density along the temporal operculum in a gyral pattern. Given these findings and concern for acute alcohol withdrawal, the patient was admitted to the Intensive Care Unit (ICU) for continued monitoring. He was started on levetiracetam 500 mg po BID for 7 days. A follow up CT brain was stable in appearance, and on Hospital Day (HD) 2 the patient developed multiple intermittent and random episodes of sinus tachycardia with a rate of 130s-150's. These episodes lasted seconds to minutes during which the patient was without any hemodynamic compromise and he remained asymptomatic. A 12-lead ECG was obtained just after an episode which showed a sinus rhythm at a rate of 92 beats/min, with normal axis and without any acute changes. The qt -corrected was noted to be prolonged at 497msec and two grams of IV magnesium sulphate was given. After an unremarkable workup for causes of sinus tachycardia, cardiology recommended metoprolol tartrate 12.5 mg po bid. On the evening of HD 2, the patient had repeated episodes of sinus tachycardia now associated with upward gaze and tonic-clonic hand motions concerning for seizures. Surprisingly, throughout these episodes the patient was interactive and cooperative, without any confusion or postictal state. The patient was placed on Long Term Monitoring for Epilepsy (LTME). 21 EEG electrodes were placed according to the International 10/20 System. A single EKG electrode was also placed. Video recording was time-locked with EEG recording. The EEG was interpreted by a board certified epileptologist. Upon EEG initiation, the background was noted to demonstrate a continuous slow rhythm largely in the delta frequency of 1-3Hz, ranging between 10-50 uV. There was no posterior dominant rhythm and no eye opening/closing artifacts. Spontaneous variability was present. The interictal rhythm was continuous, slow, generalized and lateralized to right. At times there was evidence of asymmetry, there were faster and slower activities on the right, particularly in the right frontal/temporal region when compared to left side. During the patient's continuous video EEG monitoring EEG evidence of seizures in right hemisphere were captured from beginning of the recording without any clear clinical signs. There was also evidence of diffuse encephalopathy and structural abnormality of the right hemisphere, consistent with patient's known right SAH and haemorrhagic contusion. The patient was in focal EEG status since the initiation of the recording while the patient exhibited no clinical signs of seizure. Hyperventilation and photic stimulation were not performed. Single lead EKG showed regular, heart rate at 60 sec per minute. As a result of these findings, the patient was loaded with 3 grams of levetiracetam and 1mg of lorazepam IV and continued on maintenance, 1 g levetiracetam BID. Once the patient was loaded, there was no recurrence of seizure (**Figure 1**).

Discussion

There are a variety of known etiologies of NCSE including electrolyte abnormalities, hypoxic-ischemic encephalopathy, Traumatic Brain Injury (TBI) and acute hormonal disturbances [11]. Nearly 75% of patients with NCSE have no identifiable changes on physical examination other than a decrease in responsiveness

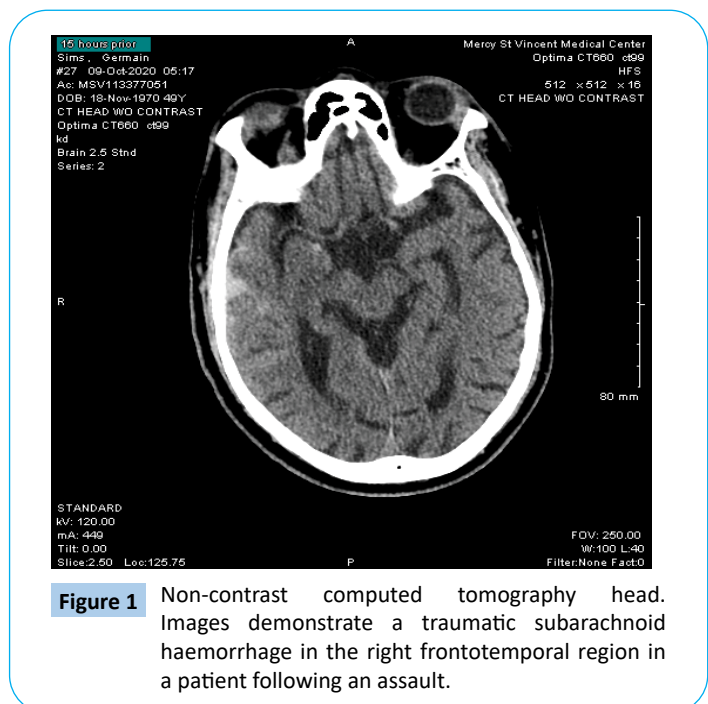


Figure 1 Non-contrast computed tomography head. Images demonstrate a traumatic subarachnoid haemorrhage in the right frontotemporal region in a patient following an assault.

[12,13] which can often readily be attributed to another etiology. NCSE can present with negative symptoms including confusion and lethargy or subtle and often overlooked positive symptoms including blinking, nystagmus, facial twitching or tremulousness. In a small study of 48 patients, abnormal ocular movements were shown to be a specific clinical finding in NCSE as compared with patient without NCSE [14]. While much of the data on NCSE is drawn from populations of patients who are acutely ill or comatose, these data suggest that patients with NCSE may have a worse prognosis as compared with convulsive status epilepticus [15,16]. Similarly, it has been demonstrated that up to 14 percent of patients treated for convulsive status epilepticus persist in NCSE upon initiation of EEG monitoring [15]. In contrast to critically ill patients in the ICU setting, NCSE outside the ICU can present with a plethora of subtle clinical manifestations [17] NCSE can be difficult to distinguish from absence seizure [18], with EEG being critical to the diagnosis where 50% of Non-convulsive seizures are identified within the first hour of EEG initiation [19].

The scarcity of data regarding NCSE extends to treatment with very little literature being available regarding the most efficacious treatment modalities and without any randomized trials providing evidence to support treatment recommendations [20]. NCSE management is not addressed in the status epilepticus guidelines published by the Neurocritical Care Society [21], resulting in much variation in care and even recognition of this condition amongst clinicians.

NCSE and traumatic brain injury

Traumatic Brain Injury (TBI) is a leading cause of morbidity and mortality [22,23]. TBI can be defined as brain injury due to external mechanical forces which may be blunt or penetrative [22,24]. The pathophysiology of TBI is described as a primary insult (structural damage from the initial force) and a secondary injury which

ensues involving oxidative stress, inflammatory changes and excitotoxicity [25]. Within hours after TBI, peripherally circulating neutrophils are recruited and play an instrumental role in the early pathogenesis through mediating the production of edema, the release of neurotoxic proteases and the production of inflammatory cytokines [26,27]. Aside from the de novo synthesis of cytokines, these chemical mediators are also released from storage locally in glia [28]. Among TBI patients; seizures are not uncommon and are an important component of prognosis. Nearly 25% of patients with traumatic brain injuries who have a seizure in the first week after injury, will progress to have subsequent seizures [29]. The development of epilepsy after TBI has a broad incidence ranging from 4.4-53% depending on the population studied [30]. In a retrospective analysis of 451 adult TBI patients 9.3% had EEG evidence of electrographic status epilepticus with 19% being associated with intracerebral haemorrhage including trauma [31,32].

NCSE may be particularly harmful among patients with TBI. As

animal data suggests, the acutely injured brain has greater sensitivity to damage posed by NCSE [33,34]. Evidence from human studies supports these data with levels of extracellular glutamate and the lactate to pyruvate ratio (well-known markers of brain injury) being elevated among TBI patients with seizures [35-39]. NCSE is also associated with elevated levels of neuron specific enolase [40]. It is difficult to distinguish whether the brain damage seen in this condition is a cause or result of NCSE.

Conclusion

This case exemplifies an anomalous cause of sinus tachycardia. As described, patients with TBI are at high risk for seizures including those which may present without typical clinical motor findings. This unique case of focal status epilepticus related to acute head trauma highlights the need for physicians to be cognizant of this condition and to have a high clinical suspicion for NCSE in patients with TBI who are presenting with disparate signs and symptoms.

References

- 1 Shneker BF, Fountain NB (2003) Assessment of acute morbidity and mortality in nonconvulsive status epilepticus. *Neurology* 61: 1066-1073.
- 2 Rudin D, Grize L, Schindler C, Marsch S, Ruegg S, et al. (2011) High prevalence of nonconvulsive and subtle status epilepticus in an ICU of a tertiary care center: A three-year observational cohort study. *Epilepsy Res* 96: 140-150.
- 3 Sutter R, Semmlack S, Kaplan PW (2008) Non-convulsive status epilepticus in adults: an overview. *Schweiz Arch Neurol Psychiatr* 159: 53-83.
- 4 Privitera MD, Strawsburg RH (1994) Electroencephalographic monitoring in the emergency department. *Emerg Med Clin North Am* 12: 1089-1090.
- 5 Knake S, Rochon J, Fleischer S (2006) Status epilepticus after stroke is associated with increased long-term case fatality. *Epilepsia* 47: 2020-2026.
- 6 DeLorenzo RJ, Hauser WA, Towne AR, Boggs JG, Pellock JM, et al. (1996) A prospective, population-based epidemiologic study of status epilepticus in Richmond, Virginia. *Neurology* 46: 1029-1035.
- 7 Vignatelli L, Tonon C, D'Alessandro R (2003) Bologna Group for the Study of Status E: Incidence and short-term prognosis of status epilepticus in adults in Bologna, Italy. *Epilepsia* 44: 964-968.
- 8 Knake S, Rosenow F, Vescovi M, Oertel WH, Mueller HH, et al. (2001) Incidence of status epilepticus in adults in Germany: A prospective, population-based study. *Epilepsia* 42: 714-718.
- 9 Coeytaux A, Jallon P, Galobardes B, Morabia A (2000) Incidence of status epilepticus in French-speaking Switzerland: (EPISTAR). *Neurology* 55: 693-697.
- 10 Jordan KG (1999) Non-convulsive status epilepticus in acute brain injury. *J Clin Neurophysiol* 16: 332-340.
- 11 Vespa PM, Miller C, McArthur D (2007) Nonconvulsive electrographic seizures after traumatic brain injury result in a delayed, prolonged increase in intracranial pressure and metabolic crisis. *Crit Care Med* 35: 2830-2836.
- 12 Meierkord H, Holtkamp M (2007) Non-convulsive status epilepticus in adults: clinical forms and treatment. *Lancet Neurol* 6: 329-339.
- 13 Chong DJ, Hirsch LJ (2005) Which EEG patterns warrant treatment in the critically ill? Reviewing the evidence for treatment of periodic epileptiform discharges and related patterns. *J Clin Neurophysiol* 22: 79-91.
- 14 Husain AM, Horn GJ, Jacobson MP (2003) Non-convulsive status epilepticus: Usefulness of clinical features in selecting patients for urgent EEG. *J Neurol Neurosurg Psychiatry* 74: 189-191.
- 15 DeLorenzo RJ, Waterhouse EJ, Towne AR, Boggs JG, Garnett L, et al. (1998) Persistent nonconvulsive status epilepticus after the control of convulsive status epilepticus. *Epilepsia* 39: 833-840.
- 16 Treiman DM, Meyers PD, Walton NY, Collins JF, Colling C, et al. (1998) A comparison of four treatments for generalized convulsive status epilepticus. Veterans Affairs Status Epilepticus Cooperative Study Group. *N Engl J Med* 339: 792-798.
- 17 Kaplan PW (1999) Assessing the outcomes in patients with nonconvulsive status epilepticus: nonconvulsive status epilepticus is underdiagnosed, potentially over-treated, and confounded by comorbidity. *J Clin Neurophysiol* 16: 341-352.
- 18 Kaplan PW (1996) Nonconvulsive status epilepticus in the emergency room. *Epilepsia* 37: 643-650.
- 19 Jette N, Claassen J, Emerson RG, Hirsch LJ (2006) Frequency and predictors of nonconvulsive seizures during continuous electroencephalographic monitoring in critically ill children. *Arch Neurol* 63: 1750-1755.
- 20 Jordan KG, Hirsch LJ (2006) Non-convulsive status epilepticus (NCSE), treats to burst-suppression: Pros and cons. *Epilepsia* 1: 41-45.
- 21 Brophy GM, Bell R, Claassen J, Alldredge B, Bleck TP, et al. (2012) Guidelines for the evaluation and management of status epilepticus. *Neurocrit Care* 17: 3-23.
- 22 Potts MB, Koh SE, Whetstone WD, Walker BA, Yoneyama T, et al. (2006) Traumatic injury to the immature brain: Inflammation, oxidative injury, and iron-mediated damage as potential therapeutic targets. *NeuroRx* 3: 143-153.

- 23 Thurman DJ (2016) The Epidemiology of Traumatic Brain Injury in Children and Youths: A Review of Research Since 1990. *J Child Neurol* 31: 20-27.
- 24 Maas AL, Stocchetti N, Bullock R (2008) Moderate and severe traumatic brain injury in adults. *Lancet Neurol* 7: 728-741.
- 25 Schouten JW (2007) Neuroprotection in traumatic brain injury: A complex struggle against the biology of nature. *Curr Opin Crit Care* 13: 134-142.
- 26 Hudome S, Palmer C, Roberts RL, Mauger D, Housman C, et al. (1997) The role of neutrophils in the production of hypoxic-ischemic brain injury in the neonatal rat. *Pediatr Res* 41: 607-616.
- 27 Owen CA, Campbell EJ (1999) The cell biology of leukocyte-mediated proteolysis. *J Leukoc Biol* 65: 137-150.
- 28 Morganti-Kossmann MC, Rancan M, Stahel PF, Kossmann T (2002) Inflammatory response in acute traumatic brain injury: a double-edged sword. *Curr Opin Crit Care*. 8: 101-115.
- 29 Englander J, Cifu DX, Diaz-Arrastia R (2014) Information/education page. Seizures and traumatic brain injury. *Arch Phys Med Rehabil*. 95: 1223-1234.
- 30 Frey LC (2003) Epidemiology of posttraumatic epilepsy: a critical review. *Epilepsia* 44: 11-17.
- 31 Alroughani R, Javidan M, Qasem A, Alotaibi N (2009) Non-convulsive status epilepticus; the rate of occurrence in a general hospital. *Seizure* 18: 38-42.
- 32 Towne AR, Waterhouse EJ, Boggs JG, Garnett LK, Brown AJ, et al. (2000) Prevalence of nonconvulsive status epilepticus in comatose patients. *Neurology* 54: 340-345.
- 33 Jaitly R, Sgro JA, Towne AR, Ko D, DeLorenzo RJ (1997) Prognostic value of EEG monitoring after status epilepticus: a prospective adult study. *J Clin Neurophysiol* 14: 326-334.
- 34 Young GB, Jordan KG, Doig GS (1996) An assessment of non-convulsive seizures in the intensive care unit using continuous EEG monitoring: An investigation of variables associated with mortality. *Neurology* 47: 83-89.
- 35 Vespa PM, O'Phelan K, Shah M, Mirabelli J, Starkman S, et al. (2003) Acute seizures after intracerebral hemorrhage: A factor in progressive midline shift and outcome. *Neurology* 60: 1441-1446.
- 36 Bergsneider M, Hovda DA, Shalmon E (1997) Cerebral hyperglycolysis following severe traumatic brain injury in humans: a positron emission tomography study. *J Neurosurg* 86: 241-251.
- 37 Bullock R, Zauner A, Myseros JS, Marmarou A, Woodward JJ, et al. (1995) Evidence for prolonged release of excitatory amino acids in severe human head trauma. Relationship to clinical events. *Ann N Y Acad Sci* 765: 290-297.
- 38 Vespa P, Prins M, Ronne-Engstrom E, Shalmon E, Caron M, et al. (1998) Increase in extracellular glutamate caused by reduced cerebral perfusion pressure and seizures after human traumatic brain injury: A microdialysis study. *J Neurosurg* 89: 971-982.
- 39 Vespa P, Tubi M, Claassen J, Buitrago-Blanco M, McArthur D, et al. (2016) Metabolic crisis occurs with seizures and periodic discharges after brain trauma. *Ann Neurol* 79: 579-590.
- 40 Correale J, Rabinowicz AL, Heck CN, Smith TD, Loskota WJ, et al. (1998) Status epilepticus increases CSF levels of neuron-specific enolase and alters the blood-brain barrier. *Neurology* 50: 1388-1391.