

D2 Malocclusion with Complete Deep Bite **Amal H Abuaffan**

Received: May 06, 2016; Accepted: May 09, 2016; Published: May 11, 2016

Faculty of Dentistry, University of Khartoum, Sudan

Image Case:

Intra oral view of case with:
Class II D2 Angle malocclusion
Complete deep bite
Supplemental lateral lower incisors with 90 degree rotation

Corresponding author: Amal H Abuaffan

✉ amalabuaffan@yahoo.com

Faculty of Dentistry, University of Khartoum, Sudan.

Tel: 249 91 296 1526

Citation: Abuaffan AH. Anterior Open Bite with Midline Diastema. Ann Clin Lab Res. 2016, 4:2.

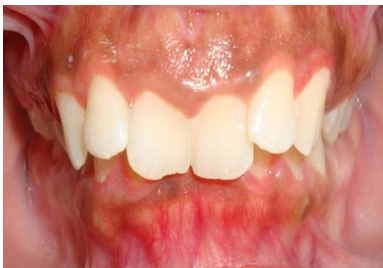

Figure 1 Frontal view.

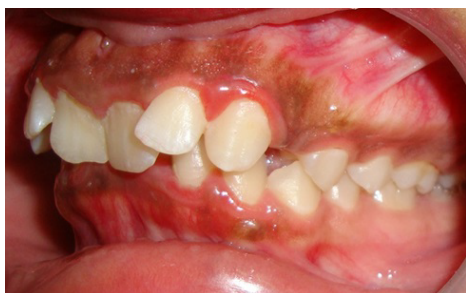

Figure 2 Left side.

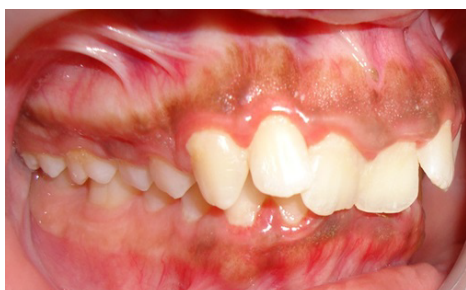

Figure 3 Right side.

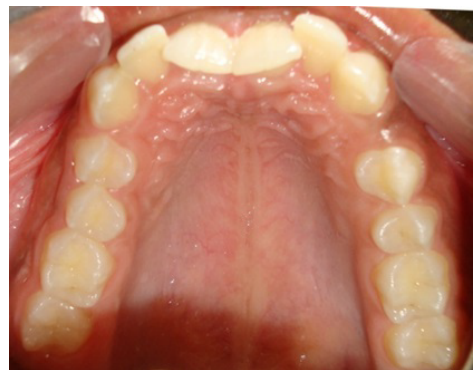

Figure 4 Upper jaw.

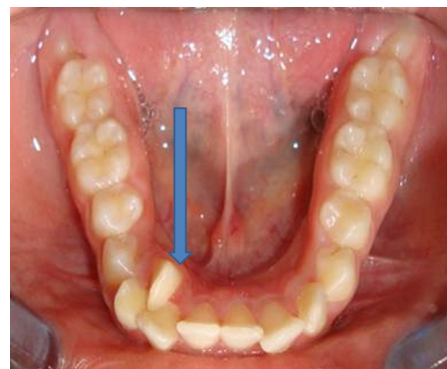


Figure 5 Lower jaw.