

# Does Nature through the Predetermined Patterns of Lung Cancer Metastases Provide Strong Evidence for the Existence of an Intrinsic “Lymphogenous Metastasis Selectivity Factor?”

**Wilson I. B. Onuigbo**

Department of Pathology, Medical Foundation and Clinic, 8 Nsukka Lane, Enugu 40001, Nigeria

## Corresponding author:

Wilson I. B. Onuigbo

✉ wilson.onuigbo@gmail.com

Department of Pathology, Medical Foundation and Clinic, 8 Nsukka Lane, Enugu 40001, Nigeria.

Tel: 2348037208680

**Citation:** Onuigbo WIB. Does Nature through the Predetermined Patterns of Lung Cancer Metastases Provide Strong Evidence for the Existence of an Intrinsic “Lymphogenous Metastasis Selectivity Factor?”. Arch Cancer Res. 2016, 4:1.

## Abstract

Colonization patterns in cancer have long been fascinating. As far back as 1879, a striking example was reported as “Case of unilateral cancer.” A century later by 1975, Ariel reported a patient with exclusively right-sided pigmented cancer. Fortunately, chance, led me to do research under Professor D. F. Cappell at the University Department of Pathology based at the Glasgow Western Infirmary. The first fruit was my 1957 final year publication on the topographical analysis of 1000 cases of lung cancer autopsies; this appeared in the British Journal of Cancer. In turn, this led my Professor to draw glowing attention to it in a famous Textbook in 1958. Fortunately, my work blossomed, on account of fruitful safaris to the other Scottish Medical Schools. Thereafter, many publications on lymph-borne colonization patterns appeared. On the basis of them, let me conclude that the predictable orderliness of lymph-borne metastasis is indicative of the workings of an underlying intrinsic directional Factor. In sum, it may fittingly be named the “Lymphogenous Metastasis Selectivity Factor” (LMSF). Hence, it is hypothesized that its verification and identification could conduce to target therapy following breakthroughs in translational laboratories.

**Received:** January 14, 2016; **Accepted:** January 29, 2016; **Published:** February 01, 2016

## Introduction

Important themes are met in the long literature of bodily cancer colonization. It included a unilaterally disposed case dating to 1879 [1]. After the passage of a century in 1975, Ariel’s own encounter [2] was in someone in whom there were “innumerable” pigmented deposits and yet “The left side of the body remained completely inviolate [2].” “It was,” he had declared, “as if an imaginary line had been drawn vertically front and back to repel any invasion from right to left.” Personal interest in such dimensional data led to my final year publication based on the topographical analysis of 1000 cases of lung cancer. It appeared in the British Journal of Cancer in 1957 [3]. Thereafter, in the 1958 Edition of the famous Muir’s Text-Book of Pathology, Prof Cappell remarked thus: “Onuigbo, working in my Department, has shown that spread to the adrenals is predominantly to the ipsilateral side and this distribution indicates the lymphatics rather than the arterial blood stream as the usual route of metastases [4].” Next,

instructive autopsy data were added from other Medical Schools during safaris undertaken in Scotland as follows:

### Examples of unilateral spread of lung cancer in Scotland

Three cases are illustrative. They are illumined with italics for both the primary origins and the various colonies as follows:

i *Glasgow Royal Infirmary (PM 8/1945). Left lung origin. On the under aspect of the left cerebellar lobe there is a secondary tumour nodule. There is also a single secondary tumour nodule in the left lobe of the liver and another in the left adrenal.*

ii *Edinburgh Royal Infirmary (PM 6/1946). Left lung origin. The lymph nodes in relation to the left hilum are replaced by cancerous tissue. Situated in the lower anterior aspect of the left lobe of the liver is a solitary spheroidal tumour deposit. The left adrenal contains tumour tissue. In the brain, a very large mass of tumour is situated in the left frontal and parietal lobes*

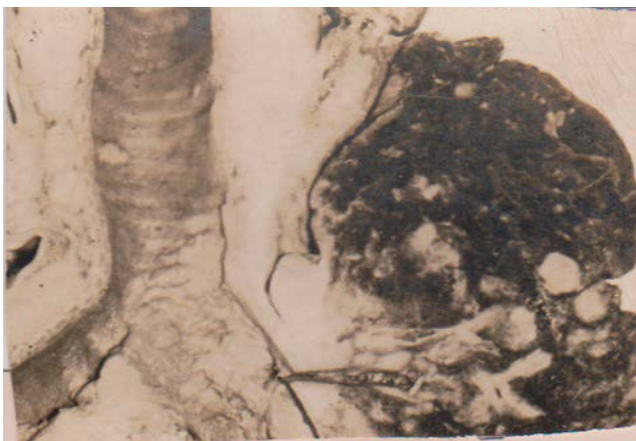iii *Aberdeen Royal Infirmary* (PM 92/1952). *Right lung* origin. Two small tumour nodules are seen, on section, in the *right* frontal lobe; a similar nodule is found in the *right* occipital lobe. On section, numerous secondary deposits of varying size are found scattered throughout the liver, more especially in the *right* lobe. The *right* adrenal is extensively invaded and weighs 130 gm. The left is free.

## Related Patterns

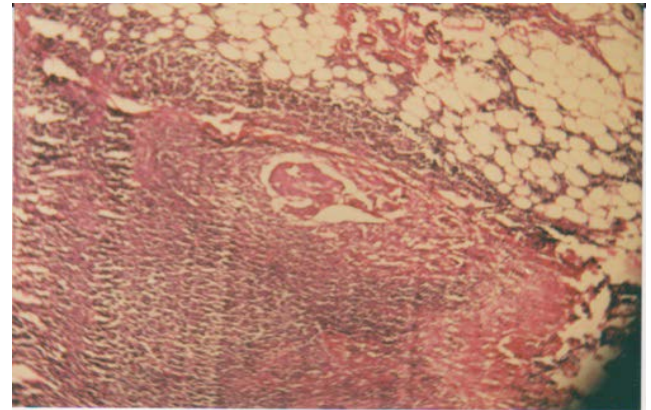
Undoubtedly, these pointed patterns are, as Professor Scarf [5] concluded, a reflection of the grafting experiments done by Nature in man. In this context, the prevailing panorama was delineated personally with Scottish necropsy series which actually continued for years. The latest was entitled "The prevalence of endobronchial metastases in lung cancer in Scotland [6]." Thus, **Figure 1** depicts whitish left lung tumor sheathing the lower trachea and showing coalesced endobronchial metastases with discrete extension just across the carina. This was a sequel to my possession of the copies of the 100 autopsies performed personally during my Postgraduate Training Program at the University Department of Pathology based at the Glasgow Western Infirmary. Incidentally, that Institution was aptly described historically in the Bulletin of the History of Medicine [7] as being second to none in Britain.

The postmortem materials were obtained with the mono-block formalin-fixation method whose enduring feature has been the long preservation of tissues from the neck to the pelvis [8]. Incidentally, although there is now the predatory problem of who takes possession of laboratory specimens [9], those packaged preciously by my Master were shipped by sea to me at Enugu, my base in the Capital City of the Eastern Region of Nigeria which is deep in the Dark Continent!

In this context, the clear colonization patterns repeatedly pointed to the need to trace the footsteps of lymph-borne cancer cells all the way from the lung to, say, the abdominal lymph nodes [10]. In particular, I noted that the earliest deposit was present beneath the node's convex border, i.e, where lymph flows in, (**Figure 2**). Accordingly, I theorized six times that new lymphatic vessels were being formed. Nowadays, this is being called



**Figure 1** Section of left lung tumor shows sheathing of the trachea with deposits partially coalescent in the ipsilateral bronchus and isolated in the proximal right bronchus.



**Figure 2** Section shows abdominal fat above lymph node whose convex capsule exhibits a subcapsular lymphatic channel containing cancer colony.

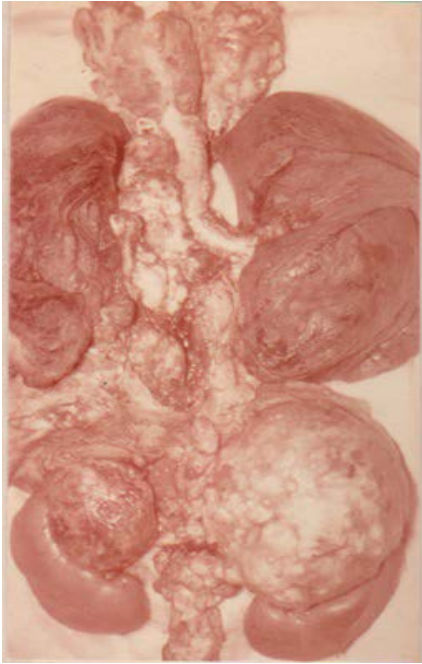"Lymphangiogenesis," a phenomenon on which I have provided a review [11].

I have also documented how contralateral neck nodes are involved [12], this being very important in scalene node surgery [13]. Furthermore, despite the long doubt spanning many decades [14,15], as to how cancer spreads to the pancreas and its abutting lymph nodes, my special mono-block maneuver confirmed the reality of the impact of lymphangiogenesis there [16]. For examples, **Figure 3** draws attention to the definitely organized meanderings due to lymphangiogenesis. Thus, note how the *right* lung tumor metastasized upwards to the *left* sided neck nodes and downwards to the left sided adrenal gland, whereas the mediastinal node invasion continued to remain ipsilateral.

Among the laws of lymphatic metastasis, which I proposed in 1964, the 5th was on the "skip" phenomenon [17]. Nowadays, researches on it have continued. Thus, according to Kim [18], there are drainage patterns "such as skip metastasis and micrometastasis, (which) still remain the subject of investigation." Likewise, Misthos [19] and associates analyzed its clinical significance and prognosis. What of its pathological significance?

## Discussion

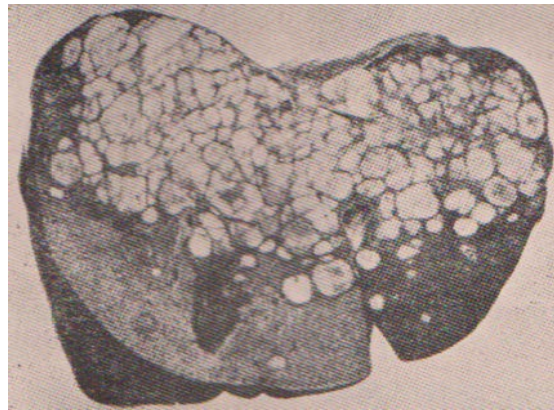The element of skipping presupposes choice of a particular soil. Actually, for centuries, the old masters questioned the attributes of "Site" and "Soil [20]. Recently, Kaplan and her group [21] wondered about this phenomenon in their research paper entitled "Preparing the 'soil': The premetastatic niche." As they put it, "Current focus on cancer metastasis has centered on the intrinsic factors regulating the cell autonomous homing of the tumor cells to the metastatic site." I am persuaded that this hitherto unknown "homing element" is the present proposed "Lymphogenous metastasis selectivity factor" (LMSF). For example, **Figure 4**. Illustrates the multiple deposits formed in a lung cancer case by way of the LMSF in the subjacent liver [22]. Surely, this pattern is *not* that of the haphazard distribution expected from the arterial system.



**Figure 3** Mono-block formalin-fixed specimen showing the lungs; the primary right tumor is next to the coalesced mediastinal lymph node deposits. The selective association is apparent from the cross over not only to the left neck nodes but also to the left adrenal gland.

## Conclusion

LMSF naturally directs positional activities during metastases. Consequently, what remains to be done is clear. It is, indeed, to hypothesize that this Factor is what is responsible for the well-directed natural phenomena which are traceable in lymphatic metastasis. In all probability, target therapy will result from recondite researches carried out on it, especially in the recently sprouting Translational Institutions [23].



**Figure 4** Vertical section of the liver showing the abundance of cancer nodules in its upper portion in a case of lung cancer; it is unlike expectations from haphazard scatter by way of the arterial system.

## References

- 1 Braidwood PM (1879) Case of unilateral cancer. *Trans Pathol Soc Lond* 30: 413-416.
- 2 Ariel IM (1975) Disseminated melanoma with unique unilateral distribution. *Cancer* 36: 2143-2146.
- 3 Onuigbo WIB (1957) Some observations on the spread of lung cancer in the body. *Br J Cancer* 11: 175-180.
- 4 Cappell DF (1958) *Muir's Text-Book of Pathology*, London: Arnold 505.
- 5 Scarf RW (1948) The morbid anatomist and cancer research. *Proc Roy Soc Med* 42: 19-24.
- 6 Onuigbo WIB (2014) Prevalence of endobronchial metastases in lung cancer in Scotland. *Ann Saudi Med* 34: 68-69.
- 7 Jacyna LS (1988) The laboratory and the clinic: the impact of pathology on surgical diagnosis in the Glasgow Western Infirmary, 1875-1910. *Bull Hist Med* 62: 384-406.
- 8 Onuigbo WB (1963) A mono-block formalin-fixation method for investigating cancer metastasis. *Z Krebsforsch* 65: 209-210.
- 9 Furness PN (2001) Research using human tissues – a crisis of supply? *J Pathol* 195: 277-284.
- 10 Onuigbo WB (1963) A modified theory of retrograde lymphatic metastasis in lung cancer. *Br J Dis Chest* 57: 120-125.
- 11 Onuigbo WB (2014) Lymphangiogenesis in cancer: A Review. *Biochem Physiol* 3: 3.
- 12 Onuigbo WB (1962) Contralateral cervical node metastases in lung cancer. *Thorax* 17: 201-204.
- 13 Brantigan JW, Brantigan CO, Brantigan OC (1973) Biopsy of nonpalpable scalene lymph nodes in carcinoma of the lung. *Am Rev Resp Dis* 107(6): 962-974.
- 14 Wilks S, Moxon W (1875) *Lectures on pathological anatomy*. (2<sup>nd</sup>edn). London: Churchill 179.
- 15 Robbins SL (1959) *Textbook of pathology*, London: Saunders, p. 1179.
- 16 Onuigbo WB (1966) Lung cancer metastasis to the pancreas and its surrounding nodes. *Br J Dis Chest* 60: 152-155.
- 17 Onuigbo WB (1964) Lymph node metastases in lung cancer. *Geriatrics* 19: 380-388.
- 18 Kim AW (2009) Lymph node drainage patterns and micrometastasis in lung cancer. *Semin Thorac Cardiovasc Surg* 21: 298-308.
- 19 Misthos P, Sepsas E, Athanassiadi K (2004) Skip metastases: analysis of their clinical significance and prognosis in the IIIA stage of non-small cell lung cancer. *Euro J Cardio-Thorac Surg* 25: 502-503.
- 20 Onuigbo WIB (1975) The origins of the soil theory of cancer metastasis. *Materia Medica Polona* 7: 254-255.
- 21 Kaplan RN, Rafii S, Lyden D (2006) Preparing the "soil": The premetastatic niche. *Cancer Res* 66: 11089-11093.
- 22 Onuigbo WB (1976) Cluster patterns of liver deposits in lung cancer. *Indian J Chest Dis* 18: 183-185.
- 23 Woolf SH (2008) The meaning of translational research and why it matters. *J Am Med Assoc* 299: 211-213.