

Eltrombopag – A Cost-Effective Single Oral Therapeutic Agent Avoiding Splenectomy in Steroid-Resistant Immune Thrombocytopenic Purpura

Abdul Jalal MJ,
Mohammed Iqbal KM,
Nusaiba K and Basheer S

Department of Internal Medicine and Rheumatology, VPS Lakeshore Hospital, Kochi, Kerala, India

Abstract

Immune Thrombocytopenic Purpura (ITP) is an autoimmune disorder with isolated thrombocytopenia marked by peripheral blood platelet count $<100 \times 10^9/L$ without any other etiology or disorders that may be associated with thrombocytopenia. The treatment of newly diagnosed ITP patients is steroids. However, about one-third of patients do not respond to steroids. Here, we present a 63-year-old hypothyroid, hypertensive, and diabetic female presented with a history of bruising of skin in multiple sites.

Keywords: Primary ITP; Immune thrombocytopenia; Immune thrombocytopenic purpura; TPO-RA; Eltrombopag

*Corresponding author:

Muhammed Jasim Abdul Jalal

✉ jasimabduljalal@yahoo.com

Department of Internal Medicine and Rheumatology, VPS Lakeshore Hospital, Nettoor, P.O., Maradu, NH 47– By-Pass, Kochi-682040, Kerala, India.

Tel: 9544020621

Received: January 02, 2021; **Accepted:** April 23, 2021; **Published:** April 28, 2021

Introduction

Immune Thrombocytopenic Purpura (ITP) is an autoimmune disorder with isolated thrombocytopenia marked by peripheral blood platelet count $<100 \times 10^9/L$ without any other etiology or disorders that may be associated with thrombocytopenia. The treatment of newly diagnosed ITP patients is steroids. However, about one-third of patients do not respond to steroids. In such cases, intravenous immunoglobulin or splenectomy is indicated. Apart from the evidence of platelet destruction in ITP, certain studies have shown decreased platelet production along with destruction. Eltrombopag is an oral Thrombopoietin Receptor Agonist (TPO-RA). Eltrombopag has been shown to provide a good response in chronic ITP patients not responding to steroid therapy.

Case Report

A 63-year-old hypothyroid, hypertensive, and diabetic female presented with a history of bruising of skin in multiple sites. She denied any history of hematuria, melena, epistaxis, and bleeding gums. There was no history of fever, weight loss, and trauma. General examination showed multiple echymotic patches over the trunk and extremities. System examinations were within the normal limits and did not show any hepatosplenomegaly and generalized lymph node enlargement.

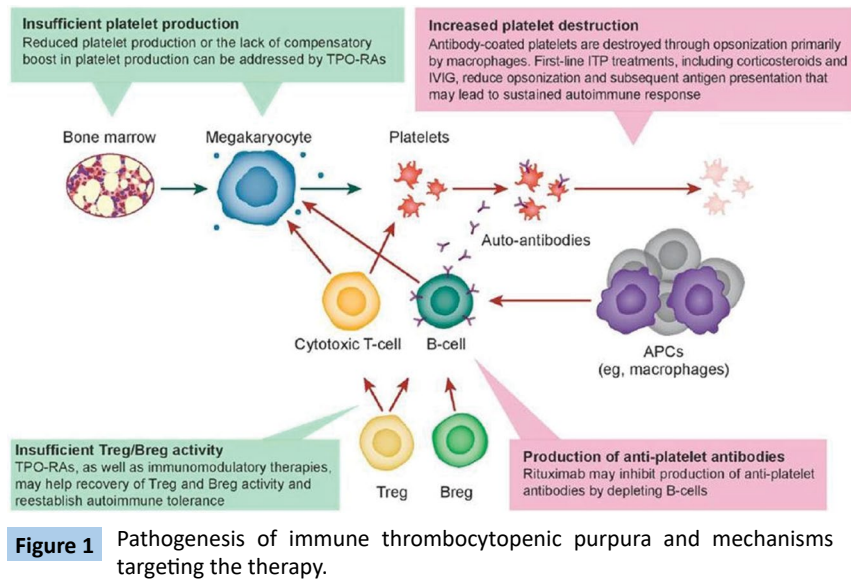
Investigations revealed a low platelet count of $8 \times 10^9/L$ [Normal

range $150 \times 10^9/L - 450 \times 10^9/L$] with normal white cell count and haemoglobin. Liver functions, renal functions, and coagulation profile were normal. Thus we excluded the possibilities of leukemia, aplastic anaemia, systemic lupus erythematosus, and sepsis.

Isolated thrombocytopenia suggested the possibility of immune thrombocytopenic purpura. This was confirmed by bone marrow biopsy, which demonstrated normal megakaryocytes, whereas peripheral blood smear showed decreased platelet count which was typical of ITP.

The patient was treated with platelet transfusion, intravenous, and oral steroids to prevent dreaded complications like intracranial haemorrhage. A transient increase in platelet count was noticed but failed to maintain the optimum platelet count. Immunotherapy was initiated with azathioprine along with steroids. But the platelet count remained sub-optimal and the patient developed cutaneous symptoms.

Our patient did not respond to corticosteroids and



immunosuppression. So we considered TPO-RA (Eltrombopag). It resulted in a drastic increase in platelet count and the patient was free of symptoms. Hence, Eltrombopag was continued and platelet count elevated up to $300 \times 10^9/L$. She is on our follow-up for 1 year without worsening of symptoms.

Discussion

Immune Thrombocytopenic Purpura (ITP) is a diagnosis of exclusion. There are no specific clinical markers or laboratory investigations to establish the diagnosis of ITP with accuracy. Clinically, ITP has an increased risk of bleeding. If ITP is diagnosed within 3 months of its presentation, then it is said to be “newly diagnosed” [1]. Chronic ITP is diagnosed if symptoms last for more than 12 months [2].

Eltrombopag is an oral Thrombopoietin Receptor Agonist (TPO-RA) and has been shown to provide a good response in chronic ITP patients not responding to steroid therapy as it increases the platelet counts significantly in patients with chronic ITP and reduces the morbidity and mortality associated with the ITP [3,4].

The pathogenesis of Immune thrombocytopenic purpura includes [5]:

1. Increased platelet destruction.
2. Insufficient platelet production.
3. Insufficient regulatory T-cells/B-cells activity.
4. Production of anti-platelet antibodies

Corticosteroids and intravenous immunoglobulin targets increased platelet destruction. They reduce the capacity of the immune system to remove antibody-coated platelets.

Thrombopoietin Receptor Agonist [TPO-RA] addresses reduced platelet production or the lack of a compensatory boost in platelet production. They help in the recovery of regulatory T-cells/B-cells activity and re-establish autoimmune tolerance. Rituximab [Anti-

CD 20 antibody] acts by inhibiting the production of anti-platelet antibodies by depleting B-cells.

The only therapeutic option in the management of ITP which focuses on increased platelet production is TPO-RAs (**Figure 1**) [6]. Apart from promoting existing megakaryocytes to produce more platelets, they also enhance the proliferation of megakaryocytes in bonemarrow [7,8]. TPO-RAs reduce platelet destruction by restoring regulatory T-cells and B-cells activity, thereby attenuating the autoimmune response to platelets [9]. It also progressively decreases the auto-antibody levels in patients with ITP, thus contributing to the restoration of immune tolerance to platelets [10].

TPO-RAs, specifically eltrombopag acts as follows:

- A. When added to standard first-line therapy (Corticosteroids/ IVIG) in newly diagnosed ITP patients
 1. Increases the durability of response
 2. Decreases the relapse rate
 3. Reduces the need for additional courses of steroid or IVIG
- B. When given for a short course during the early phase of ITP
 1. Increases the regulatory T-cell activity
 2. Alter the natural course of the disease without the need for continued administration.
- C. In combination with immune modulation is effective in patient's refractory to single-agent ITP medications [9].

ITP in our patient was refractory to first-line management. Hence, we considered a second-line treatment strategy. Our patient could not afford IVIG/Rituximab due to financial constraints. Our only option left was splenectomy. Considering the age of the patient, co-morbidities, increased chance of surgical morbidity, infections,

and cardiovascular risk, our plan was to proceed with splenectomy after a trial of a thrombopoietin receptor agonist, eltrombopag. For adult patients with ITP, the recommended starting dose for eltrombopag is 50 mg/day, which can be increased to 75 mg/day if a sufficient platelet count is not reached [11]. Eltrombopag increased the platelet count in our patient and she was free of symptoms.

Conclusions

From the above experience, we infer that eltrombopag:

1. Is an affordable, oral mono-therapeutic agent of ITP with a good safety profile and fewer complications?

References

- 1 Tripathi A, Shukla A, Mishra S, Yadav Y, Yadav D (2014) Eltrombopag therapy in newly diagnosed steroid non-responsive ITP patients. *Int J Hematol* 99: 413-417.
- 2 Tripathi A, Mishra S, Kumar A, Yadav D, Shukla A, et al. (2013) Megakaryocyte morphology and its impact in predicting response to steroid in immune thrombocytopenia. *Platelets* 25: 526-531.
- 3 Saleh MN, Bussel JB, Cheng G (2013) EXTEND Study Group: Safety and efficacy of eltrombopag for treatment of chronic immune thrombocytopenia: Results of the long-term, open-label EXTEND study. *Blood* 121: 537-545.
- 4 Bussel JB, Cheng G, Saleh MN (2007) Eltrombopag for the treatment of chronic idiopathic thrombocytopenic purpura. *N Engl J Med* 357: 2237-2247.
- 5 Gómez-Almaguer D (2018) Eltrombopag-based combination treatment for immune thrombocytopenia. *Ther Adv Hematol* 9: 309-317.
- 6 Raj AB (2017) Immune Thrombocytopenia: pathogenesis and treatment approaches. *J Hematol Transfus* 5: 1056.
- 7 Di Buduo CA, Currao M, Pecci A (2016) Revealing eltrombopag's promotion of human megakaryopoiesis through AKT/ERK-dependent pathway activation. *Haematologica* 101: 1479-1488.
- 8 Townsley DM, Scheinberg P, Winkler T (2017) Eltrombopag added to standard immunosuppression for aplastic anemia. *N Engl J Med* 376: 1540-1550.
- 9 Zufferey A, Kapur R, Semple JW (2017) Pathogenesis and Therapeutic Mechanisms in Immune Thrombocytopenia (ITP). *J Clin Med* 6: 16.
- 10 Ghadaki B, Nazi I, Kelton JG (2013) Sustained remissions of immune thrombocytopenia associated with the use of thrombopoietin receptor agonists. *Transfusion (Paris)*. 53: 2807-2812.
- 11 Wong RSM, Saleh MN, Khelif A (2017) Safety and efficacy of long-term treatment of chronic/persistent ITP with eltrombopag: Final results of the EXTEND study [published correction appears in *Blood*. *Blood* 130: 2527-2536.