

DOI: 10.36648/1791-809X.16.S6.926

## Gianotti Crosti Syndrome and Its Relationship with Acral Rash- Pediatric Approach

### Abstract

The Gianotti-Crosti syndrome, also known as popular acrodermatitis of childhood, is a secondary to, especially viral or after immunization of the host immune response against infections frequently little dermatosis. Usually appear in the Pediatric population because these patients usually are brought to your paediatrician is critical knowledge of the characteristics of this syndrome and the close relationship it has with the acral rash, to the point where authors have proposed to use the term Gianotti-Crosti, regardless of their cause and presentation to describe all eruptive dermatosis location of acral syndrome. However, it is essential recognition of both concepts individually, their differences and similarities to perform a correct diagnosis and appropriate treatment applied as appropriate.

**Keywords:** Acropapulosis syndrome; Gianotti Crosti; Rash; Pediatrics; Dermatitis

**Received:** 11-Mar-2022, Manuscript No. Iphsj-22-12661; **Editor assigned:** 13-Mar-2022, Preq No. Iphsj-22-12661(PQ); **Reviewed:** 27-Mar-2022, QC No. Iphsj-22-12660 **Revised:** 01-Apr-2022, Manuscript No. Iphsj-22-12661(R); **Published:** 09-Apr-2022, DOI: 10.36648/1791-809X.16.S6.926

### Introduction

The Gianotti-Crosti syndrome (Sx GC), also known as acropapulosis childhood or acrodermatitis child popular, is a rare and self-limited dermatosis presence of monomorphic skin lesions affecting children regardless of sex, from the six months to 12 years of age, although some authors propose intervals ranging from 3 months to 15 years old, but after studies confirm a global and significantly higher incidence between the first and sixth year of life, on the contrary, its appearance in adults is much more rare, with few cases reported in the literature. [1, 2]. Such pathology was first described by Fernando Gianotti and Agostino Crosti in Milan, Italy, in 1955, however, from that time until today, and with all the advances in the field of medicine pathogenesis remains unknown, although it has related to viral and bacterial infections, as well as immunization, in fact, initially the disease described as secondary to infection by hepatitis B; However, in recent years, other viral and bacterial agents and vaccine antigens, have been associated with this dermatosis as shown in Table 1 [3]. Actualmente, numerous studies confirm that VEB is the most common cause SGC, is therefore the most common cause of this dermatosis is considered viral additionally other viruses have been associated with the SGC, including hepatitis A, cytomegalovirus, herpes virus 6, coxsackie, rotavirus, parvovirus B19, molluscum contagiosum, HIV, respiratory syncytial virus, mumps virus and Para influenza virus 1 and 2. Bacteria as Bartonella henselae, Mycoplasma pneumonia, Streptococcus  $\beta$  haemolytic and Borrelia burgdorferi, have also been reported as potential causative agents in spite that there are few reported

**Laura Camila Garcia Medina\*<sup>1</sup>, Yensi Lorena Romero Diaz<sup>2</sup>, Zaira Maria Sanchez Silvera<sup>3</sup>, Yalisa Consuegra Montes<sup>4</sup>, Jonathan Andrés Gómez Patiño<sup>5</sup>, Marly Andrea Riobó Galvis<sup>6</sup>, Freddy Fernando Fonseca López<sup>7</sup>, Catherine Rosero Morales<sup>8</sup>, Laura Andrea Martinez Puello<sup>9</sup>**

- 1 General Physician, Universidad de los Andes, Bogotá, Colombia
- 2 General Physician, Fundación Universitaria Sanitas, Bogotá, Colombia
- 3 General Physician, Universidad Simón Bolívar, Barranquilla, Colombia
- 4 General Physician, Universidad del Norte, Barranquilla, Colombia
- 5 General Physician, Universidad Cooperativa de, Medellín, Colombia
- 6 General Physician, Fundación Universitaria Sanitas, Bogotá, Colombia
- 7 General Physician, Universidad Militar Nueva Granada, Bogotá, Colombia
- 8 General Physician, Universidad de Ciencias Aplicadas y Ambientales, Bogotá, Colombia
- 9 General Physician, Universidad del Sinú, Cartagena, Colombia

#### \*Corresponding author:

Laura Camila Garcia Medina

✉ lc.garcia148@uniandes.edu.co

General Physician, Universidad de los Andes, Bogotá, Colombia

**Citation:** Garcia Medina LC, Romero Diaz YL, Sanchez Silvera ZM, Montes YC, Gómez Patiño J, et al. (2022) Gianotti Crosti Syndrome and Its Relationship with Acral Rash- Pediatric Approach. Health Sci J. Vol. 16 No. S6: 926.

cases. In addition, also it described later SGC immunization with vaccines diphtheria, polio enter virus, tetanus, pertussis, hepatitis A and B, and anti-viral association measles, mumps and rubella, included in MMR [4, 5] (Table 1).

Like the pathogenesis, which is not completely precise, the pathophysiology of the syndrome, the incidence and prevalence are unknown even knowing that it has a worldwide distribution, however, there is underreporting, which makes it difficult to estimate its real prevalence and incidence. Although it is known that it is pathology without predilection for ethnicity or gender. However, given that patients can be diagnosed with a nonspecific viral exanthema, it is probably underdiagnosed. In fact, it is well known that this syndrome is somewhat difficult to diagnose due to poor knowledge. For this reason, authors have proposed criteria such as those observed in Table 2 and knowing that these patients are usually taken to their paediatrician, it is important that the clinician knows the fundamental characteristics of the syndrome; therefore, the clinical picture presents characteristics that are undoubtedly very valuable when giving the diagnosis. diagnosis, among these characteristics are low fever, asymptomatic and self-limited papulo-vesicular reaction with a symmetrical distribution on the face, more specifically on the cheeks, buttocks and extensor surfaces of the extremities as

seen in Figure 1, forming plaques or remaining isolated, it rarely involves the palms, soles, flexor areas, and mucosa. The trunk is generally spared and the lesions are usually not pruritic [5-7] (Table 2).

According to the literature, these lesions are pink or brown in color, where edematous pustular lesions or the previously mentioned papulovesicular lesions are usually interspersed, which generally measure from 1 to 10 mm in diameter, although other authors propose ranges that go from 1 to 5 mm and that, in addition, they can stay for at least ten days with the possibility of presenting the positive Koebner phenomenon that consists of the early stage of the disease, where patients can present a transient rash on the back, chest or abdomen and desquamation [8,9]. Currently, CGS has been considered a delayed hypersensitivity reaction against certain antigens, especially those caused by certain viral infections such as those mentioned above [10, 11]. (Figure 1).

Table 1. Aetiological infectious agents of infantile papular acrodermatitis.

Virus	Bacterium
Epstein-Barr virus	Bartonella henselae
Hepatitis A, B and C viruses	Estreptococo β-hemolítico
Cytomegalovirus	Borrelia burgdorferi
Herpes virus 6	Mycoplasma pneumoniae
Coxsackie A16, B4 and B5	-
Rotavirus	-
Parvovirus B19	-
Molluscum contagiosum	-
Respiratory syncytial virus	-
Echo virus	-
Para influenza	-
HIV	-

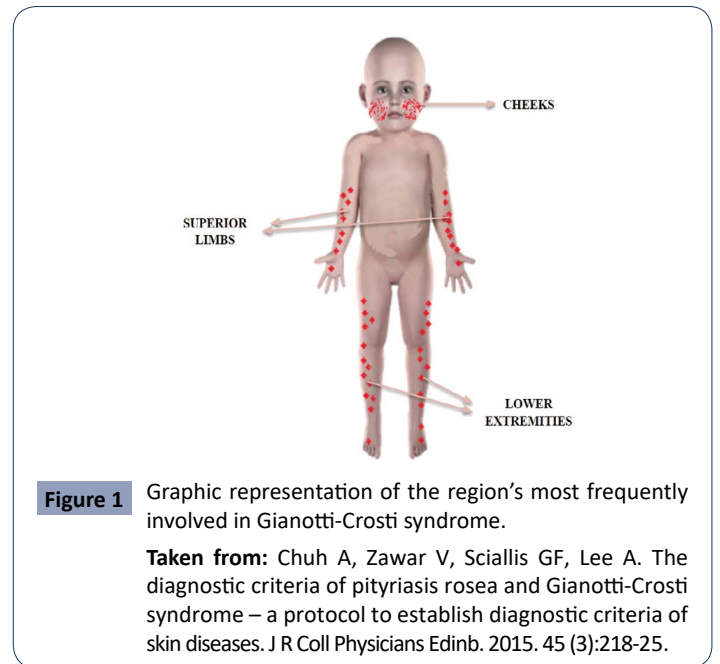


Figure 1 Graphic representation of the region's most frequently involved in Gianotti-Crosti syndrome.

Taken from: Chuh A, Zawar V, Sciallis GF, Lee A. The diagnostic criteria of pityriasis rosea and Gianotti-Crosti syndrome – a protocol to establish diagnostic criteria of skin diseases. J R Coll Physicians Edinb. 2015. 45 (3):218-25.

Table 2. Diagnostic criteria for Gianotti-Crosti syndrome or papular acrodermatitis of infancy, modified translation of Chuh A.

Inclusión signs for diagnosis		Clinical signs of exclusion of the diagnosis	
A- Of the rash	B- From the skin biopsy (if it has been performed)	A- Of the elementary lesions of the rash and its extensión	B- Medical criteria or clinical judgment
1. It should consist of monomorphic, brownish-pink papules or papulovesicles, with a flat surface, with a diameter of one to 10mm.	1. Must offer compatible histopathology	1. They should not be flaky	1. You should not consider any of the differential diagnoses of CGS as more likely.
2. It must affect at least three of the locations: cheeks, buttocks, dorsal aspect of the forearm, anterior aspect of the legs	-	2. They should not cover large areas of the trunk.	-
3. It must be symmetrical and have evolved in the 10 days	-	-	-
Diagnostic criteria for CGS			
I	The patient, on at least one occasion, must meet all the clinical signs of inclusion, defined by a doctor.		
II	The histopathology, if a biopsy has been performed, must be compatible with SGC.		
III	The patient should never develop any of the exclusion signs, defined by a doctor		
IV	Medical criteria should not consider any of the GCS differential diagnoses as more likely.		

**Table 3.** Comparative table of Gianotti syndrome and acral rash.

Characteristic	Gianotti Crosti syndrome	Acral rash
Colour	Pink or Brown	Red or pinkish
	They are mainly papulo-vesicular or edematous pustular	Wide range (erythematous or purpuric, macular, papular, vesicular and pustular and so on)
Injury		
Self-limitation	Yes	Yes
	On the cheeks, buttocks, and extensor surfaces of the extremities, it is rarely observed on the trunk, palms, soles, flexor areas, and mucous membranes.	limbs, may occupy palms and soles of the feet
Location		
Fever	Yes (Low)	Yes
Size	Generally 1 to 10 millimeters in diameter	It depends on the type of injury
Frequency	Higher in children (from one to 6 years)	Higher in children (Less than 1 year of age)
Cause	Infection, often of viral origin (Epstein Barr virus)	Infections or atopic dermatitis
Pathophysiology	Not known	Variable
Duration	3-5 weeks	It depends on the type of injury

However it is necessary to recognize the relationship between this Gianotti Crosti syndrome and acral exanthema, the latter being known as an acute and extensive rash of the skin, usually with spontaneous cutaneous resolution, of a pinkish color that generally appears as a consequence of some Infectious diseases, which may be accompanied by fever and dermatological manifestations located in peripheral areas, are known by the term "acral". As can be analysed, both the syndrome in question and the acral exanthema have certain similarities, as can be seen in Table 2, such as, for example, the fact that they appear after infections that may well be viral or bacterial, as well as the possibility of appearing after immunizations, to manifest fever and pinkish or reddish skin lesions located on the extremities [12]. In fact, it has been proposed to use the term Gianotti-Crostit syndrome, regardless of its cause and form of presentation to describe all eruptive dermatoses of acral location [13]. However, it must be recognized that, although they are very similar and easily confused, Gianotti syndrome does not encompass all types of lesions as well as acral rashes if they involve a wide range of macular, papular, purulent, vesiculopapular, erythematous lesions, etc. , therefore, this is a point to take into account for the differential diagnosis, in addition to considering the negative clinical aspects of SGC that help the diagnosis, such as the absence of lesions on the trunk and the presentation of scaly lesions, additionally, The presentation of a febrile episode of low intensity, some 7-10 days before, accompanied by catarrhal manifestations of the upper respiratory tract cannot be ignored [14,15] (Table 3).

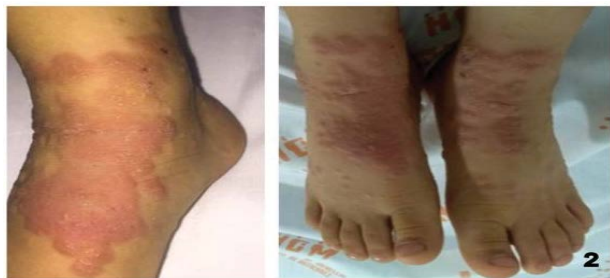## Materials and Methods

A detailed bibliographic search of the most relevant published information is carried out in the databases PubMed, scielo, Medline, national and international libraries specialized in the topics covered in this review article. The following descriptors were used: Acropapulosis, Syndrome, Gianotti Crosti, Rash, Pediatrics, Dermatoses. The data obtained range between 5 and 30 records after the use of the different keywords. The search for articles was conducted in Spanish and English, limited by year of publication, and studies published from 2011 to the present

were used.

## Results

Gianotti-Crostit syndrome (GCS) is primarily a disease of early childhood; it is most common in children between 1 and 6 years of age. Characterized by an acute onset of a papular or papulovesicular rash with a symmetrical distribution, found predominantly on the cheeks, extensor surfaces of the extremities, and buttocks, sparing the antecubital and popliteal fossae, as well as the palms, plants and mucosal surfaces. With the advent of more universal vaccination against hepatitis B virus, the Epstein-Barr virus has become the most common etiologic agent of Gianotti-Crostit syndrome [15]. The pathophysiology is unknown. A delayed hypersensitivity reaction of the dermis to various pathogens and possibly to vaccines is assumed. The most likely process is a type IV local hypersensitivity reaction to the causative antigen. However, immunohistochemistry and electron microscopy findings are nonspecific and do not demonstrate the presence of viral particles or antigens in skin lesions, suggesting that lesion development does not involve a direct local interaction between viral antigens and immune cells. of the skin There may be prodromes such as pharyngitis, upper respiratory tract infection and diarrhoea. Lymphadenopathy is observed in 25-35% of cases [16, 17]. This is observed in the presentation of a case of a 22-month-old male patient who, on dermatological examination, observed blisters and vesicles of different sizes, isolated and grouped, located mainly on the face and upper and lower limbs, with some on the trunk. With positive serological tests for Epstein-Barr virus [18]. Likewise, the literature reports a case of a child diagnosed with this syndrome after vaccination against diphtheria, tetanus and pertussis and the live varicella virus vaccine [19]. GCS is diagnosed clinically by the presence of a characteristic rash and its distribution, with differential diagnoses including erythema multiform, lichen planus, papular urticaria, scabies, and atopic dermatitis, as in the case of Llanora et al. from a four-year-old boy presenting with characteristic reddish-brown, partially flat-topped papules on the extensor surface of the lower limbs [17]. Situation similar to the report by Escobar et al. from a four-year-old male patient with multiple papulovesicular lesions,



**Figure 2** Erythematous plaques with irregular, well-defined borders with some vesicles and scaling on their surface distributed symmetrically on the dorsum of the feet.

Taken from Escobar, A. M., et al. "Síndrome de GianottiCrosti: diagnóstico a considerar en pacientes pediátricos con exantemas acrales." *Revista argentina de dermatología* 102.1 (2021): 21-30.

some of which were normal skin color and others erythematous, monomorphic, 3-5 mm in diameter, firm, grouped, forming well-defined plaques with irregular edges, symmetrically distributed in the distal region upper and lower extremities, especially on the extensor surface of the hands (**Figure 2**) [20].

The classic presentation is that of a symmetric exanthema with an acral distribution, which, as it is a nonspecific viral exanthema, is usually underdiagnosed. Gianotti considered that these patients presented clinically different from infantile acrodermatitis pustular, and described acrolocalized papulovesicular syndromes (21). Recent studies have reported viral rashes with a possible association with COVID-19 in Pediatric patients. They described a 10-month-old boy with Gianotti-Crosti syndrome in the setting of a recent positive RT-PCR test for SARS-CoV-2 to add to the collection of cutaneous manifestations of COVID-19. In particular, chilblains on acral surfaces are thought to occur frequently in children and young adults with COVID-19 (22). Once again, a case report confirms the symmetrical acral appearance that characterizes GCS, therefore, it remains a clinical diagnosis of exclusion. The diagnosis is often made after the child has not been successfully treated for a more common cause of acral rash (eg, scabies), as there are no pathognomonic laboratory or histopathology findings [23].

## Discussion

Gianotti-Crosti syndrome is a benign rash that presents in childhood and rarely in adulthood; is it associated with

multiple viral, bacterial and vaccine diseases. It manifests as a papular eruption of acral distribution with associated systemic symptoms. Our results are similar to those of Neves et al, with respect to the age range in which it appears and the location of the lesions. The presentation of his case of a 2-year-old boy who, on physical examination, showed a papulovesicular exanthema predominantly on the extremities, legs and feet, buttocks and face; some crusty lesions on palms and soles [24]. Likewise, other authors guarantee that the vaccines are the main triggers of this condition, as in the case of a 6-year-old boy who, after receiving the second doses against measles-rubella with live attenuated viruses, started a skin rash, where skin-colored to erythematous, flat-topped papules <1.0 cm in diameter were seen symmetrically distributed on the extremities. Above the knees, several lesions had fused into plaques. In addition to these papular lesions, typical target lesions, comprising central discs of erythema, raised edematous intermediate rings, and red outer rings, <2 cm in diameter, were symmetrically scattered over the dorsal aspect of the ankles and feet [25]. The case Ion et al. agree with our results that a broad group of viruses can be associated with this syndrome, as in the case of a 3-year-old, 8-month-old girl with a generalized maculoerythematous rash associated with positive serologies for Epstein Barr, Echovirus, and Coxsackie viruses that raise suspicion of Gianotti-Crosti syndrome [26]. Although most cases occur in the Pediatric population, the literature also reports a case of an adolescent, which is important for the clinician not to rule out the possibility that the adult population is also affected while The distribution of lesions may vary, as in the case of an 18-year-old female patient who presented with acute skin lesions on the upper extremities, which later spread to the face, neck, torso, abdomen, and lower extremities, and on examination dermatology showed multiple normochromic and monomorphic papules, some of which formed crusts, distributed symmetrically [27]. This syndrome, in addition to its high link with parvovirus [28]. Is also associated with other entities such as atopic dermatitis and molluscum contagiosum [29].

## Conclusion

Gianotti Crosti Syndrome is closely related to acral rash. This syndrome is characterized by an acral papular eruption with a symmetric distribution. It is a benign and self-limited disease present mainly in the Pediatric population due to infections and vaccinations. However, it is important that the clinician has knowledge of the characteristics of the lesions for their correct evaluation and management.

## References

- López-Cepeda, Larissa Dorina (2020) Síndrome de Gianotti-Crosti o acrodermatitis papular de la infancia. *Rev Cent Dermatol Pascua* 29: 20-25.
- Chuh A, Zavar V, Sciallis GF, Lee A (2015) Los criterios de diagnóstico

de la pitiriasis rosada y el síndrome de Gianotti - Crosti: un protocolo para establecer los criterios de diagnóstico de las enfermedades de la piel. *JR Coll Médicos Edinb* 45: 218-225.

- Di Lernia V, Mansouri Y (2013) Epstein-Barr virus and skin manifestations in childhood. *Int J Dermatol* 52:1177-84.

- 4 Niklitschek S, Romero W, Zegpi MS (2011) Síndrome de Gianotti-Crosti: reporte de dos casos y revisión de la literatura. *Rev Ped Elec* 8.
- 5 Admani S, Jinna S, Friedlander SF, Sloan B (2015) Cutaneous infectious diseases: Kids are not just little people. *ClinDermatol*. 1 de noviembre de 33:657-71.
- 6 Aznar SL, Cemeli Cano M, Amiguet Biain MR (2019) Acrodermatitis papulosa infantil tras infección por virus de Epstein-Barr. *Rev Pediatr Aten Primaria* 21:81.
- 7 Silva JC, Torres MC (2014) Diagnóstico diferencial de los exantemas. *Pediatría Integral* 18:22-36.
- 8 Wells L, Mahil S (2018) Rash on extensor surfaces of a child. *BMJ* 360:5547.
- 9 Knöpfel N, Noguera-Morel L, Latour I, Torrelo A (2019) Viral exanthems in children: A great imitator. *Clin Dermatol* 37:213-26.
- 10 Hall LD, Eminger LA, Hesterman KS, Heymann WR (2015) Epstein-Barr virus: dermatologic associations and implications: part I. Mucocutaneous manifestations of Epstein-Barr virus and nonmalignant disorders. *J Am Acad Dermatol* enero de 72:1-19.
- 11 Caccavale S, Ruocco E (2017) Acral manifestations of systemic diseases: Drug-induced and infectious diseases. *ClinDermatol* 35:55-63.
- 12 Coronel-Carvajal, Carlos (2021) Síndrome de Gianotti-Crosti o acrodermatitis papular de la infancia: presentación de un caso. *Archivo Médico Camagüey* 25:471-478.
- 13 Escalante-Jibaja, Emma y col (2018) Exantemas virales. *dermatología peruana* 28:167-184.
- 14 Someshwar S, Jerajani HA (2014) case of Gianotti-Crosti syndrome. *Muller J Med Sci Res*.
- 15 Leung AKC, Sergi CM, Lam JM, Leong K F (2019) Gianotti-Crosti syndrome (papular acrodermatitis of childhood) in the era of a viral recrudescence and vaccine opposition. *World J Pediatr* 15:521-527.
- 16 Leal SBC, Balconi SN, Cafrune FE (2021) Gianotti-Crosti syndrome and yellow fever vaccine: unprecedented reaction *Int J Dermatol* 60:e227-e228.
- 17 Llanora, Genevieve Villablanca, Clifton Ming Tay, and Hugo PS van Beve (2012) Gianotti-Crosti syndrome: case report of a pruritic acral exanthema in a child. *Asia Pacific Allergy* 2:223-226.
- 18 Marcassi AP, Piazza CAD, Seize MBMP, Cestari SDCP (2018) Atypical Gianotti-Crosti syndrome. *An Bras Dermatol* 93:265-267
- 19 Retrouvey M, Koch LH, Williams JV (2013) Gianotti-Crosti syndrome following childhood vaccinations. *Pediatr Dermatol* 30:137-8.
- 20 Escobar AM (2021) Síndrome de GianottiCrosti: diagnóstico a considerar en pacientes pediátricos con exantemas acrales. *Revista argentina de dermatología* 102:21-30.
- 21 Soto, AD Novelo (2017) Gianotti-Crosti Syndrome in Adult Patient Following Enterovirus Infection: Case Report. *Dermatología Cosmética, Médica y Quirúrgica* 15:99-102.
- 22 Swali Ritu N, Erica B Lee, Jennifer L Adams (2021) Gianotti-crosti syndrome in the setting of recent coronavirus disease-19 infection. *Pediatric dermatology* 38:629-631.
- 23 Sears W, Hodge B, Jones B, Thompson M, Vidwan N (2014) Visual diagnosis: 12-month-old boy with persistent rash and lymphadenopathy. *Pediatr Rev* 35:452-455.
- 24 Neves IM, Nogueira MV, Patraquim C, Alves MC (2021) Gianotti-Crosti syndrome: a frequent but underdiagnosed rash. *BMJ Case Rep*14:e244988.
- 25 Oka M (2021) Simultaneous Development of Gianotti-Crosti Syndrome and Erythema Multiforme Following Second Dose of Measles-rubella Vaccine. *Acta Derm Venereol*.
- 26 Ion, Laura-Mihaela (2021) SYND"GIANOTTI-CROSTI ROME." *Romanian J Pediat Rics* 70:156.
- 27 Pedreira RL, Leal JM, Silvestre KJ, Lisboa AP, Gripp AC (2016) Gianotti-Crosti syndrome: a case report of a teenager. *An Bras Dermatol* 91:163-165.
- 28 Chuh A, Zawar V, Lee A, Sciallis G (2016) Is Gianotti-Crosti Syndrome Associated with Atopy? A Case-Control Study and a Postulation on the Intrinsic Host Factors in Gianotti-Crosti Syndrome. *Pediatr Dermatol*. 33:488-92.
- 29 Estébanez A, Silva E, Guillen S, García A, Martín JM (2020) Síndrome de Gianotti-Crosti-like secundario a Molluscum contagiosum [Gianotti-Crosti syndrome-like reaction secondary to Molluscum contagiosum] *An Pediatr* 93:49-50.