



## RESEARCH ARTICLE

## Intravenous administration of metallic mercury with homicidal intent: report of a new interesting case.

Konstantina Fragkou<sup>1</sup>, Christina Marvaki<sup>2</sup>,  
Geraldine Papantoniou<sup>3</sup>, Euphrosyne Zisiou<sup>4</sup>,  
Emmanouel Triantafyllou<sup>5</sup>

1. RN, MSc, Intensive Care Unit, General Hospital of Rhodes "Andreas Papandreou", Greece
2. Professor, Faculty of Nursing, Technological Educational Institute of Athens, Greece
3. Head Nurse, Intensive Care Unit, General Hospital of Rhodes "Andreas Papandreou", Greece
4. General Physician, General Hospital of Kimi "Georgios Papanikolaou", Greece
5. Head Consultant, Intensive Care Unit, General Hospital of Rhodes "Andreas Papandreou", Greece

### Abstract

**Introduction:** Intravenous administration of metallic mercury (Hg) is a rare occurrence that is usually reported in association with suicide attempts, with accidental injection, and with attempt of drug addicts to develop new ways to become intoxicated.

**Aim:** The report of a new rare incident of intravenous administration of metallic Hg that was hospitalised in Intensive Care Unit of a General Greek Hospital.

**Material/Method:** The presentation of a 22 years old female, with no medical history, that was admitted in a Greek hospital after intravenous self-injection of metallic Hg.

**Results:** The patient, primarily occurred tightness in the precordial region, followed by burning pain in the chest, without respiratory distress.

During the first hours of the treatment, the patient was awake and completely oriented to stimuli from the environment (GCS:15). Few hours later, she presented gradually decreased level of consciousness, followed by tremor (GCS:9). The patient started oral chelation therapy with the chelating agent DMSA/succimer 800mg x3. After 2 hours, from the first dose of the chelating agent, the improvement of her consciousness level was remarkable. She was fully awake and had full communication with the environment. Blood and urine mercury levels were toxic. Radiographic examinations revealed multiple, tiny, metallic Hg emboli in patient's functional organs.

**Conclusions:** Owing to the apparent rarity of the phenomenon, the immediate and long term health effects are uncertain and inconclusive. Chelation therapy is considered necessary. Prolonged monitoring of the patient's clinical status is required to prevent early and late reactions of acute or/and chronic Hg intoxication.

**Keywords:** Metallic mercury, intravenous injection, mercury poisoning, clinical manifestations

Corresponding author: Fragkou Konstantina, Larnakas 3A, 85100 Rhodes, Tel: 2241078763, 6932255484, Email: fragkou.kon@gmail.com

### Introduction

In recent years, the risks to humans and the environment from mercury exposure have been recognised. The World Health Organization, The Agency for Toxic Substances and Disease Registry, the United Nations Environment Programme, have determined that mercury and its compounds are considered highly toxic to humans, as high exposure can lead to death.<sup>1,2</sup>

The mercury toxicity to humans, depends on the chemical structure, the amount absorbed, the route of exposure and the general health of the

person exposed.<sup>3</sup>

There are several reports in the literature concerning mercury intoxication and its health effects. In most cases, the reported clinical manifestations of metallic mercury exposure, are described by inhalation of mercury vapors: The most commonly reported respiratory symptoms include cough, dyspnea which can progress to pulmonary edema or fibrosis, and tightness or burning pains in the chest. Gastrointestinal effects observed include, abdominal pains, nausea and/or vomiting, diarrhea and stomatitis. Increases in heart rate and blood pressure have been reported.<sup>4</sup>

A number of studies<sup>5-10</sup> have reported increases in tremors, muscle fasciculations and myoclonus. Renal effects are included, ranging from mild transient proteinuria, to acute renal failure.<sup>11-14</sup> Visual disturbances were also observed.

The most prominent Central nervous system symptoms include tremors (initially affecting the hands and sometimes spreading to other parts of the body), emotional lability, insomnia, memory loss, neuromuscular changes, headaches, polyneuropathy.

However, the human and animal data are generally limited to inhalation exposure of metallic vapors and oral exposure to inorganic and organic mercury compounds. There is limited dermal exposure information on adverse effects from ointments and creams that contain inorganic mercury compounds.<sup>15, 16</sup> Data is extremely limited concerning subcutaneous and intramuscular exposure.<sup>17</sup>

Intravenous administration of metallic Hg is a rare occurrence that is usually reported in association with suicide attempts, with accidental injection, and with the attempts of drug addicts to develop new ways to become intoxicated.

A total of only 78 cases have been reported in the literature over the period 1923-2000.<sup>18</sup>

Whereas in Greece, according to the Poison Information Centre data, no cases were reported till 2012 [Figure1].

Here in, we report a new case report of the intravenous administration of metallic mercury. The patient was hospitalised in the Intensive Care Unit of a General Greek Hospital.

### **Description of the Case**

We present the case of a 22 years old female patient, with no medical history, that was admitted to the hospital after the self injection of intravenous metallic mercury.

The metallic mercury had been taken from three broken thermometers in an attempt at suicide. The information was obtained from the patient.

The patient was brought to the Emergency Room by her relatives two hours after the self injection.

The Physical examination that took place in the Emergency Room, revealed normal consciousness level, with a GCS:15.

Despite complaining of a tightness in the precordial region, followed by burning pain in the chest, without respiratory distress, her vital signs were as follows: Blood pressure of 120/60mmHg, Heart Rate of 90/min, Temperature of 36.6°C and a Respiratory Rate of 17/min.

The electrocardiogram showed normal sinus rhythm, without other pathological findings.

The Chest X-Ray revealed multiple, tiny metallic mercury emboli, more apparent at middle and lower lung fields [Figure 2].

The patient was transported to the Intensive Care Unit for continuing observation and monitoring.

Initial Blood Gases on room air (FiO<sub>2</sub> 21%) were: PaO<sub>2</sub> 104mmHg, PCO<sub>2</sub> 26.5mmHg, pH 7.58, HCO<sub>3</sub> 25.1mmol/L.



From the laboratory tests, no pathological findings were found.

During the first hours following admission, the patient was awake and completely oriented to stimuli from the environment, with a GCS:15. A few hours later, she presented with a gradually decreasing level of consciousness, followed by tremor, with a GCS:9 (Verbal Response= Incomprehensible Speech: 2, Eye Response Opening= to response to pain: 2, Motor Response= Localizing response to pain: 5).

Subsequent vital signs were without significant changes: Blood Pressure of 120/55mmHg, Heart Rate of 90/min, Temperature 37.4 °C and Respiratory Rate 17/min and SpO2 99%.

#### Therapy

A nasogastric tube was inserted and the patient started oral chelation therapy with the chelating agent DMSA – Dimercaptosuccinic acid/ succimer 800mg every 8 hours, as was recommended by the Local Poison Information Centre, based on patient's weight.

Two hours after the first dose of the chelating agent, she showed a marked improvement in her level of consciousness. She was fully awake and oriented to time and place.

Special laboratory evaluation confirmed toxic Blood and urine mercury levels. Her blood mercury concentration was greater than  $>35\mu\text{g/l}$ , when the normal range is below  $<6\mu\text{g/l}$ . Her urine mercury concentration was greater than  $>60\mu\text{g/l}$ , when the normal range is below  $<10\mu\text{g/l}$ . Biochemical parameters of renal function, urea and creatinine, remained normal during her treatment in the ICU. Urea ranged from 15-23mg/dl and creatinine from 0,66- 0,89mg/dl.

Subsequent radiographic examinations: CT scan of the chest, showed significant volumes of radiopaque foreign bodies, (deposits of

mercury), predominately in the lower and posterior lung fields. A small pleural effusion was observed. No intracardiac and pericardial mercury deposits were detectable. An abdomen CT scan demonstrated similar multiple small spherical opacities of metallic density in the liver, in the right kidney, and in the region of the spleen and the paraspinal muscles. Whereas brain CT scan was found to be normal.

Radiological examination of the forearm, revealed small concentrations of metallic mercury at the injection site, but without the presence of localised inflammation [Figure3].

The patient completed the first 7- day cycle of DMSA/ succimer (800mg x3) therapy and was eventually discharged from the ICU in excellent condition.

It was recommended to continue the second 14-day cycle of DMSA/ succimer (800mg x2) on her transfer to the medical ward.

A psychiatric assessment was also recommended and further follow up of blood and urine mercury levels, in order to rule out the possibility of chronic mercury toxicity.

#### **Discussion**

Metallic mercury, when injected intravenously, can cause a variety presentations: from a total lack of symptoms,<sup>19</sup> to respiratory failure, kidney damage, liver damage, neurologic symptoms,<sup>20</sup> and even death. Murray and Hedgepeth<sup>21</sup> and De Palma et al.,<sup>22</sup> reported the death of two patients caused by acute renal and hepatic failure, and Acute Respiratory Distress Syndrome.

Our patient, made a full clinical recovery and did not show any renal, hepatic, or pulmonary sequelae. Our observation is most in concordance with that of Bruce et al.,<sup>20</sup> who described a patient with a gradually decreasing level of consciousness, without any other symptoms of



mercury toxicity. It is important to emphasize, that it is the only case reported with this particular clinical picture.

The most common respiratory manifestations reported, are dyspnea and tightness in the chest,<sup>20,23-25</sup> as was found in our case.

In the present case, as in many others, alterations in liver, kidney and lung function were absent, although considerable amounts of mercury could be detected.

Radiographic examinations of most cases, describe multiple tiny metallic mercury deposits in functional organs,<sup>20,23,26-30</sup> as in our patient.

The usage of chelation agents in the treatment of mercury exposure is recommended. Although, in cases of intravenous exposure, its use is controversial.<sup>25,31</sup> In the present case, the chelation therapy with DMSA/ succimer was considered necessary.

### Conclusions:

Owing to the apparent rarity of the phenomenon, the immediate and long term health effects are uncertain and inconclusive.

Intravenous administration of metallic Hg is considered as an emergency condition that can cause widely varying presentations from a total lack of symptoms to respiratory failure, kidney damage, liver damage, neurological symptoms and even death. Chelation therapy is considered necessary.

Prolonged monitoring of the patient's clinical status is required to prevent early and late reactions of acute or/and chronic Hg intoxication.

### References

1. World Health Organization (WHO). Elemental Mercury and Inorganic Mercury Compounds: Human Health Aspects. 2003
2. Agency for Toxic Substances and Disease Registry (ATSDR). Toxicological Profile for Mercury. U.S.

Department of Health and Human Services. Public Health Service. 1999; 1-43. Available at: <http://www.atsdr.cdc.gov/toxprofiles/tp46.html>. Date of access: 10.07.2012

3. United Nations Environment Programme (UNEP). Global Mercury Assessment. 2002; 27 Available at: <http://www.chem.unep.ch/mercury/default.htm>. Date of access: 24.06.2012
4. Agency for Toxic Substances and Disease Registry (ATSDR). Managing Hazardous Materials Incidents. Mercury (Hg). World Health Organization. 2006; 5-8. Available at: <http://www.atsdr.cdc.gov/mhmi/mmg.46pdf>. Date of access: 17.07.2012
5. Fagala G.E, Wigg C.L. Psychiatric manifestations of mercury poisoning. Journal of the American Academy of Child and Adolescent Psychiatry 1992; 31:306-311.
6. Taueg C, Sanfilippo D, Rowens B. Acute and chronic poisoning from residential exposures to elemental mercury. Journal of Toxicology-Clinical Toxicology 1992; 30:63-67.
7. Ehrenberg R.L., Vogt R.L., Smith, A.B. Effects of elemental mercury exposure at a thermometer plant. American Journal of Industrial Medicine 1991; 19: 495-507.
8. Albers J.W., Kallenbach L.R., Fine L.J., Langolf G.D., Wolfe, R.A., Donofrio P.D., et al. Neurological abnormalities associated with remote occupational elemental mercury exposure. Annals of Neurology 24: 651-659.
9. Mathiesen T, Ellingsen D, Kjuus H. Neuropsychological effects associated with exposure to mercury vapor among former chloralkali workers. Scandinavian Journal of Work, Environment and Health 1999; 5: 342-250.
10. Letz R, Gerr F, Cragle D, Green C, Watkins J, Fidler A. Residual Neurologic Deficits 30 Years after Occupational Exposure to Elemental Mercury, Neurotoxicology 2000; 21: 459-474.
11. Buchet J, Roels H, Bernard A, Lauwerys R. Assessment of renal function of workers exposed to inorganic lead, cadmium, or mercury vapor. Journal of Occupational Medicine 1980; 22:741-750.
12. Langworth S, Almkvist O, Soderman, E, Wikström B. Effects of occupational exposure to mercury vapor on the ventral nervous system. British Journal of Industrial Medicine 1992; 49:545-555.



13. Ellingsen D, Efskind J, Haug E, Thomassen Y, Martinsen I, Gaarder P. Effects of low mercury vapour exposure on the thyroid function in chloralkali workers. *Journal of Applied Toxicology* 2000b;20:483-489.
14. Barregard L, Quelquejeu G, Sallsten G, Haguenoer J, Nisse C. Dose-dependent elimination kinetics for mercury in urine - observations in subjects with brief but high exposure. *International Archives of Occupational and Environmental Health* 68: 345-348.
15. Bourgeois M, Doms-Goossens A, Knockaert D, Sprengers D, Van Boven M, Van Tittelboom T. Mercury intoxication after topical application of a metallic mercury ointment. *Dermatologica* 1986;172:48-51.
16. De Bont B, Lauwerys R, Govaerts H, Moulin D. Yellow mercuric oxide ointment and mercury intoxication. *Eur J Pediatr* 1986;145:217-8.
17. Agency for Toxic Substances and Disease Registry (ATSDR). Toxicological Profile for Mercury. U.S. Department of Health and Human Services. Public Health Service. 1999; 170-171. Available at: <http://www.atsdr.cdc.gov/toxprofiles/tp46.html>. Date of access: 10.07.2012
18. Winker R, Schaffer AW, Konnaris C, Barth A, Giovanoli A, Osterode W, et al. Health consequences of an intravenous injection of metallic mercury. *Int Arch Occup Environ Health* 2002; 75(8):581-6.
19. Chitkara R, Seriff NS, Kinas HY. Intravenous self-administration of metallic mercury in attempted suicide. Report of a case with serial roentgenographic and physiologic studies over an 18-month period. *Chest* 1978; 73(2):234-6.
20. Bruce A, Shaffer M, Wolfgang W. Multiple small opacities of metallic density in the lung. 21. American College of Chest Physicians 1989;96(5):1179-1181.
21. Murray KM, Hedgpeeth JC. Intravenous self-administration of elemental mercury: efficacy of dimercaprol therapy. *Drug Intell Clin Pharm* 1988; 22(12):972-5.
22. De Palma G, Mariotti O, Lonati D, Goldoni M, Catalani S, Mutti A, et al. Toxicokinetics and toxicodynamics of elemental mercury following self-administration. *Clin Toxicol (Phila)* 2008; 46(9):869-76
23. Maniatis V, Zois G, Stringaris K. I.v. Mercury self-injection: CT imaging. *AJR Am J Roentgenol* 1997;169(4):1197-8.
24. Giombetti RJ, Rosen DH, Kuczmierczyk AR, Marsh DO. Repeated suicide attempts by the intravenous injection of elemental mercury. *Int J Psychiatry Med* 1988;18(2):153-67.
25. Wale J, Pankaj K Yadav, Shairy G. Intravenous administration/infusion of metallic mercury. Case report and literature review. *Indian J Radiol Imaging* 2010;(2):147-149.
26. Kedziora A, Duflou J. Attempted suicide by intravenous injection of mercury: a rare cause of cardiac granulomas. A case report. *Am J Forensic Med Pathol* 1995;16(2):172-6
27. McFee RB, Caraccio TR. Intravenous mercury injection and ingestion: clinical manifestations and management. *J Toxicol Clin Toxicol* 2001;39(7):733-8.
28. Kedziora A, Duflou J. Attempted suicide by intravenous injection of mercury: a rare cause of cardiac granulomas. A case report. *Am J Forensic Med Pathol* 1995;16(2):172-6.
29. Dell' Omo M, Muzi G, Bernard A, Filiberto S, Lauwerys RR, Abbritti G. Long-term pulmonary and systemic toxicity following intravenous mercury injection. *Arch Toxicol* 1997; 72(1):59-62.
30. Peterson N, Harvey-Smith W, Rohrmann CA. Radiographic aspects of metallic mercury embolism. *Am J Radiol* 1980; 135:1079-81.
31. Gopalakrishna A, Pavan Kumar T. Intravenous injection of elemental mercury: A report of two cases. *Indian J Plast Surg* 2008;41(2):214-218.

## ANNEX

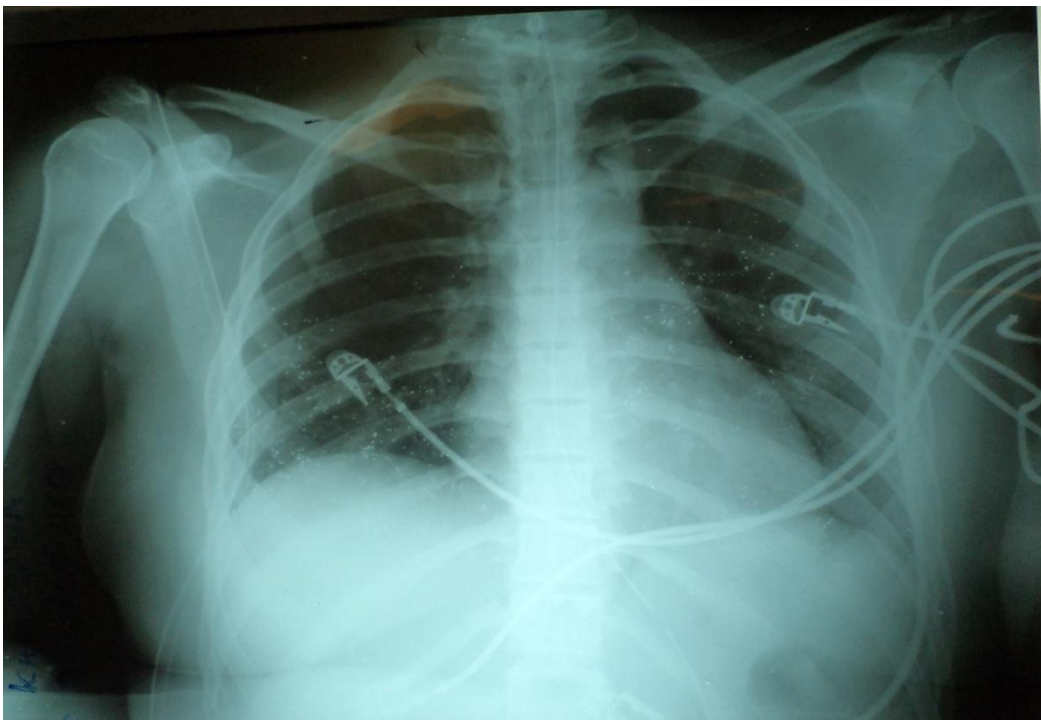
Figure1.

Source: Data base of Poison Information Centre in Greece, 2011

Poison Information Centre				
	Way of exposure	Frequency	Percent	Valid Percent
Valid	Oral	355	66.9	86.8
	Eyes	2	.4	.5
	Inhalation	2	.4	.5
	Dermal	40	7.5	9.8
	Eyes and Dermal	1	.2	.2
	Parenteral	1	.2	.2
	Other ways	5	.9	1.2
	Questions about Poisonings	3	.6	.7
	Total	409	77.0	100.0
Missing	System	122	23.0	
Total		531	100.0	

Figure2.

CXR: Mercuri emboli at lung fields





**Figure 3.**

**Forearm X-Ray: Concentrations of metallic mercury at the injection site**

