

**LIPIDIOZIS IN CAPTIVE REARED BLUEFIN TUNA (*Thunnus thynnus* L.1758) FROM THE WESTERN MEDITERRANEAN REGION IN TURKEY****Öznur Diler<sup>1</sup>, Mehmet Rüstü Özen<sup>1</sup>, Behire Işıl Didinen<sup>1\*</sup>, Nezire Lerzan Çiçek<sup>1</sup>,  
Yasar Özvarol<sup>2</sup>**<sup>1</sup> Süleyman Demirel University, Fisheries Faculty, Eğirdir-Isparta-Turkey<sup>2</sup> University of Mediterranean, Fisheries Faculty, Antalya- Turkey**Abstract:**

In this study was investigated histological alteration associated with frozen baitfish feeding of cage-reared bluefin tuna (*Thunnus thynnus*) in the Gulf of Antalya in Turkey. For this purpose, liver, heart and skeletal muscle samples taken from wild (control) and cage-reared bluefin tuna (70 to 150 kg, n = 25) were examined by histologic methods. As a result of in this study was observed vacuolation of the hepatocytes depending on the lipid accumulation in the liver parenchyma and lipid deposits in the cardiac and skeletal muscle tissues cells in cage-reared bluefin tuna. Thus, negative affects of feeding with wet foods have high content of fat and protein in the health of cage-reared bluefin tuna were determined.

**Keywords:** Bluefin tuna, *Thunnus thynnus*, Frozen baitfish feeds, Lipidiozis, Liver**Özet:****Türkiye’de Batı Akdeniz Bölgesinde Yetiştiriciliği Yapılan Orkinoslar (*Thunnus Thynnus* L.1758)’da Yağlanma**

Bu çalışmada ülkemizde Antalya körfezinde kafeslerde yetiştiriciliği yapılan orkinos balıkları (*Thunnus thynnus*)’nın beslenmesinde dondurulmuş yem balıklarının kullanımının meydana getirdiği histolojik değişimler araştırılmıştır. Bu amaçla, doğadan yakalanmış(kontrol) ve kafeslerde yetiştirilmiş orkinos balıklardan (70-150 kg, n = 25) alınan karaciğer, kalp ve iskelet kası örnekleri histolojik metotlarla incelenmiştir. Çalışmanın sonucunda karaciğer dokusunda lipit birikimine bağlı olarak hepatositlerde vakoulasyon, iskelet ve kalp kası hücrelerinde de lipit birikimi olduğu saptanmıştır. Böylece, kafeslerde yetiştiriciliği esnasında yağ ve protein içeriği yüksek yaş yemlerle beslenen orkinos balıklarının sağlığının olumsuz yönde etkilendiği belirlenmiştir.

**Anahtar Kelimeler:** Orkinos, *Thunnus thynnus*, Dondurulmuş yem balıkları, Yağlanma, Karaciğer

\* Correspondence to:

Behire Işıl DİDİNEN, SDU Eğirdir Su Ürünleri Fakültesi, Isparta-TURKEY

Tel: (+90 246) 313 34 47 Fax: (+90 246) 313 3452

E-mail: [behiredinen@hotmail.com](mailto:behiredinen@hotmail.com)

## Introduction

Bluefin tuna (*Thunnus thynnus*) is a highly migratory species that is targeted for its high commercial value in most of the oceans worldwide, particularly in international waters. Raw tuna, especially the meat from the belly of the fish, is the main ingredient of the Japanese delicacies as sushi and sashimi. The best-quality sushi and sashimi is achieved from fish with high levels of fat accumulated in musculature. Large bluefin tuna (BFT) are fattened in a cage for a relatively short period by feeding with high-fat content food after their capture in the wild. The aim to increase tissue fat content, not to increase fish biomass (Yıldırım, 2004; Yerlikaya *et al.*, 2009).

BFT are presently fattened in cages in the Mediterranean Sea for 8 months (from July to February-March), and achieving higher growth rates than fish in the wild, because of higher water temperature and ad libitum food supply composed (mainly of high lipid content fish and cephalopods (Chase, 2002). Mediterranean countries involved in tuna farming include Spain, Italy, Greece, France, Malta, Cyprus, Croatia, Tunisia, and Libya. In Turkish coastal waters, BFT aquaculture started in 2002. At present, 6 BFT farms are located in Antalya and Izmir. The main aim of BFT fattening in cages is to improve flesh quality and thereby obtain high-value fish products for the Japanese markets (Perçin and Konyalıoğlu, 2008; Yerlikaya *et al.*, 2009).

Despite the expansion of tuna facilities in the Mediterranean regions, only a limited number of studies have examined the health status of caged-reared tuna (Perçin and Konyalıoğlu, 2008; Yerlikaya *et al.*, 2009). Therefore, in the present study were investigated changes in the tissues of BFT fattened in cages for determining the health status associated with diet.

## Materials and Methods

### Rearing conditions

The BFT were caught by purse seine in the fishing area between Cyprus and Antalya and transferred to cages (1000 ind./cage) in the Gulf of Antalya in Turkey (Figure 1). Approximate density of fish in cages was 1000 individuals per cage. Fish were fattened in cages (diameter, 50 m, depth, 30m) in water depths over 40 m from July to November 2007 and were fed a diet consisting of defrosted small pelagic fish (sardine,

herring, ringa, and mackerel) provided twice daily, with squid 6 days per week. Temperature of the water during fattening the tuna in cages was ranged 23.5-29.6 °C.

### Histological examination of tuna samples

Tissue samples of liver, skeletal muscle and heart were taken from wild BFT in may and farmed BFT at harvesting time in october (70 to 150 kg, n = 25) for histopathological examination. Samples were fixed in 10 % buffered formalin, dehydrated in a graded ethanol and embedded in paraffin. Sectioned tissues (5 µm) were stained with hematoxylin-eosin for general observations. In addition, the sample tissues were fixed in liquid nitrogen for 5 min. frozen sections of 5-10 µm were cut in cryostat microtome and stained with Oil-Red O to evaluate lipid content (Bancroft and Stevens, 1977; Roberts, 1978; Caballero *et al.* 1999). All the stained sections were examined and photographed under a light microscope with digital camera.

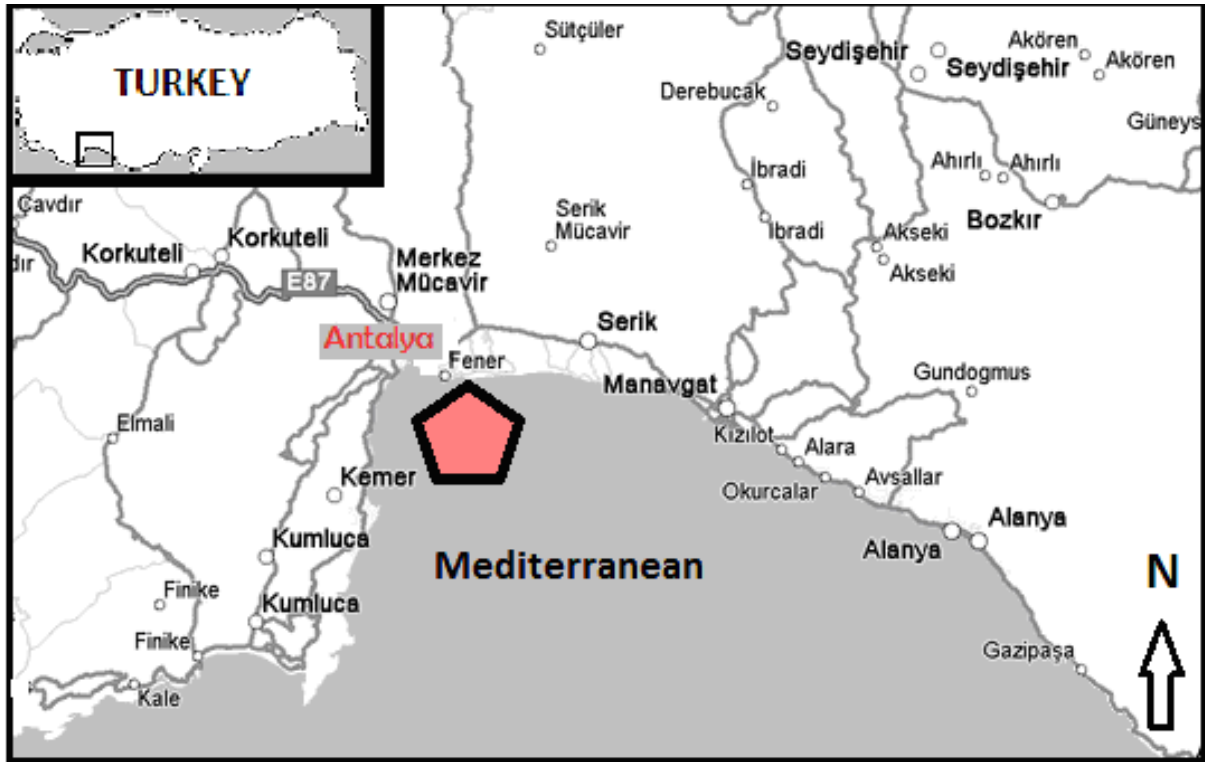
## Results and Discussion

The quality of food is considered an important factor affecting the health status and quality of farmed tuna (Maita, 2007). Different environmental conditions and feeding protocols could also cause variations in fat levels in tuna (Gimenez-Casalduero and Sanchez-Jeres, 2006; Nakamura *et al.*, 2007). Freshness of the baith-fish used for tuna feeding in cages determines the farming success; feeding low-quality fish can cause health problems, increase potential for parasite invasions and loss of growth rate within the farmed population, and eventual mortality (Dos Santos *et al.*, 1993; Mladineo *et al.*, 2006).


In this study was determined vacuolation of the hepatocytes depending on lipid accumulation in the liver parenchyma in the farmed bluefin tuna fed with defrosted small pelagic fish and squid. Hepatocyte nuclei were located at the periphery of cells (Figure 2). Lipid deposits were also found in the cardiac and skeletal muscle cells. However, lipid deposits were determined in a small area of intercellular area in the liver of wild *Thunnus thynnus* in this study (Figure 3). Roberts and Agius (2008) reported that hepatic necrosis and lipidosis observed in BFT fed with African pilchards (*Sardinops sagax*) at the high water temperature (25.5°C) in farmed northern in eastern Adriatic. The most serious cases, result-

ing Ferrante *et al.* (2008) observed higher the lipid content in cage-reared BFT than wild. Yerlikaya *et al.* (2009) investigated changes in the proximate composition of BFT reared in cages in the Gulf of Antalya, Turkey, during the fattening period. They observed that the fat content of BFT


significantly increased from July (3.25%) to October (16.55%). Similarly, Perçin and Konyalıoğlu (2008) determined serum biochemical values finding that cholesterol and triglyceride levels were higher in captive BFT compared to wild fish.



**Figure 1.** Location of tuna fattening cages in the Gulf of Antalya, Turkey



**Figure 2.** Lipid deposits in liver cells and nuclei were propelled to the peripheries of the cell (arrow); Oil-Red O, 10×



**Figure 3.** Lipid deposits (arrows) in intercellular area in liver of wild *Thunnus thynnus* (H+E, X 20)

## Conclusions

As a result of in this study were determined negative affects of feeding with wet foods have high content of fat and protein in the health of cage-reared bluefin tuna.

## Acknowledgments

We wish to thank the Research Grant Council of Suleyman Demirel University for financial support (Project number: SDUBAP 1295-M-06).

## References

- Bancroft, J.D., Stevens A., (1977). Theory and Practice of Histological Techniques. Churchill Livingstone, Medical Div. Longman Group Ltd. Ednburgh, 436 pp.
- Caballero, M.J., Lo'pez-Calero, G., Socorro J., Roo, F.J., Izquierdo, M.S., Fernandez, A.J., (1999). Combined effect of lipid level and fish meal quality on liver histology of gilt-head sea bream (*Sparus aurata*), *Aquaculture*, **179**: 277-290.  
**doi: [10.1016/S0044-8486\(99\)00165-9](https://doi.org/10.1016/S0044-8486(99)00165-9)**
- Dos Santos, J., Burkow, I.C. and Jobling M. 1993. Patterns of growth and lipid deposition in cod (*Gadus morrhua* L.) fed natural prey and fish-based feeds, *Aquaculture*, **110**: 173-189.  
**doi: [10.1016/0044-8486\(93\)90271-Y](https://doi.org/10.1016/0044-8486(93)90271-Y)**
- Ferrante, I., Ricci, R., Aleo, E., Passi, S., Cataudella, S., (2008). Can enzymatic antioxidant deferenes in liver discriminate between wild and sea cage reared Bluefin Tuna quality?. *Aquaculture*, **279**: 182-187.  
**doi: [10.1016/j.aquaculture.2008.03.035](https://doi.org/10.1016/j.aquaculture.2008.03.035)**
- Gimenez-Casalduero, F., Sanchez-Jerez, P., (2006). Fattening rate of bluefin tuna *Thunnus thynnus* in two Mediterranean fish farms, *Cybium*, **30**: 51-56.
- Maita, M., (2007). Fish health assessment. In: H. Nakagava, M. Sato and D.M. Gatlin III, Editors, Dietary supplements for the health and quality of cultured fish, CABI International, Japan: 11-35.  
**doi: [10.1079/9781845931995.0010](https://doi.org/10.1079/9781845931995.0010)**
- Mladineo, I., Miletić, I., Boćina, I., (2006). *Photobacterium damsela* subsp. *piscicida* outbreak in cage-reared Atlantic bluefin tuna (*Thunnus thynnus*), *Journal of Aquatic Animal Health*, **18**: 51-54.  
**doi: [10.1577/H05-012.1](https://doi.org/10.1577/H05-012.1)**
- Nakamura, Y., Ando, M., Seoka, M., Kawasaki, K., Tsukamasa, Y., (2007). Changes of proximate and fatty acid compositions of the dorsal and ventral ordinary muscles of the full-cycle cultured Pacific bluefin tuna *Thunnus orientalis* with the growth, *Food Chemistry*, **103**: 234-241.  
**doi: [10.1016/j.foodchem.2006.07.064](https://doi.org/10.1016/j.foodchem.2006.07.064)**
- Perçin, F., Konyalıoğlu, S., (2008). Serum biochemical profiles of captive and wild northern bluefin tuna (*Thunnus thynnus* L.1758) in the Eastern Mediterranean, *Aquaculture Research*, **39**: 945-953.  
**doi: [10.1111/j.1365-2109.2008.01954.x](https://doi.org/10.1111/j.1365-2109.2008.01954.x)**
- Roberts, R.J., (1978). Fish Pathology. Balliere Tindall, London, 318 pp.
- Roberts, R.J., Agius, C., (2008). Pan-steatitis in farmed northern bluefin tuna, *Thunnus thynnus* (L.), in the eastern Adriatic, *Journal of Fish Diseases*, **31**: 83-88.  
**doi: [10.1111/j.1365-2761.2007.00901.x](https://doi.org/10.1111/j.1365-2761.2007.00901.x)**
- Yerlikaya, P., Gökoğlu, N., Topuz, O., Gökoğlu, M., (2009). Changes in the proximate composition of bluefin tuna (*Thunnus thynnus*) reared in the cages located on the Gulf of Antalya (Turkey's Western Mediterranean coast) during the fattening period, *Aquaculture Research*, **40**: 1731-1734.  
**doi: [10.1111/j.1365-2109.2009.02276.x](https://doi.org/10.1111/j.1365-2109.2009.02276.x)**
- Yıldırım, S., (2004). A study on some area system and activity features of bluefin tuna (*Thunnus thynnus* L.1758) farms in Turkey, *Journal of Fisheries and Aquatic Science*, **21**: 301-3