

## Massive Extramedullary Plasmacytoma of the Skull

**Mohamad Khawandanah MD and Mohamad Cherry MD**

44-year-old female patient presented to our facility with 2 week history of headaches and massive mass located in the right forehead. She was diagnosed with multiple myeloma 5 years prior to presentation in outside hospital where she was initially treated with multiple lines including bortezomib and lenalidomide based multiple regimens in addition to 2 autologous stem cell transplants. Computed tomography (CT) brain scans (**Figure 1**) and Magnetic resonance imaging (MRI) scans (**Figure 2**) were representing extramedullary plasmacytoma. We treated patient with Dexamethasone and radiation therapy. Her mass had significant response to treatment, and later we referred patient to hospice secondary to deterioration in performance status.

Hematology-Oncology Section, Department of Medicine, The University of Oklahoma Health Sciences Center, Oklahoma City, OK, USA

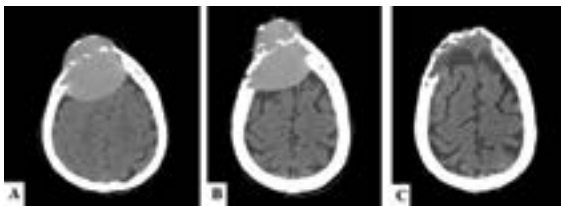
### Corresponding author:

Mohamad Khawandanah MD

Assistant Professor of Medicine, University of Oklahoma Health Sciences Center Stephenson Cancer Center, 800 NE 10th street, Oklahoma City, OK 73102, USA

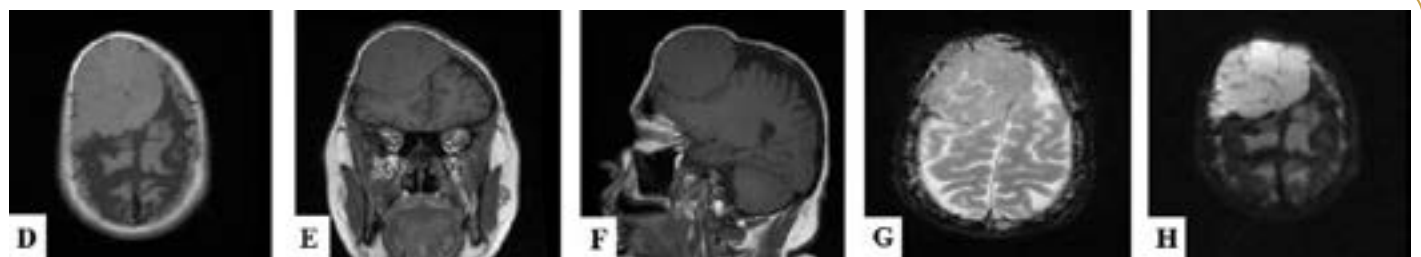✉ Mohamad-khawandanah@ouhsc.edu

Tel: 1405-271-4000



CT of the brain on initial presentation shows a destructive hypoattenuating mass centered within the right anterior calvarium (A and B). CT scan 2 months after treatment shows resolution of mass effect on the brain with decrease in size (C).

**Figure 1** CT studies of the brain.



MRI on initial presentation shows a large right frontal calvarial lesion extends intracranially with mass effect on the underlying right frontal lobe, mid line shift and basilar cistern effacement. (D, E and F: T1 weighted image, F and G: T2 weighted image, H: diffuse weighted image).

**Figure 2** MRI studies of the brain.