

Perforator vascular localization assisted by different methodology in reconstructive surgery

Rizwan Ali*, Jinghong Xu

Department of Plastic surgery, The First Affiliated Hospital, School of Medicine, Zhejiang University, No. 79 Qingchun Road, Hangzhou 310003, China

AUTHORS' CONTRIBUTION: (A) Study Design · (B) Data Collection · (C) Statistical Analysis · (D) Data Interpretation · (E) Manuscript Preparation · (F) Literature Search · (G) No Fund Collection

ABSTRACT

Different methodologies assist perforator's vascular localization in reconstructive surgery. In modern reconstructive microsurgery, perforator flaps have become the pillar of treatment. Their well-described benefits over the conventional free flaps are reduced donor location morbidity, improved flap mobility, and determining, creating reconstructive methods additional ingenious. There are different procedures used for vascular plotting in perforator flaps. In this review, we will debate the pros and cons as well as comparison of numerous vascular plotting techniques used for vascular localization in detail such as Hand-held Doppler Sonography (HHD), CT angiography (CTA), MR angiography (MRA), DS angiography (DSA), CD Sonography (CDS), Infrared thermography (IRT), and Indocyanine green-fluorescence angiography (ICG-FA).

Keywords: Perforator flap; Different methodologies; Pros and cons; Comparison

Address for correspondence:

Dr. Rizwan Ali,
Department of Plastic Surgery,
The First Affiliated Hospital, School of Medicine,
Zhejiang University, No. 79 Qingchun Road,
Hangzhou 310003, China
E-mail: 12018636@zju.edu.cn

Word count: 4403 **Tables:** 00 **Figures:** 01 **References:** 84

Received: 16.06.2023, Manuscript No. ipjbs-23-13842; **Editor assigned:** 19.06.2023, PreQC No. P-13842; **Reviewed:** 03.07.2023, QC No. Q-13842; **Revised:** 10.07.2023, Manuscript No. R-13842; **Published:** 31.07.2023

INTRODUCTION

For preoperative planning in plastic surgery, particularly for perforator flap surgery, preoperative imaging is being used more and more. This strategy came when contemporary reconstructive surgery made a greater attempt to reduce donor site morbidity, which led to the perforator flap's subsequent rise in popularity [1-4] the choice of the perforator artery used to perfuse the flap is a crucial factor in the success of all perforator flaps. The "dominant" perforator, chosen to supply the flap, is selected based on a variety of characteristics, such as size (biggest caliber accessible), venous caliber and/or venous interconnectivity, and anatomic features including subcutaneous, subfascial, and intra-muscular course.

The danger of partial necrosis of the flap is significant in this surgical treatment and is directly connected to perforator choice. According to authors' reports, this risk occurs 30% of the time, particularly among high-risk patients like smokers and obese people [5-7] Thus, it is crucial to employ methods that enable in-depth examination of perforator anatomy. Prior to a few years ago, the evaluation of instruments includes Laser Doppler Flowmetry (LDF), power-Doppler ultrasonography (PDUS), and duplex ultrasound (DUS) [8-12] Preoperative PDUS localization of flap perforators may enhance the surgeon's capacity to elevate the flap and construct it to catch the dominant vasculature and increase survival [10]

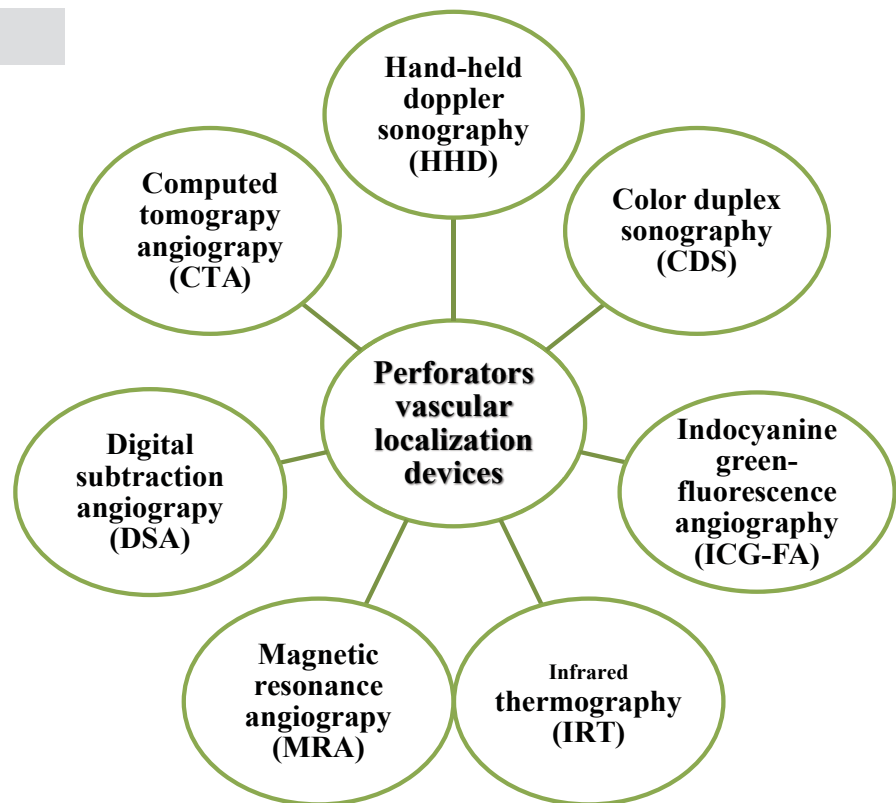
The investigation of vascular structure and perfusion in three dimensions at high resolution is now possible because to new imaging technologies. Recent advances have made magnetic resonance angiography (MRA) and computed tomographic angiography (CTA) two of the best non-invasive methods for studying the vascular system [13] The advantages and disadvantages as well as comparison of a variety of vascular plotting techniques used for vascular localization, including hand-held Doppler Sonography (HHD), CT angiography (CTA), MR angiography (MRA), DS angiography (DSA), CD Sonography (CDS), infrared thermography (IRT), and Indocyanine green-fluorescence angiography (ICG-FA), will be discussed in detail in this review. The following methods are shown in (Fig. 1.)

DISCUSSION

Appraisal of Hand-Held Doppler Sonography (HHD)

Handheld Doppler ultrasound was first applied to free flap microsurgery in 1975 and is a portable, relatively

Fig.1. Names of perforators vascular localization devices.



inexpensive detection technique [14]The appropriate site of perforators in well-muscled helpers operating a hand-held Doppler is analogous to the site of the corresponding perforators found after dissection in new cadavers and established that a close correlation existed was described by Taylor et al [15] Pencil-type Doppler probe records the movement of erythrocytes by referring and identifying reflected ultrasound. Several tests with distinctive frequencies can be utilized which are contingent upon the vessels profundity and width to be researched. The eight and ten MHz are two most generally utilized frequencies, and they have the highest sensitivity of just twenty and fifteen mm, individually. [16] The usage of hand-held Doppler have been accounted to find perforators of the upper limb, lower limb, and trunk.[17-20] A moderately latest domain of reconstructive surgery, where the hand-held Doppler utilized in the pedicle perforator-flaps [21, 22]and freestyle perforator flaps [23-26]

Pros of HHD

HHD’s benefits are inexpensive, tiny size, non-intrusive, convenience, and effortlessness of doing the checkup. Furthermore, there are extraordinary tests accessible that can be sanitized and make the procedure accessible during operation to conclude the preparation and to test the throb of a vessel throughout the surgery [16, 17, 20, 27]

Cons of HHD

The primary drawback of most broadly utilized doppler tests (8 MHz) is that it’s just recognizing vessels to the profundity of twenty mm. it makes the method not much effective for detecting perforator appearance over the fascia, at whatever point the wideness of skin and subcutaneous

tissue surpasses this sum [17] Furthermore, one can never identify for sure which vessel produces the HHD to pick up the Doppler signal. This method also does not generate a three-dimensional picture of the vasculature and its nearby anatomical structure that can later be accumulated and recovered.

Success rate of HHD

In 2006, the research of Yu and Youssef [17] contained one hundred patients experiencing reconstruction of antero-lateral thigh and the sites of hand-held doppler signs of the eight-MHz and ten-MHz test were contrasted to the intraoperation finding. In the result of the perforator, the +VE prescient rate for the eight-MHz test was eighty-nine percent, whereas no false-negative outcome were discovered. A +VE prescient rate of ninety-four percent and -VE prescient rate of forty-three percent was detected in the ten-MHz test. Shaw et al [19] investigation contrasted hand-held doppler with the intraoperative finding of thirty patients experiencing a reconstruction of the anterolateral thigh. For the hand-held doppler finding, they discovered an enormous underestimation of thirty percent to an overestimation of one hundred and fifty percent. An analysis of 8 perforator flaps of the superior gluteal artery and thirty-two perforator flaps of deep inferior epigastric, in which hand-held doppler finding was contrasted to intra-operative finding discovered a +VE prescient rate of just 52.4 percent for consolidated deep inferior epigastric perforator and superior gluteal artery perforator flaps [20]. Appraisal of Computed Tomography Angiography (CTA) Computed tomography angiography incorporates the utilization of X-radiations with the three-dimensional investigation of the pictures. The quantity of lines of

detectors makes decision on how quickly a scan can be carried out and to what degree detail can be disclosed. An incredible assortment of computed tomography scanners and operating systems are presently accessible, which makes it difficult to compare the results of different studies. The quantity of lines of multi-detector utilized in various studies range from four [28] to sixty-four [29], allowing the generation of cuts of around one mm or more slender, contingent upon the scanner use of Computed tomography. CTA scan has lately appeared as an outstanding and mini-invasive vascular system procedure and is now regarded as a dependable perforating vessel analysis technique. The precision ratio for recognizing the branching source of perforators of antero-lateral thigh have been accounted for to be ninety-eight percent, and pre-operative localization of perforators by computed tomography angiography have revealed to make operation period short essentially [30] Another research found a 100% connection between CTA results and intraoperative results in breast reconstruction of the profound inferior epigastric perforator (DIEP) [29].

Pros of CTA

For anterolateral thigh perforator flap transplantation, Yang et al. used computed tomography angiography (CTA) and revealed a significant reduction in flap complication using CTA as compared to the standard group. [31] The benefit of computed tomography angiography is that it gives a picture with exact visual descriptions on the vessel's route and caliber and their associations with other anatomical structures. This makes it possible for specialists to establish a dissection plan, option for perforators before the operation, and make the dissection more secure and convenient. [28] [32-37]

Cons of CTA

Identification of the smallest divisions of perforator arteries relies on obtaining the CT photos properly. Because of the need about sensitivity to ionizing radiation, CTA utilizes low-dose procedures that minimize patient radiation dose which have the ability to reduce picture quality if image specifications are not optimized [38] While CTA can provide precise info on perforator design, it doesn't deliver preoperative physiological info on perforator flow features or perfusion evaluation [39] The major disadvantages of computed tomography are exposure to radiations and distinctive management. Notably, with the use of multi-detector row CTA with attenuation based online tube current modulation, the radiation dose can be reduced [40] and the nonionic iodinate contrasted medium is viewed as more secure. Despite the fact that computed tomography angiography might incur extra charges, Rozen et al. [41] cost assessment revealed that cost advantages of utilizing pre-operative computed tomography angiography in the harvesting of deep inferior epigastric perforator flaps via decreasing the period of operation and hospital stay.

Appraisal of Color duplex sonography (CDS)

CDS allows assessment of perforator area, size,

and accompanying vessel credibility details such as atherosclerotic disease, prior surgery (scar tissue), or other vascular disorders [42] Color duplex sonography is a promptly accessible noninvasive imaging tool in most vascular components which also provides info regarding the three-dimensional anatomical structures throughout the vasculature to some extent. [43] CDS was effectively used to pre-operatively evaluate flaps in head and neck, trunk (44-48) and extremities [43, 49] for reconstruction. Before ALT flap harvesting, Tsukino et al. [43, 50] researched the reliability of CDS in 10 patients. A comparison of CDS finding with intraoperative finding revealed a 100% concordance. This has been affirmed in a study of 6 cases for deep inferior epigastric perforator (DIEP) flaps [45] Color duplex sonography have been seen of an incentive in instances where the perforated vessels may have been harmed, such as after fat modeling, as it may provide info regarding the quantity of movement in the vessels or in instances where the amount of computed tomography angiography radiation is unwanted [45].

Pros of CDS

Color duplex is noninvasive much like to hand-held Doppler. There is one advantage of CDS if compared it with hand-held Doppler is "its capacity to provide further info regarding vessel's anatomy and perforators with respect to its encompassing tissue and which perforator is the prevailing one can examine quantitatively" [47].

Cons of CDS

The drawback of CDS is that the examination must be carried out by skillful staff, who has enough awareness about anatomical structures of free flap perforator. Moreover, due to its actual dynamic, it's slighter reproducible [33, 51] There is another drawback of CDS with compared to computed tomography angiography, magnetic resonance angiography and digital subtraction angiography is that CDS don't produce a two-dimensional or three-dimensional picture of the whole anatomy of vessels which may be utilized by a specialist through design or elevation of the flap [28, 32, 33].

Appraisal of Digital subtraction angiography (DSA)

An iodine contained contrast medium is given intra-arterial whereas taking X-radiations in conventional angiography. In DSA, for the depiction of vascular anatomy, these contrast-enhancing images are subtracted digitally from the prior to administration of contrast masking X-radiations. This method of inquiry produces 2D pictures and thus usually has to be carried out in two directions. The preliminary picture is saved in memory from an angiographic arrangement. The following pictures are removed from this picture and presented a video monitor as an ongoing screen. This allows the examination to be fully monitored as it is in advancement. The picture data is also saved at real-time rates concurrently on a digital disk [52] In the free flap design, DSA is described transcendentally in flaps of the fibula, where it's fundamental

to knowledgeable regarding congruity of the 3 vessels of the lower legs, tibiofibular trunk bifurcating degree, and on the plaque of arteriosclerotic [52-54] The usage of DSA was also noted in the preparation of musculocutaneous flaps of transverse [55] and oblique [56] rectus abdominis. Throughout the surgery, it was apparently utilized to imagine a flap's vascular design afterwards it is harvested. It may exhibit perforator and its association with the vessels of the axial flap, which in the subordinate procedure can assist the specialist securely thin and isolate the flap [55, 56] However, this is not a frequently reported method.

Pros of DSA

DSA can be conducted in outpatient and making it possible to observe it cost-effectively and in real-time [57] DSA's recounted benefits incorporate the realities that it can deliver a picture of the anatomy of intraluminal vessels and info regarding changing in atherosclerotic.

Cons of DSA

A drawback of digital subtraction angiography is that it's a tedious, invasive method that requires the utilization of iodinated-contrast medium, which may cause to a hypersensitivity reaction, harm to kidney and vessels [58] Additionally, there is a dose of radiation to be contemplated [53] There is an additional drawback of DSA is that the vasoconstriction effects of iodine-contrast medium, make the accurate estimation of the breadth of vessels and the appraisal of small caliber vessels undependable. Besides, after the angiography, the patient must remain in the supine position for many hours to permit healing of puncture location. It often leads to admit in hospital compulsory and modality of image comparatively pricy. Finally, at the puncture place, there is a 4.5 percent possibility of developing fake aneurysms [59].

Appraisal of Magnetic resonance angiography (MRA)

Magnetic resonance imaging consistently adjusts the turn of hydrogen molecules in tissues with the utilization of the magnetic field. As hydrogen molecules come back to their moderate form, the consequent use of radiofrequency pulse outcomes in the release of energy. Magnetic resonance imaging identifies the discharged of energy and information process into anatomical pictures by computer software. Cancer growth haven't been associated with experience to a magnetic field or radiofrequency pulse with magnetic resonance imaging [60]. The vessels enhanced by the infusion of gadolinium (Gd) which is a paramagnetic contrast agent. Although MRI doesn't use radiations, the vessels images are typically found in the arterial phase and consequently to specifically envision just arteries in the blood pool phase and additionally discern the combinations of huge artery and vein. Currently, a latest intravascular contrast agent called Gd, Ablavar has come to be obtainable which is designed to image both phases of artery and blood pool of contrast improvement in the absence of interfering from soft tissues improvement. There's also the likelihood of visualizing vessel in the absence of contrast infusion,

although with minimal resolutions [61]

Magnetic resonance angiography was mainly utilized in the mapping of fibula free flaps. [51] However, currently, it is utilized in the designing of reconstruction of breast perforator-flaps [61] In research containing 56 patients, Masia et al [61] discovered one hundred percent connection among magnetic resonance angiography and intra-operational finding for DIEP flaps. In a research of 31 patients, Greenspun et al. [62] described PPV (Positive Predictive Value) of hundred percent, but an NPV (Negative Predictive Value) of ninety-six percent and utilizing magnetic resonance angiography contrast. However, in the case of fibula flaps, it's unluckily harder to make conclusion regarding the PPV and NPV depend upon present accessible literatures. The studies which associate the pre-operative photographs with operational results are made up of just little populaces and aren't unambiguous [62-67].

Pros of MRA

The pre-operative understanding of MRA results allows surgeons to provide pre-operative specific guidance to patients on practical choices for donor sites choice. In fact, MRA significantly aids in the general protection of intra-operative surgical dissection and decision-making, as well as potential post-operative 2nd flap malfunction choices [68] MRA does not involve ionizing radiation exposure, and usually, it shorts the data period as compared to conventional scans. The benefit of MRA is that it can be carried out in the clinic. MRA is suitable for the recognition of aneurysms, occlusions, and stenosis and is particularly important in cases where the use of contrast agents is high risk. MRA is a piece of favorable machinery to evaluate blood flow and blood vessel morphology accurately and non-invasively. Although it cannot be deemed as a conventional technique at present. It is highly helpful for recognition, particularly in those patients whose diagnosed disease is contraindicated for conventional angiography [69] MRA generates a 3D picture that permits specialists to precisely evaluate the vessel's breadth, route, and their connection to additional encompassing structures before the operation [51, 63, 66].

Cons of MRA

MRA's drawbacks are contraindications for usage with a cardiac pacemaker or patients who are extremely claustrophobic. Maximum claustrophobic patients may endure an anxiolytic MRI. Ongoing progress in MRA has reduced the method period for a single donor position to 20 minutes and reduced the real procurement scan time to 20s.[61, 62, 67, 70] Nevertheless, the examination period for various donor site investigation could be 40 minutes.

Appraisal of Infrared thermography (IRT)

Infrared thermography (IRT) is a fairly long-standing idea, recently applied to vessel imaging. In 1800 Sir William Herschel found "infrared" radiation while calculating the temperature of light [71] In 1929 Kalman Tihanyi discovered a camera grounded on the principle which all

objects in the form of infrared radiation emanate a "heat signal." [72] This radiation is sensed in the same way as a regular camera senses light [72], and produces visible heat maps in the same way images are made. The movement in perforator vessels produces a visible heat signal which can recognize by IRT enabling localization [73].

Pros of IRT

Over time the IRT has grown to become commonly available in the medical industry. In flap preparation and processing, IRT provides a non-ionizing, non-invasive way of determining the position and efficiency of the perforator and therefore assists in making surgical decisions in real time. This will ensure better quality and more effective processes, and possibly enhance patient results [74].

Cons of IRT

First, IRT just delivers perforator position info, in contrast to morphology and physiology. Secondly, any anatomical details supplied are in the form a superficial, 2-dimensional chart. It's remaining essential for the surgeon to retain an in-depth awareness of the local vascular and flap anatomy while viewing such photos. However, IRT is not commonly accessible at present, and few people are educated in its application [74].

Appraisal of Indocyanine green-fluorescence angiography (ICG-FA)

A modern laser-assisted near-infra-red angiography technology with intravenous indocyanine green (ICG) dye will greatly increase the immediacy and precision of the flap perfusion evaluation[75] Imaging using a near-infrared camera network and ICG as a laser-induced fluorescent symbol for the depiction of arteries such as the retinal arteries and anastomoses in cardiac bypass surgery[76] ICG angiography has also been recorded to be efficient for flap blood circulation identification and bile and lymphatic flow visualization[75].

Preferably, ICG angiography imaging should be done during the architecture of the flap and require localization of the perforator vessels underlying it. The flap is then constructed depending on the position and scale of the vessel, since the picture may be replicated after dismemberment to test flap perfusion. Suppose that, image may be done at the time of perforator assortment to determine flap perfusion, where the required perforators are retained and the residual perforators can be provisionally clamped. If considered ineffective, clamps are detached and pick supplementary or alternative vessels. Imaging can identify flap perfusion after transition during microsurgery and assess blood flow inside the anastomosis[77].

Pros of ICG-FA

ICG-FA may be useful in intra-operatively testing the perfusion of pedicle perforator flaps by defining areas of reduced infusion. When clinical findings such as sufficient bleeding from the boundaries of the wound deny this info, resection of the tissue may be suspended to allow perfusion stabilization [78] ICG-FA will provide a more detailed

picture of the specific region where a pedicle (angiosome) or an actual perforator (perfosome) perfuses. ICG-FA could make for better choice of perforators and likely reduce the occurrence of partial flap failure[77] In autologous breast reconstruction with microvascular-free flaps, ICG-FA has helped to minimize post-operative fat necrosis by enabling visualization intra-operatively of the degree of critically perfused regions that require resection[79] ICG angiography can be beneficial for pre-operative flap choice preparation and for intra-operative / post-operative evaluation of flaps utilized in reconstructive surgery. It has the ability to be advantageous in making judgments on replantation operation, surgical debridement in accident or cancer treatment, and also in deciding amputation rates. ICG angiography is a novel plastic surgeon innovation for evaluating perforators, angiosomes, and flap perfusion, all of which are central to plastic surgery values; offering reconstructions that reduce recipient morbidity and enhance clinical results[77].

Cons of ICG-FA

The main drawback of ICG-FA is that its precise only as a snapshot in time. Consequently, forecasting flap ischemia may not be hundred percent reliable due to certain causes such as geographic vasospasm, post-operative edema, dressings and non-compliance with patients [77] While there is no precise vital perfusion index rating, a filling flaw shown from ICGA on a pedicle flap during restoration can allow alteration of the surgical strategy to avoid flap impediments pro-actively[80].

Comparison of CTA and MRA

Over a 15-second breath-hold journey through the bore of the CT scanner, regular scanners rapidly obtain 0.5 mm on any photo resolution pictures. In other words, the tissue volumes shown on each picture are 0.5x, 0.5x, 0.5 mm in any plane of obliquity. This is enough resolution to study entirely major coronary artery sections. Plaque with and without calcium can be quantified under optimal conditions as none, slight, temperate and severe. CTA's benefit over MRA is that it can more correctly portray tiny vessels and particularly perforators. That's why computed tomography angiography is dominantly utilizing in the perforator-flap scan, where the perforators route and volume are of big significance for the medical procedure [32, 33]. MRA's primary benefits above computed tomography angiography are "it is the absence of patient experience with ionizing radiations and need to utilize the probable nephrotoxin contrast-medium [61, 66].

Comparison of color Doppler ultrasound (CDUS) and computed tomography angiography (CTA)

Feng, et al. has made a comparison between CDUS and CTA for their unwavering quality and affectability in identifying the perforator's area precisely [81] They indicated that in identifying the location of dominant perforators, the preoperational CDUS accuracy rate is 95 percent and the CTA accuracy rate is 82.5 percent

which is lower as compared to CDUS. Nevertheless, this disparity wasn't statistically substantial. The mean error (ME) value of CDUS findings was 1.11 ± 1.29 mm, while the ME value of CTA was 2.55 ± 2.63 mm which are noteworthy statistical contrast. Contrarily, the period required for analyzing the pictures utilizing CTA is 27.2 ± 1.77 min recorded lower than the period for CDUS is 34.83 ± 3.55 min. the achievement of CDUS have been straightforwardly associated with the radiologist's skill; however, for CTA, the same haven't been true [81] Metal implants in CTA pictures are recognized to create artifact formation, but this does not concern to CDUS. On the other side, Doppler ultrasound is an inexpensive method in contrast to CT angiography [81] Thus, Feng et al. proposed using CDUS in skilled hands rather than CTA to locate perforators better, and it is also less costly [81] .

Comparison of CDS, CTA and MRA

CDS is noninvasive and gives 3D anatomy around vessels [43] but it is only can be performed by a skillful person who require to enough experience of flap surgery. Additionally, its less reproducible because of its real-life dynamics[33,51] Only in specific cases, for example, in situations where CT angiography and MR angiography are inadvisable or where there're particular inflows inside the vessel, should CDS be used as the main mapping method [2].

Comparison of DSA, CDS, CTA, and MRA

With the implementations of color duplex ultrasound, computed tomography angiography, magnetic resonance angiography, the DSA's needed as an essential mapping tool in free-flaps preparation seem to fade. It is more invasive, requiring a dose of radiation and utilization of iodinated contrast-medium in comparison to CDS and MRA. Moreover, it's only generate two-dimensional pictures, and eventually, there might be false aneurysm take place [2].

Comparison of IRT, Doppler ultrasound, ICG-FA, MRA and CTA

IRT is a 2-dimensions map. IRT is usable with CTA and MRA, in comparison to 3D modeling [74] It is also necessary to remember that IRT can only include details to a certain extent, in addition to having a two-dimensional map[74] It is mean that perforators in subcutaneous tissues may not be identified further from the skin surface, and thus may be unnoticed in flap planning via IRT. CTA is superior at recognizing those perforators [82] Doppler ultrasound is operator dependent for perforator detection

and high inter-user variability, with limited responsiveness. MRI, ICG angiography and CTA are costly, need the usage and interpretation of proper instruction, and involve the usage of contrast and/or ionizing radiation. MRI and CTA do not have any perforator consistency details and can't be utilized for intra-operative or post-operative surveillance [83]. In addition, MR and CT are timewasting and based on the availability of scanners and awaiting catalogs, which need feedback from radiology for analysis which reporting. In contrast, the operational surgeon can perform and interpret IRT either pre-operatively or in a preliminary clinical setting, and it just takes five min to perform once people are primarily skilled. Consequently, IRT offers a faster, less intrusive skin perfusion evaluation process, deprived of the hazards related with ionizing radiation and contrast injection [84].

CONCLUSION

Before free flap transfer, preoperative imaging of perforators is a crucial step to take in order to minimise problems and maximize flap harvesting. Currently, pertinent details on the presence, origin, course, dimension, and traits of the perforators and of their feeding tubes are available. This review illustrated the pros, cons and comparison of different methodologies used in perforator vascular localization assistant. All the methodologies have their own pros and cons but surgeon can choose the suitable method to assist localization of vascular perforator flap according to the place and type of flap which is going to harvest. In comparison to all methodologies, CDS is invasive, more reliable, less expensive, and easy to locate vascular perforator flap. However, further studies need to find out novel methodology which can overcome the disadvantages of present techniques.

AUTHOR CONTRIBUTIONS

Rizwan Ali and Jinghong Xu conceived the project. Jinghong Xu supervised the project and provided guidance. All authors wrote, edited, and approved the final manuscript.

FUNDING

Nil

COMPETING INTEREST

The Authors declare that there is no conflict of interest.

REFERENCES

1. **Blondeel PN, Van Landuyt KH, Monstrey SJ, et al.** The "Gen" consensus on perforator flap terminology: preliminary definitions. *Plast Reconstr Surg.* 2003;112(5):1378-1383
2. **Smit JM, Klein S, Werker PM.** An overview of methods for vascular mapping in the planning of free flaps. *JPRAS.* 2010;63(9):674-682.
3. **Kao HK, Chang KP, Chen YA, et al.** Anatomical basis and versatile application of the free medial sural artery perforator flap for head and neck reconstruction. *JPRAS.* 2010;125(4):1135-1145.
4. **Hijawi JB, Blondeel PN.** Advancing deep inferior epigastric artery perforator flap breast reconstruction through multidetector row computed tomography: an evolution in preoperative imaging. *J Reconstr Microsurg Open.* 2010;26(1):11-20.
5. **DeBono R, Thompson A, Stevenson JH.** Immediate versus delayed free TRAM breast reconstruction: an analysis of perioperative factors and complications. *Br J Plast Surg.* 2002;55(2):111-116.
6. **Chang DW, Reece GP, Wang B, Robb GL, et al.** Effect of smoking on complications in patients undergoing free TRAM flap breast reconstruction. *Plast Reconstr Surg.* 2000;105(7):2374-2380.
7. **Mackay DR, Braun SA, Stott RS.** Problems with the transverse rectus abdominis myocutaneous island flap in breast reconstruction. *SAMJ.* 1989;76(12):654-656.
8. **Ribuffo D, Muratori L, Antoniadou K, et al.** A hemodynamic approach to clinical results in the TRAM flap after selective delay. *Plast Reconstr Surg.* 1997;99(6):1706-1714.
9. **Blondeel PN, Beyens G, Verhaeghe R, et al.** Doppler flowmetry in the planning of perforator flaps. *Br J Plast Surg.* 1998;51(3):202-209.
10. **Rand RP, Cramer MM, Strandness DE, Jr.** Color-flow duplex scanning in the preoperative assessment of TRAM flap perforators: a report of 32 consecutive patients. *Plast Reconstr Surg.* 1994;93(3):453-9.
11. **Blondeel PN, Arnstein M, Verstraete K, et al.** Venous congestion and blood flow in free transverse rectus abdominis myocutaneous and deep inferior epigastric perforator flaps. *Plast Reconstr Surg.* 2000;106(6):1295-1299.
12. **Schaverien M, Saint-Cyr M, Arbique G, et al.** Arterial and venous anatomies of the deep inferior epigastric perforator and superficial inferior epigastric artery flaps. *Plast Reconstr Surg.* 2008;121(6):1909-1919.
13. **Saba L, Atzeni M, Rozen WM, et al.** Non-invasive vascular imaging in perforator flap surgery. *Acta Radiologica.* 2013;54(1):89-98.
14. **Lianjun W, Huiming W.** Application of preoperative vascular localization techniques for perforator flaps. 2017;35(6):659-662.
15. **Taylor GI, Doyle M, McCarten G.** The Doppler probe for planning flaps: anatomical study and clinical applications. *Br J Plast Surg.* 1990;43(1):1-16.
16. **Mun GH, Jeon BJ.** An efficient method to increase specificity of acoustic Doppler sonography for planning a perforator flap: perforator compression test. *Plast Reconstr Surg.* 2006;118(1):296-297.
17. **Yu P, Youssef A.** Efficacy of the handheld Doppler in preoperative identification of the cutaneous perforators in the anterolateral thigh flap. *Plast Reconstr Surg.* 2006;118(4):928-933.
18. **Khan UD, Miller JG.** Reliability of handheld Doppler in planning local perforator-based flaps for extremities. *Aesthetic plastic surgery.* 2007;31(5):521-525.
19. **Shaw RJ, Batstone MD, Blackburn TK, et al.** Preoperative Doppler assessment of perforator anatomy in the anterolateral thigh flap. *Br J Plast. Surg.* 2010;48(6):419-422.
20. **Giunta RE, Geisweid A, Feller AM.** The value of preoperative Doppler sonography for planning free perforator flaps. *Plast. Reconstr. Surg.* 2000;105(7):2381-2386.
21. **Jakubietz RG, Jakubietz MG, Gruenert JG, et al.** The 180-degree perforator-based propeller flap for soft tissue coverage of the distal, lower extremity: a new method to achieve reliable coverage of the distal lower extremity with a local, fasciocutaneous perforator flap. *Ann Plast Surg.* 2007;59(6):667-671.
22. **Misra A, Niranjana NS.** Fasciocutaneous flaps based on fascial feeder and perforator vessels for defects in the patellar and peripatellar regions. *Plast Reconstr Surg.* 2005;115(6):1625-1632.
23. **Ahmad N, Kordestani R, Panchal J, et al.** The role of donor site angiography before mandibular reconstruction utilizing free flap. *J. Reconstr. Microsurg. Open.* 2007;23(4):199-204.
24. **Hamdi M, Van Landuyt K, Monstrey S, et al.** Pedicled perforator flaps in breast reconstruction: a new concept. *Br J Plast Surg.* 2004;57(6):531-539.
25. **D'Arpa S, Cordova A, Pirrello R, et al.** Free style facial artery perforator flap for one stage reconstruction of the nasal ala. *JPRAS.* 2009;62(1):36-42.
26. **Niranjana NS, Price RD, Govilkar P.** Fascial feeder and perforator-based V-Y advancement flaps in the reconstruction of lower limb defects. *Br J Plast Surg.* 2000;53(8):679-689.
27. **Puri V, Mahendru S, Rana R.** Posterior interosseous artery flap, fasciosubcutaneous pedicle technique: a study of 25 cases. *JPRAS.* 2007;60(12):1331-1337.
28. **Alonso-Burgos A, Garcia-Tutor E, Bastarrika G, et al.** Preoperative planning of deep inferior epigastric artery perforator flap reconstruction with multislice-CT angiography: imaging findings and initial experience. *JPRAS.* 2006;59(6):585-93.
29. **Rozen WM, Phillips TJ, Ashton MW, et al.** Preoperative imaging for DIEA perforator flaps: a comparative study of computed tomographic angiography and doppler ultrasound. *Plast Reconstr Surg.* 2008;121(1):1-8.
30. **Chen SY, Lin WC, Deng SC, et al.** Assessment of the perforators of anterolateral thigh flaps using 64-section multidetector computed tomographic angiography in head and neck cancer reconstruction. *EJSO.* 2010;36(10):1004-1011.
31. **Yang JF, Wang BY, Zhao ZH, et al.** Clinical applications of preoperative perforator planning using CT angiography in the anterolateral thigh perforator flap transplantation. *Clinical radiology.* 2013;68(6):568-573.
32. **Masia J, Clavero JA, Larranaga JR, et al.** Multidetector-row computed tomography in the planning of abdominal perforator flaps. *JPRAS.* 2006;59(6):594-599.
33. **Smit JM, Dimopoulou A, Liss AG, et al.** Preoperative CT angiography reduces surgery time in perforator flap reconstruction. *JPRAS.* 2009;62(9):1112-1117.
34. **Pacifico MD, See MS, Cavale N, et al.** Preoperative planning for DIEP breast reconstruction: early experience of the use of computerized tomography angiography with VoNavix 3D software for perforator navigation. *JPRAS.* 2009;62(11):1464-1469.
35. **Rozen WM, Ashton MW, Grinsell D, et al.** Establishing the case for CT angiography in the preoperative imaging of abdominal wall perforators. *Microsurgery.* 2008;28(5):306-313.
36. **Rozen WM, Ashton MW.** The "limited rectus sheath incisions" technique for DIEP flaps using preoperative CT angiography. *Microsurgery.* 2009;29(7):525-528.
37. **Ribuffo D, Atzeni M, Saba L, et al.** Angio computed tomography preoperative evaluation for anterolateral thigh flap harvesting. *Ann Plast Surg.* 2009;62(4):368-371.
38. **Thimmappa N, Bhat AP, Bishop K, et al.** Preoperative cross-sectional mapping for deep inferior epigastric and profunda artery perforator flaps. *Cardiovasc Diagn Ther.* 2019;9(1):131-142.
39. **Mohan AT, Saint-Cyr M.** Advances in imaging technologies for planning breast reconstruction. *Gland surgery.* 2016;5(2):242-254.
40. **Greess H, Wolf H, Baum U, et al.** Dose reduction in computed tomography by attenuation-based on-line modulation of tube current: evaluation of six anatomical regions. *European radiology.* 2000;10(2):391-394.
41. **Rozen WM, Ashton MW, Whitaker IS, et al.** The financial implications of computed tomographic angiography in DIEP flap surgery: a cost analysis. *Microsurgery.* 2009;29(2):168-169.
42. **Oliva IB, Day K, Dill KE, et al.** ACR Appropriateness Criteria((R)) Imaging of Deep Inferior Epigastric Arteries for Surgical Planning (Breast Reconstruction Surgery). *JACR.* 2017;14(11):456-461.
43. **Tsukino A, Kurachi K, Inamiya T, et al.** Preoperative color Doppler assessment in planning of anterolateral thigh flaps. *Plast Reconstr Surg* 2004;113(1):241-246.
44. **Heitland AS, Markowicz M, Koellensperger E, et al.** Duplex ultrasound imaging in free transverse rectus abdominis muscle, deep inferior epigastric artery perforator, and superior gluteal

- artery perforator flaps: early and long-term comparison of perfusion changes in free flaps following breast reconstruction. *Ann Plast Surg*. 2005;55(2):117-121.
45. De Frene B, Van Landuyt K, Hamdi M, et al. Free DIEAP and SGAP flap breast reconstruction after abdominal/gluteal liposuction. *JPRAS*. 2006;59(10):1031-1036.
 46. Yano K, Hosokawa K, Nakai K, et al. A rare variant of the deep inferior epigastric perforator: importance of preoperative color-flow duplex scanning assessment. *Plast Reconstr Surg*. 2003;111(4):1578-1579.
 47. Ogawa R, Hyakusoku H, Murakami M. Color Doppler ultrasonography in the planning of microvascular augmented "super-thin" flaps. *Plast Reconstr Surg*. 2003;112(3):822-828.
 48. Chen JJ, Giese S, Jeffrey RB, et al. Treatment and stabilization of complex wounds involving the pelvic bone, groin, and femur with the inferiorly based rectus abdominis musculocutaneous flap and the use of power color Doppler imaging in preoperative evaluation. *Ann Plast Surg*. 1999;43(5):494-498.
 49. Futran ND, Stack BC. Use of color Doppler flow imaging for preoperative assessment in fibular osteoseptocutaneous free tissue transfer. *Otolaryngol Head Neck Surg*. 1997;117(6):660-663.
 50. Michlits W, Papp C, Hormann M, et al. Nose reconstruction by chondrocutaneous preauricular free flaps: anatomical basis and clinical results. *Plast Reconstr Surg*. 2004;113(3):839-844.
 51. Lohan DG, Tomasian A, Krishnam M, et al. MR angiography of lower extremities at 3T: presurgical planning of fibular free flap transfer for facial reconstruction. *AJR American journal of roentgenology*. 2008; 190 (3):770-6.
 52. Ovitt TW, Newell JD 2nd. Digital subtraction angiography: technology, equipment, and techniques. *Medical instrumentation*. 1986; 20(4):199-205.
 53. Monaghan AM, Dover MS. Assessment of free fibula flaps: a cautionary note. *The British journal of oral & maxillofacial surgery*. 2002; 40(3):258-9.
 54. Seres L, Csaszar J, Voros E, et al. Donor site angiography before mandibular reconstruction with fibula free flap. *The Journal of craniofacial surgery*. 2001; 12(6):608-13.
 55. Ohjimi H, Era K, Fujita T, Tanaka T, et al. Analyzing the vascular architecture of the free TRAM flap using intraoperative ex vivo angiography. *Plastic and reconstructive surgery*. 2005; 116(1):106-13.
 56. Ohjimi H, Era K, Tanahashi S, et al. Ex vivo intraoperative angiography for rectus abdominis musculocutaneous free flaps. *Plastic and reconstructive surgery*. 2002; 109(7):2247-2456.
 57. Hayashi K, Matsunaga N, Fujisawa H, et al. [Digital radiography--clinical application of digital subtraction angiography]. *Gan no rinsho Japan journal of cancer clinics*. 1983; 29(10):1191-1198.
 58. Valentini V, Agrillo A, Battisti A, et al. Surgical planning in reconstruction of mandibular defect with fibula free flap: 15 patients. *The Journal of craniofacial surgery*. 2005; 16(4):601-7.
 59. Gabriel M, Pawlaczek K, Waliszewski K, et al. Location of femoral artery puncture site and the risk of postcatheterization pseudoaneurysm formation. *Int J Cardiol*. 2007; 120(2):167-71.
 60. Shellock FG, Cruess JV. MR procedures: biologic effects, safety, and patient care. *Radiology*. 2004; 232(3):635-52.
 61. Masia J, Kosutic D, Cervelli D, et al. In search of the ideal method in perforator mapping: noncontrast magnetic resonance imaging. *Journal of reconstructive microsurgery*. 2010; 26(1):29-35.
 62. Greenspun D, Vasile J, Levine JL, et al. Anatomic imaging of abdominal perforator flaps without ionizing radiation: seeing is believing with magnetic resonance imaging angiography. *Journal of reconstructive microsurgery*. 2010; 26(1):37-44.
 63. Fukaya E, Grossman RF, Saloner D, et al. Magnetic resonance angiography for free fibula flap transfer. *Journal of reconstructive microsurgery*. 2007; 23(4):205-211.
 64. Rozen WM, Stella DL, Bowden J, et al. Advances in the preoperative planning of deep inferior epigastric artery perforator flaps: magnetic resonance angiography. *Microsurgery*. 2009; 29(2):119-23.
 65. Rozen WM, Ashton MW, Stella DL, et al. Magnetic resonance angiography and computed tomographic angiography for free fibular flap transfer. *Journal of reconstructive microsurgery*. 2008; 24(6):457-8.
 66. Kelly AM, Cronin P, Hussain HK, et al. Preoperative MR angiography in free fibula flap transfer for head and neck cancer: clinical application and influence on surgical decision making. *AJR American journal of roentgenology*. 2007; 188(1):268-74.
 67. Neil-Dwyer JG, Ludman CN, Schaverien M, et al. Magnetic resonance angiography in preoperative planning of deep inferior epigastric artery perforator flaps. *Journal of plastic, reconstructive & aesthetic surgery: JPRAS*. 2009; 62(12):1661-5.
 68. Thimmappa ND, Vasile JV, Ahn CY, et al. MRA of the skin: mapping for advanced breast reconstructive surgery. *Clinical radiology*. 2019; 74(1):13-28.
 69. Handelsman H. Magnetic resonance angiography: vascular and flow imaging. *Health Technol Assess (Rockv)*. 1994(3):1-20.
 70. Vasile J, Newman T, Prince M, et al. Contrast-Enhanced Magnetic Resonance Angiography. *Clinics in plastic surgery*. 2011; 38:263-75.
 71. Ring EFJ. The discovery of infrared radiation in 1800. *The Imaging Science Journal*. 2000; 48(1):1-8.
 72. Ring EF. The historical development of thermal imaging in medicine. *Rheumatology (Oxford, England)*. 2004; 43(6):800-802.
 73. de Weerd L, Mercer JB, Weum S. Dynamic infrared thermography. *Clin Plast Surg*. 2011; 38(2):277-92.
 74. Hennessy O, Potter SM. Use of infrared thermography for the assessment of free flap perforators in autologous breast reconstruction: A systematic review. *JPRAS Open*. 2019; 23:60-70.
 75. Benson RC, Kues HA. Fluorescence properties of indocyanine green as related to angiography. *Physics in medicine and biology*. 1978; 23(1):159-63.
 76. Reuthebuch O, Haussler A, Genoni M, et al. Novadaq SPY: intraoperative quality assessment in off-pump coronary artery bypass grafting. *Chest*. 2004; 125(2):418-424.
 77. Liu DZ, Mathes DW, Zenn MR, et al. The application of indocyanine green fluorescence angiography in plastic surgery. *Journal of reconstructive microsurgery*. 2011; 27(6):355-64.
 78. Jakubietz RG, Schmidt K, Bernuth S, et al. Evaluation of the Intraoperative Blood Flow of Pedicled Perforator Flaps Using Indocyanine Green-fluorescence Angiography. *Plastic and reconstructive surgery Global open*. 2019; 7(9):e2462.
 79. Phillips BT, Lanier ST, Conkling N, et al. Intraoperative perfusion techniques can accurately predict mastectomy skin flap necrosis in breast reconstruction: results of a prospective trial. *Plastic and reconstructive surgery*. 2012; 129(5):778e-88e.
 80. Yeoh MS, Kim DD, Ghali GE. Fluorescence angiography in the assessment of flap perfusion and vitality. *Oral and maxillofacial surgery clinics of North America*. 2013; 25(1):61-66.
 81. Feng S, Min P, Grasseti L, et al. A Prospective Head-to-Head Comparison of Color Doppler Ultrasound and Computed Tomographic Angiography in the Preoperative Planning of Lower Extremity Perforator Flaps. *Plastic and reconstructive surgery*. 2016; 137(1):335-47.
 82. Weum S, Mercer JB, de Weerd L. Evaluation of dynamic infrared thermography as an alternative to CT angiography for perforator mapping in breast reconstruction: a clinical study. *BMC medical imaging*. 2016; 16(1):43.
 83. de Weerd L, Miland AO, Mercer JB. Perfusion dynamics of free DIEP and SIEA flaps during the first postoperative week monitored with dynamic infrared thermography. *Annals of plastic surgery*. 2009; 62(1):42-7.
 84. John HE, Niumsawatt V, Rozen WM, et al. Clinical applications of dynamic infrared thermography in plastic surgery: a systematic review. *Gland surgery*. 2016; 5(2):122-32.