

Post Irradiation Pelvic Sarcoma 8 Years after Treatment for Adenocarcinoma for Prostate: About a Case

Lai-Tiong F,
Michalet M,
Ruyer A,
Ripoche J,
Van-Hulst S and
Houede N

Medical Oncology unit, Cancer Institute of Gard, University of Nîmes, France

Corresponding author:

Florence lai-Tiong

✉ florence.lai-tiongfofo@laposte.net

Medical Oncology unit, Cancer Institute of Gard, University of Nîmes, France.

Tel: 0685973306

Citation: Lai-Tiong F, Michalet M, Ruyer A, et al. Post Irradiation Pelvic Sarcoma 8 Years after Treatment for Adenocarcinoma for Prostate: About a Case. Arch Cancer Res. 2016, 4:1.

Abstract

Radiotherapy for prostate cancer can be associated with the development of second cancer, primarily carcinoma and exceptionally sarcomas. We report a case of post irradiation pelvic sarcoma eight years after external beam radiotherapy for localized T1c prostate adenocarcinoma. Eight years after the radiotherapy he showed a radio-induced high grade sarcoma. Although the use of external beam radiation therapy for the treatment of prostate cancer has been common practice for decades and despite such cases being regarded as extremely rare, post-irradiation sarcoma should be considered as a potential cause of pelvic pain developing after radiotherapy.

Keywords: Prostate cancer, Radiotherapy, Postradiation sarcoma

Received: January 14, 2016; **Accepted:** February 15, 2016; **Published:** February 18, 2016

Introduction

Radiotherapy for prostate cancer can be associated with the development of second cancer. The majority are carcinomas while post-irradiation sarcomas are exceptional. We report the case of a 75 year-old Caucasian male who was diagnosed with a pelvic sarcoma eight years after external beam radiotherapy.

Case Presentation

A seventy-five year-old Caucasian male presented with rapidly progressive incontinence and obstipation eight years after high dose radiotherapy for prostate adenocarcinoma.

At the age of 67, the patient had been diagnosed with moderately differentiated localized T1c adenocarcinoma with a Gleason score of 6(3+3) using needle biopsy of the prostate. Pre-treatment Prostate-Specific-Antigen (PSA) had been 5.63 ng/ml (normal range < 4 ng/ml).

First, he underwent radiation therapy at 80 Gy on the prostate and 54 Gy on the seminal glands. PSA nadir of 0.98 was achieved in four years after treatment, and no urinary or digestive toxicity were described.

Five years after irradiation, PSA had risen slightly and the patient began Leuproreline three years later, after the Positron Emission Tomography (PET) imaging had showed a localized prostate hypermetabolism and that PSA had reached 4.45 ng/ml.

New needle biopsy of the prostate revealed a Gleason score of 8(4+4) adenocarcinoma.

After one year of hormonal ablation therapy the patient showed obstructive symptomatology and septicemia.

On physical examination, he had pelvic and lumbar pain, constipation, substantial increase in nocturia and dysuria.

The patient received large-spectrum antibiotics and underwent derivation surgery with a colostomy. Transanal-guided biopsies were performed. PSA levels continued to be low at 1.79 ng/ml.

Abdominal Computed Tomography (CT) scan revealed a huge heterogeneous mass measuring 10.5 × 10.7 cm. Thorax CT scan did not find lung dissemination (**Figure 1**).

Prostate high-grade sarcoma with rectum extension was suspected (**Figures 2 and 3**).

On histological examination, mitoses were easily found: 3/10 fields and there were multiple foci of necrosis. On immunohistochemistry, the tumor cells were positive for CD31 and negative for: cytokeratine AE1-AE3, CK7,CK5-6,CK20,EMA,P63,PSA,CDX2,PSO4S, chromogranine A,PS100,CD34,Actine, Desmine, Caldesmone, CD117,DOG1.

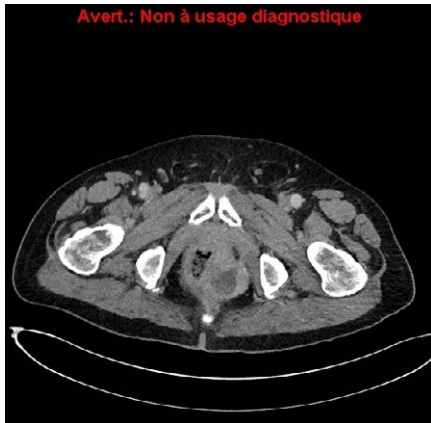

Figure 1 Computed Tomography scan showing a left lateral heterogeneous mass.

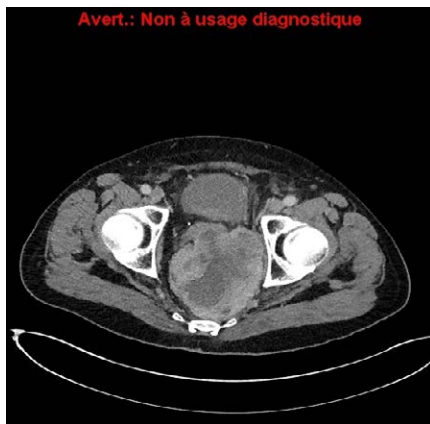


Figure 2 Contact of the mass with rectum.

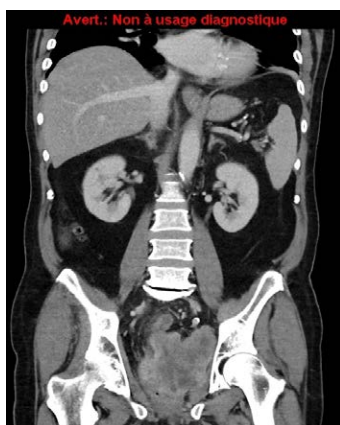

Figure 3 The mass invaded the pelvis.

On the basis of these results, the tumor was classified as a high-grade (III) pleomorphic undifferentiated cell sarcoma, linked to radiotherapy.

Sarcomatoid sarcoma was excluded because of the absence of epithelial markers. The patient, due to the invasion of the rectum, was not eligible for surgery and received neoadjuvant based-

Anthracycline chemotherapy. After three cycles of chemotherapy with DOXORUBICIN 50 mg/m² every three weeks, central necrosis of the tumor was observed, but a metastasis in the liver appeared.

Chemotherapy was followed. After 6 cycles of chemotherapy, partial response was obtained. Tumor surgery and metastasectomy were planned.

Discussion

The first clinical association between exposure to radiotherapy and sarcoma was recognized in 1992 by Beck, in a description of bone sarcomas in patients who had received radiotherapy for tuberculous arthritis [1]. These tumors usually occur many years after exposure to radiation and are associated with a poor prognosis [2]. Post-irradiation bone sarcomas are more common than soft tissue sarcomas. Radiation-induced sarcomas are rare tumors, more malignant than prostatic adenocarcinoma, representing less than 0.2% of all irradiated patients [3]. Local symptoms are the most frequent presentation. In our case the patient presented sub-occlusion symptoms; that lead to diagnosis [4].

CT scan is useful for the diagnosis, because it will help to study locoregional and distant spread of the disease. Nevertheless the definitive diagnosis is established through biopsy. Several publications suggest that there is an increased risk of second cancers after radiotherapy or brachytherapy [5].

Cahan et al. established in 1948 criteria to diagnose a post-irradiation neoplasm: localization of the tumor, latent period over than four years, completely different histological between the two lesions, any genetic predisposition for tumor [6]. Our patient had no familial history that could suggest a hereditary genetic disorder. Brenner et al. found that 1 of 250 irradiated patients for prostate cancer would develop secondary cancer after 5 years, while after 10 years 1 of 70 patients would [7]. The second cancers appear in the radiation field, adjacent to it or in distant sites. These authors reported the high risk for developing pelvic sarcoma after radiotherapy that was 85% (IC95% [15-201%]).

For patients with bulky disease who may be at risk for positive surgical margins, small series have demonstrated that neoadjuvant doxorubicin and cisplatin can produce significant tumor necrosis [8]. Experimental studies suggest that intensity-modulated radiation therapy may be associated with up to three times higher risk of secondary malignancy [9].

There are few cases of radiation-induced prostatic sarcoma reported in the medical literature. Due to the increased-life expectancy with improved survival in cancer patients, the incidence is expected to be higher.

Conclusion

Sarcoma of the prostate is a rare and aggressive malignancy that can develop many years after treatment for prostate adenocarcinoma.

In addition to long-term surveillance for disease recurrence, there should be suspicion for development of second cancer when obstructive symptoms occur without biochemical relapse, particularly when the patient has a history of pelvic irradiation.

References

- 1 Beck A (1992) Zur frange des Rontgensarkoms, zugleich ein Beitrag zur pathogenesis des Sarkoms. Muench Med Wochenshr 69: 623-625.
- 2 Laskin WB, Silverman TA, Enzinger FM (1988) Postradiation soft tissue sarcomas: an analysis of 53 cases. Cancer 62: 2330-2340.
- 3 Rammeh S, Zermani R, Sfaxi M, Farah F, Zouari S, et al. (2006) Prostatic stromal sarcoma. Prog Urol 16: 381-383.
- 4 SextonWJ, Lance RE, ReynesAO, Pisters PW, Tu SM, et al. (2001) Adult prostate sarcoma: the M.D. Anderson Cancer Center Experience. J Urol 166: 521-525.
- 5 Adel-Wahab M, Reis IM, Hamilton K (2008) Second primary cancer after radiotherapy for prostate cancer- a SEER analysis of brachytherapy versus external beam radiotherapy. Int J Radiat Oncol Biol Phys 72: 58-68.
- 6 Hall E, In de Vita VT, Hellman S (1993) Principles of carcinogenesis. In: Devita VT, Hellman S, Rosembreg SA, editors. Cancer: Principles and practice of oncology.4th ed. Philadelphia, PA: Lippincott 213.
- 7 Brenner DJ, Curtis RE, Hall EJ, Ron E (2000) Second malignancies in prostate carcinoma patients after radiotherapy compared with surgery. Cancer 88: 398-406.
- 8 Ahlering TE, Weintraub P, Skinner DG (1988) Management of adult sarcomas of the bladder and prostate. J Urol 140: 1397-1399.
- 9 Kry SF, Salehpour M, Followill DS, Stovall M, Kuban DA, et al. (2005) The calculated risk of fatal secondary malignancies from intensity-modulated radiation therapy. Int J Radiat Oncol Biol Phys 62: 1195-1203.