

DOI: 10.21767/2171-6625.100090

# Post-operative *Herpes Simplex Virus* Encephalitis after Surgical Resection of Meningioma: A Case Report and Review of the Literature

Mohammad Samadian, Mehrdad Hosseinzadeh Bakhtevvari and Omidvar Rezaei

Department of Neurosurgery, Loghman e Hakim hospital, Shahid Beheshti University of Medical Sciences, Tehran-Iran

**Corresponding author:** Mehrdad Hosseinzadeh Bakhtevvari, M.D., Clinical Neurosurgeon, Department of Neurosurgery, Loghman Hakim Hospital, Shahid Beheshti University of Medical Sciences, Tehran-Iran, Tel: +9821-55414065; +98912-1874506; E-mail: mehrdaada@yahoo.com

**Received:** Jan 22, 2016; **Accepted:** Mar 08, 2016; **Published:** Mar 15, 2016

## Abstract

**Background:** *Herpes Simplex Virus* (HSV) encephalitis is a rare but life threatening complication in neurosurgical patients. Diagnosis of Herpes Simplex Encephalitis (HSVE) is based on the detection of the *herpes simplex virus* (HSV) DNA in patient's CSF samples. A low threshold for both investigations with CSF PCR and empirical treatment with intravenous acyclovir is warranted.

**Methods and materials:** In this case we discussed a 55-year-old man with HSVE after surgical resection of meningioma. We represent a rare case of HSV encephalitis. The appearance of a high grade fever (40°C) and altered consciousness and spastic quadriparesia complicated the post-operative course in a 55-year-old man who underwent surgical removal of a meningioma on the second postoperative day. Brain MRI detected brain abnormalities on the fourth day after onset of symptoms, and polymerase chain reaction (PCR) identification of HSV 1 DNA confirmed the diagnosis.

**Result:** A positive prognosis was achieved due to the decision to start specific, high-dose antiviral therapy based on clinical suspicion, before a firm diagnosis was established. . Treatment with acyclovir was maintained for 8 weeks and patient die after severe sepsis.

**Conclusion:** There are only few case reports of postoperative HSV1 encephalitis. These reports suggest that this rare postoperative complication is associated with a poor prognosis, with high mortality and morbidity. Neurosurgical interventions involving peripheral nerve root or ganglia have been reported to cause re-activation of cutaneous *herpes simplex* infection. Factors compromising the immune system may also increase susceptibility to *herpes simplex* infection.

**Keywords:** Encephalitis; *Herpes simplex virus*; Meningioma; Post-operative

## Introduction

*Herpes Simplex Virus* (HSV) encephalitis is the most common form of sporadic viral encephalitis [1]. It can manifest at any time of the year, in patients of all ages, and is associated with significant morbidity and mortality [2-5]. HSV usually begins as a febrile illness with symptoms of diffuse and focal cerebral involvement, such as headaches, personality changes, obtundation, focal seizures and paresis [6,7]. Postoperative herpes simplex encephalitis has been rarely described. HSV encephalitis is an extremely life-threatening consequence of the HSV infection of the central nervous system. It is said that the HSV encephalitis is extremely rare, and only a minority of individuals return to normal functions. Antiviral therapy is most effective when early, necessitating prompt diagnosis started.

Actually, preventing the inflammation of spreading from a small area of the brain inflammation to a bigger involved area is an extremely important issue. In fact, of all different types of viral encephalitis, HSV encephalitis is one of the few viral causes of diseases for which we actually have accurate diagnostic tests and relatively cheap treatments already available [8].

The necessity for treatment is dictated by factors such as age, the immune system function, the type and severity of the disease, or mild cases- the amount of stress the condition causes [9]. The occurrence of HSV encephalitis after neurosurgery is rare and only a small number of cases have been reported in the literature. In this report we represent a rare case of HSV encephalitis in a 55-year-old man.

## Methods and Materials

### Case report

Intracranial infections following neurosurgery are most commonly caused by bacteria. Postoperative herpes simplex encephalitis has been described rarely before. Herpes simplex virus encephalitis is a life-threatening consequence of HSV infection of the central nervous system. Only a minority of individuals return to normal functions when faced by this

disease (**Table 1**). Antiviral therapy is most effective when early, necessitating prompt diagnosis is started.

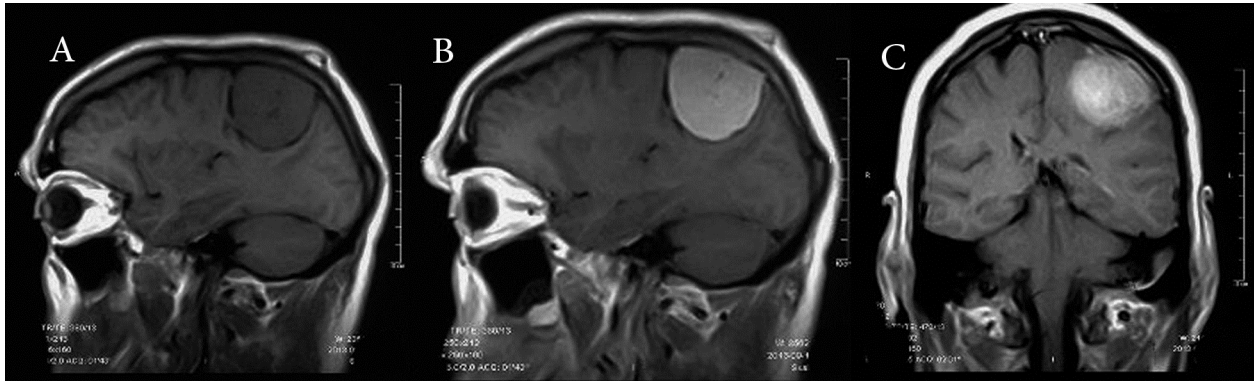
**Table 1** Literature review of postoperative HSV encephalitis

Author and year	Age/Sex	Kind of Operation	Symptoms	Confirming Test Result	Treatment	outcome
R. Filipo et al. 2005	33/male	Resection of acoustic neuroma	Strong headache, impairment of consciousness and hypertonia of arms and legs	Positive PCR HSV 1 DNA of CSF	High dose antiviral therapy	
Raper DM et al. 2011	65/female	C2-C5 laminectomy for spinal ependymoma resection	fever, vomiting and rapid decline in mental status	Positive PCR HSV 1 DNA of CSF	High dose antiviral therapy	Discharged after VP shunting and placing PEG and tracheostomy
Kwon JW et al. 2008	13/female	surgery for craniopharyngioma	rapid deterioration in mental status	Positive PCR HSV 1 DNA of CSF	High dose antiviral therapy	She recovered and could speak short sentences, but dysphasia and right hemiparesis remained
A Spuler et al. 1999	78/female	removal of a meningioma	difficulties talking and counting while playing cards, followed by several focal motor seizures involving first the right face and later the arm and leg	Positive PCR HSV 1 DNA of CSF	High dose antiviral therapy	Died nine days after the onset of symptoms
S Aldea et al. 2003	28/male*	Removal of a right frontocingular oligodendroglioma.	fever, rightsidehemiparesis, meningeal syndrome, and mild motor aphasia	Anti-HSV-IgG and IgM level	High dose antiviral therapy	Full recovery after one year
Bourgeois et al. 1999	8/male**	Left amygdalohippocampectomy for intractable complex partial seizure	Severe clinical deterioration with partial status epilepticus, aphasia and hyperthermia	Positive PCR HSV 1 DNA of CSF	High dose antiviral therapy	Full recovery
Jalloh et al. 2009	44/male	Acoustic neuroma	Pyrexia, vomiting, confusion	Positive PCR HSV 1 DNA of CSF	High dose antiviral therapy	Good recovery
Kim et al. 2013	11/male***	Epilepsy surgery for intractable seizure for 6 years	Fever and confusion	Positive PCR HSV 1 DNA of CSF	High dose antiviral therapy	Normal recovery one month after being discharged
Hon Tang et al. 2013	29/F	Right sided micro vascular decompression for trigeminal neuralgia	Fever, headache and confusion	Positive PCR HSV 1 DNA of CSF	High dose antiviral therapy	Good recovery after 2 weeks
*Possible episode of viral encephalitis in 1995						
**The patient had previously contracted HSV 1 meningo-encephalitis at the age of 16 months						
***Past medical history of HSV encephalitis at the age of five						

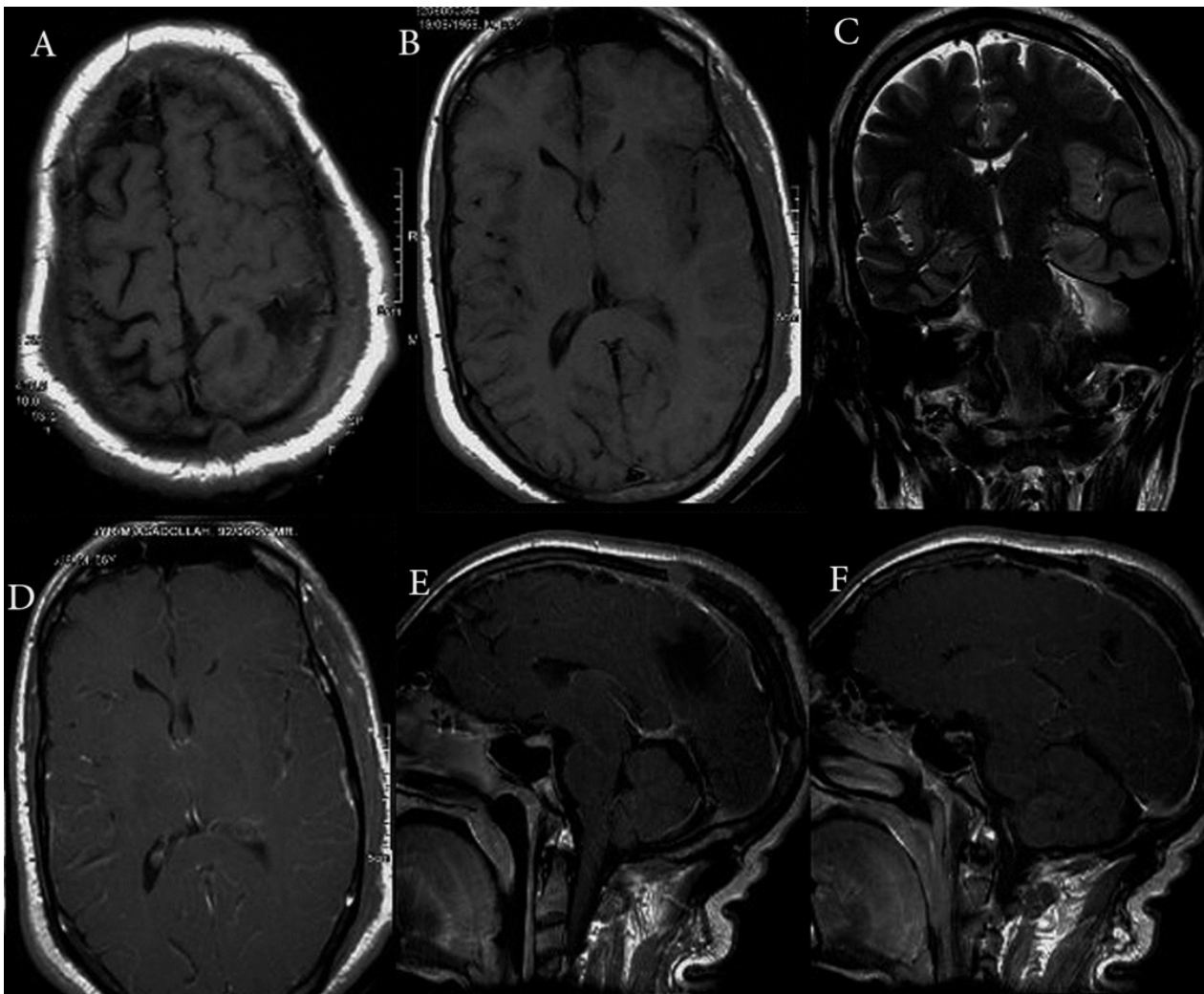
In this study we represent a rare case of HSV encephalitis. After diagnosing convexity meningioma in a 55-year-old man, the patient underwent uneventful surgery for the removal of meningioma (**Figure 1**).

The patient was awoken and was responsive after the surgery. The appearance of a high grade fever (40°C) and altered consciousness and spastic quadriparesis complicated

the post-operative course 48 hours after surgery. Neurological exam was done, but there was not any specific finding. Laboratory findings were normal. The brain MRI detected brain abnormalities on the fourth day after the onset of symptoms, signal changes in left insula and temporal lobe and also in both sides of basal ganglia were detected as a sign of infarction (**Figure 2**).



**Figure 1** Pre-operative: MRI of the Brain showing the mass studied



**Figure 2** Post-operative: Magnetic resonance imaging of the brain reveals, signal changes in the left insula and temporal lobe and also in both sides of basal ganglia as a sign of infarction

Real-time Polymerase chain reaction identification of HSV 1 DNA by DNA extraction in the CSF sample confirmed the diagnosis. A positive prognosis was achieved due to the decision to start specific, high-dose antiviral therapy based on clinical suspicion, before a firm diagnosis was established. (30

mg/kg/day intravenous Acyclovir) Treatment with acyclovir was maintained for 8 weeks but unfortunately the patient died after severe sepsis.

## Discussion

*Herpes simplex virus-1* is the most common cause of lethal sporadic encephalitis. HSV-1 encephalitis is associated with persistent severe neurological deficits, although improved therapy with intravenous acyclovir has been adopted recently [2-4]. Encephalitis caused by HSV is not common. In fact the estimated incidence, derived from large series, is 2 to 4 cases per million populations per year [10]. The differential diagnosis of HSV encephalitis is extensive [11]. It includes such infectious conditions as bacterial abscess, empyema, listeriosis, mycobacterial infection, fungal infection (especially *Cryptococcus*), parasitic infection (toxoplasmosis, amoebic infection), other viral infections (*Epstein-Barr virus*, *lymphocytic choriomeningitis virus*, *influenza virus*, *enterovirus*, *rabies*, *subacute sclerosing panencephalitis*, *arboviruses*, *adenovirus*, *rubella virus*), and noninfectious conditions such as vascular malformations, tumors, and Reye syndrome [10,12]. This wide range of possibilities makes it impossible to treat empirically without more definitive diagnostic evaluations.

It has also been mentioned that postoperative infections that occur as complications of neurosurgical procedures are originally bacterial and include meningitis, subdural empyema, and cerebral abscess [2]. It has also been proven that HSV infection has a genetic immune etiology in which a deficiency exists in a protein or a toll-like receptor that helps mediate an immune response [3].

Finally it can be said that there are only few case reports of postoperative HSV 1 encephalitis. These reports suggest that this rare postoperative complication is associated with a poor prognosis, with high mortality and morbidity. Neurosurgical interventions involving peripheral nerve root or ganglia have been reported to cause reactivation of cutaneous *herpes simplex* infection. Factors compromising the immune system may also increase susceptibility to herpes infection, so does previous HSV infection.

## Conclusion

To conclude, the most significant factor affecting the HSV encephalitis outcome is starting effective antiviral treatment as early as possible [13]. Although HSV encephalitis is rare, mortality rates reach 70% in the absence of therapy and only a minority of individual's return to normal functions. So considering the possibility of HSV encephalitis in case of decreased level of consciousness and high grade fever after neurosurgical operations is logical. Owing to the life-threatening nature of the disease, if there is a delay in diagnostic test results therapy should not be withheld until they become available. It means empirical acyclovir treatment is strongly recommended when encephalitis is suspected [4,14]. After the completion of therapy, PCR of the CSF can confirm the elimination of replicating virus, aiding further management of the patient. Unfortunately, despite all the improvements in the diagnosis and treatment of this disease, but there is still many failures. Actually, about 30% of patients with HSV encephalitis result in poor prognosis [15,16].

## Conflict of Interest

All authors certify that they have NO affiliations with or involvement in any organization or entity with any financial interest, or non-financial interest in the subject matter or materials discussed in this manuscript.

"There is no funding or conflict of interest"

"There are no financial disclosures"

## References

- Lund M (2011) Herpes simplex virus reactivation and encephalitis after topectomy. *J Pediatr Health Care* 25: 323-327.
- Aldea S, Joly LM, Roujeau T, Oswald AM, Devaux B (2003) Post-operative herpes simplex virus encephalitis after neurosurgery: case report and review of the literature. *Clin Infect Dis* 36: e96-e99.
- Casrouge A, Zhang SY, Eidenschenk C, Jouanguy E, Puel A, et al. (2006) Herpes simplex virus encephalitis in human UNC-93B deficiency. *Science* 314: 308-312.
- Tunkel AR, Glaser CA, Bloch KC, Sejvar JJ, Marra CM, et al. (2008) The management of encephalitis: clinical practice guidelines by the Infectious Diseases Society of America. *Clin Infect Dis* 47: 303-327.
- Yamada S, Kameyama T, Nagaya S, Hashizume Y, Yoshida M (2003) Relapsing herpes simplex encephalitis: pathological confirmation of viral reactivation. *J Of Neurol Neurosurg Psychiatry* 74: 262-264.
- Mckendall RR (1989) Herpes simplex virus infections of the nervous system. *Handbook of clinical neurology Revised series* 12: 207-227.
- Whitley RJ (1990) Viral encephalitis. *N Engl J Med* 323: 242-250.
- Jhun P, Bright A, Herbert M (2014) Don't let herpes melt your brain. *Annals of Emergency Medicine* 64: 589-590.
- Jones CA, Isaacs D (2004) Management of herpes simplex virus infections. *Current Paediatr* 14: 131-136.
- Skoldenberg B, Forsgren M, Alestig K, Bergstrom T, Burman L, et al. (1984) Acyclovir versus vidarabine in herpes simplex encephalitis - Randomised multicenter study in consecutive Swedish patients. *Lancet* 2: 707-711.
- Kohl S, James AR (1985) Herpes simplex virus encephalitis during childhood: Importance of brain biopsy diagnosis. *J Pediatr* 107: 212-215.
- Whitley RJ, Soong SJ, Linneman C Jr, Liu C, Pazin G, et al. (1982) Herpes simplex encephalitis. *Clinical Assessment. JAMA* 247: 317-320.
- Kimberlin DW (2007) Management of HSV encephalitis in adults and neonates: Diagnosis, prognosis and treatment. *Herpes : The Journal of the IHMF* 14: 11-16.
- Steiner I, Budka H, Chaudhuri A, Koskiniemi M, Sainio K, et al. (2010) Viral meningo-encephalitis: a review of diagnostic methods and guidelines for management. *Eur J Neurol* 17: 999-957.
- Kamei S, Sekizawa T, Shiota H, Mizutani T, Itoyama Y, et al. (2005) Evaluation of combination therapy using aciclovir and

corticosteroid in adult patients with herpes simplex virus encephalitis. *J Neurol Neurosurg Psychiatry* 76: 1544-1549

encephalitis in adult patients: results of a multicenter study. *Clin Infect Dis* 35: 254-260.

16. Raschilas F, Wolff M, Delatour F, Chaffaut C, De Broucker T, et al. (2002) Outcome of and prognostic factors for herpes simplex