

Respiratory Arrest Following Foreign Body Aspiration in Achalasia: A Case Report

Saad Khan^{1,2},
Rex Shih-Chia Huang³,
Nuha Khan⁴ and
Danae Papachristos⁵

Keywords: Foreign body aspiration, achalasia

Case Report

An 84-year-old man presented with acute respiratory distress thought secondary to aspiration pneumonia. Although limited to a seated study, a recent barium swallow showed esophageal dilatation associated with low amplitude tertiary waves. This was secondary to a tight and smooth narrowing in the distal esophagus consistent with achalasia [1] (**Figure 1a**).

Pulse oximetry on a fraction of inspired oxygen of 21% showed a reduced saturation of peripheral oxygen at 86%. Respiratory examination revealed reduced air entry at the right base, but no stridor. Chest X-ray did not reveal any abnormalities. His respiratory status deteriorated despite appropriate antimicrobial, anti-inflammatory and bronchodilator therapy.

Bronchoscopy was performed due to a high clinical suspicion of foreign body aspiration and this showed a tablet in the right main bronchus (**Figure 1b**) that disintegrated on attempted retrieval. Following the procedure the patient required invasive ventilation via tracheostomy and was eventually palliated following discussion with family. Significant complications of foreign body aspiration in adults have been reported, including obstructive pneumonitis, atelectasis, bronchiectasis and lung abscess [2]. Although rare, achalasia has a well-recognized association with foreign body aspiration [3-5] and a high index of suspicion is required to ensure appropriate management.

- 1 Department of Gastroenterology, Peninsula Health, Frankston, Victoria, Australia
- 2 Department of Medicine, Austin Health, Heidelberg, Victoria, Australia
- 3 Department of Medicine, Royal Melbourne Hospital, Parkville, Victoria, Australia
- 4 Faculty of Medicine, Nursing and Health Sciences, Monash University, Clayton, Victoria, Australia
- 5 Department of Medicine, St Vincent's Hospital, Fitzroy, Victoria, Australia

Corresponding Author: Saad Khan

Department of Gastroenterology, Peninsula Health, Frankston, Victoria, Australia, Tel: 61 403 798 622

Tel: 61 403 798 622

✉s.khan23@hotmail.com

Citation: Khan S, Huang RS, Khan N, Papachristos DA. Respiratory Arrest Following Foreign Body Aspiration in Achalasia: A Case Report. Arch Med. 2015, 7:3.

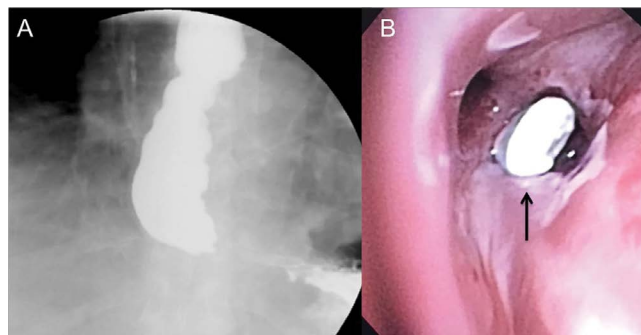


Figure 1A and 1B (1A) Distal esophagus consistent with achalasia.; (1B) Bronchoscopy.

References

- 1 Vaezi MF, Pandolfino JE, Vela MF (2013) ACG clinical guideline: diagnosis and management of achalasia. *Am J Gastroenterol* 108: 1238-1249.
- 2 Chen CH, Lai CL, Tsai TT, Lee YC, Perng RP (1997) Foreign body aspiration into the lower airway in Chinese adults. *Chest* 112: 129-133.
- 3 Marom EM, McAdams HP, Erasmus JJ, Goodman PC (1999) The many faces of pulmonary aspiration. *AJR Am J Roentgenol* 172: 121-128.
- 4 Franquet T, Giménez A, Rosón N, Torrubia S, Sabaté JM, et al. (2000) Aspiration diseases: findings, pitfalls, and differential diagnosis. *Radiographics* 20: 673-685.
- 5 Limper AH, Prakash UB (1990) Tracheobronchial foreign bodies in adults. *Ann Intern Med* 112: 604-609.