

Sonographic Reference Luminal Diameter of the Abdominal Aorta among Subjects in Nigeria

Michael S Okpaleke¹,
Valentine C Ikamaise²,
Michael P Ogolodom^{1*},
Julius Agbo³, Awajimijan
N Mbaba⁴, Kester
Egwuanmku⁵, Oluwafemi O
Egbeyemi⁶ and Uche N Eja-
egwu¹

Abstract

Background: There are no local baseline reference values to aid accurate ultrasound diagnosis of risk factors of cardiovascular diseases and abdominal aortic aneurysm in Abuja, Nigeria.

Objective: To develop normal reference values for luminal diameter of the abdominal aorta in Abuja, Nigeria.

Materials and Methods: The luminal diameters of the abdominal aorta (AA) of 422 male and female healthy subjects were measured sonographically using standard protocol. The relationship between age, body mass index (BMI), gender and the luminal diameter of the AA were investigated in the subjects. Statistical analysis was performed by the student T-test and Pearson's correlation coefficient at 5% level of significance.

Results: The values of the luminal diameter of the AA in the healthy subjects were 15.16 ± 0.55 mm in males and 15.15 ± 0.55 mm in females respectively. The 5th and 95th percentile normal reference limits of the AA were 14.20 mm and 16.10 mm respectively. There were no significant differences in the luminal diameter measurements in male and female subjects. Age correlated significantly with luminal diameter ($r=0.90$) of the AA in both gender. BMI showed weak significant correlation with luminal diameter ($r=0.136$) of the AA in female healthy subjects only.

Conclusion: The normal reference values for luminal diameters of the abdominal aorta for male and female healthy subjects have been established in this study. Age is the only significant independent predictor of the luminal diameter of the AA.

Keywords: Aorta; Luminal diameter; Ultrasonography; Reference level; Age

- 1 Department of Radiography, NnamdiAzikiwe University Awka, Nnewi Campus, Nigeria
- 2 Department of Radiography & Radiological science, University of Calabar, Nigeria
- 3 Department of Radiography, University of Nigeria, Enugu Campus, Nigeria
- 4 Rivers State University Teaching Hospital, Port Harcourt, Rivers State, Nigeria
- 5 General Hospital Kwale, Delta State, Nigeria
- 6 Department of Radiography and Radiation Sciences, Ajayi Crowther University, Oyo State, Nigeria

***Corresponding author:**

Michael Promise Ogolodom

✉ mpos2007@yahoo.com

Tel: +234803997393

Department of Radiography, Nnamdi Azikiwe University Awka, Nnewi Campus, Nigeria.

Citation: Okpaleke MS, Ikamaise VC, Ogolodom MP, Agbo J, Mbaba AN (2020) Sonographic Reference Luminal Diameter of the Abdominal Aorta among Subjects in Nigeria. Health Sci J. Sp. Iss 2: 005.

Received with Revision December 02, 2020, **Accepted:** December 16, 2020, **Published:** December 21, 2020

Introduction

The abdominal aorta (AA) is the largest artery in the body with normal diameter of approximately 20 mm, which supplies oxygenated blood to major abdominal organs such as the liver, spleen, gonads, diaphragm and pelvis [1]. Aortic diameter changes with age and is characterized by gradual widening of the lumen due to weakening of the aortic wall [2]. An abnormally dilated aorta occurs when the diameter of the abdominal aorta exceeds 3.0 cm in overall diameter [3,4] and being at least one and half times the suprarenal aortic diameter [5,6] Focal dilatation of the aorta is referred to as aortic aneurysm and rupture of an abdominal aortic aneurysm can lead to death within minutes as approximately 90% of patients die before reaching the operating room [7].

Assessment of the luminal diameter of the abdominal aorta

can be achieved with Ultrasound. This has the advantage of being cheap, readily available, sensitive and non-invasive [8,9]. Moreso, it has been documented that ultrasound is the reference imaging technique for screening including patients

with aortic abnormalities [10,11]. Other imaging modalities such as Computed Tomography Angiography (CTA) and Magnetic Resonance Angiography (MRA) are currently being used in the estimation of abdominal aortic diameter. However, CTA and MRA are expensive and not readily available in remote locations in developing countries like Nigeria.

The prevalence of abdominal aortic abnormalities such as aneurysm is increasing in sub-Saharan Africa especially in Nigeria where several cases has been diagnosed with associated high mortality [12]. A good knowledge of the normal luminal diameter of the abdominal aorta is a prerequisite for the recognition and diagnosis of aortic abnormalities such as abdominal aortic aneurysm AAA and stenosis. There are no local baseline reference values to aid accurate diagnosis and identification of people at high risk of complication of abdominal aortic abnormalities such as aneurysm [13-16]. The objective of this study is therefore to develop local reference baseline values of the normal abdominal aortic dimensions in Abuja, Nigeria and thus provide the basis for identifying people at risk of aortic abnormalities.

Materials and Methods

Four hundred and twenty-two (422) healthy adult volunteers age between 18-89 years domiciled in Abuja were enlisted into the study between February 2012 and March 2018 using purposive sampling. Ethical approval was obtained from the Research and Ethics Committees of the College of Medicine, University of Nigeria, Enugu campus and the Medic Aid Radio-diagnostic centre Abuja. Informed consent from the subjects was also obtained. Only consenting healthy volunteers without any clinically and/or laboratory confirmed cardiovascular risk factors were included in the study while subjects with history of cardiovascular diseases, and those with history of aneurysms were excluded. Anthropometric parameters namely height was obtained using a metal tape, weight was obtained using a weighing scale, age was obtained from the date of birth or certificate of birth of the subjects and body mass index was computed as the ratio of weight (kg) to height (m²).

Afterwards, the ultrasonography evaluation of the AA was performed by two experienced sonographers on the enlisted subjects who have fasted for 10-12 hours. Mindray ultrasound equipment (4D ultrasound, model - DCN3; year of manufacture-2013) was used for the measurement. Scanning was performed from the level of the diaphragm to the level of bifurcation of the AA at L₄ where measurements were made (Figure 1).

An Antero-posterior (AP) measurement of the Luminal diameter (LD) was then made at 90° to the longitudinal axis of the AA from a longitudinal frozen image on arrested respiration. This allowed correct placement of the callipers at the long axis of the vessel to avoid parallax error. Luminal diameter was measured by placing callipers at opposite ends of the inner walls of the lumen of the AA. The mean of two luminal diameter measurements was recorded (Figure 2). The following precautions were taken in order to obtain image of diagnostic quality in obese subjects and subjects with excessive bowel gas. Application of gentle pressure on the abdomen over areas with poor sonographic contrast and

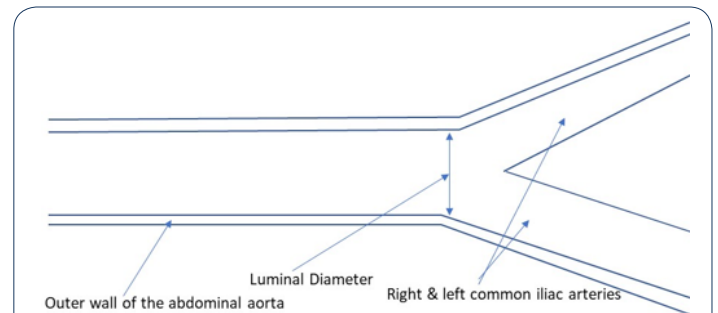


Figure 1 Schematic Diagram for the measurement of the Luminal Diameter of the Abdominal Aorta.

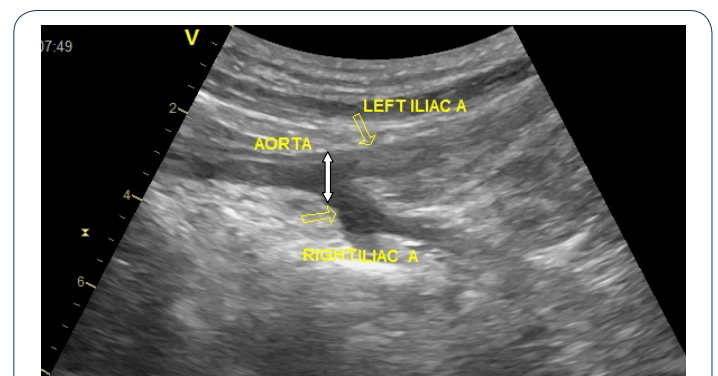


Figure 2 Sonograph showing the longitudinal measurements of luminal diameter of the abdominal aorta in healthy subjects (up-down arrow).

some of the subjects were made to turn from the supine position to the lateral decubitus position to dispel bowel gas [16]. The luminal diameters in male and female healthy subjects were analysed using SPSS package version 23. Descriptive statistics was performed. Student's t- test tool was used to compare variable and Percentile values were used to obtain lower and upper limits of luminal diameter of the abdominal aorta. The Pearson's correlation coefficient was used to obtain the association between age, body mass index, gender and the luminal diameter of the abdominal aorta.

Results

The results showed that values of the luminal diameter of the AA in the healthy subjects were 15.16 ± 0.55 mm in males and 15.15 ± 0.55 mm in females respectively (Table 1). The 5th and 95th percentile normal reference limits of the AA obtained were 14.20 mm-16.10 mm respectively (Table 2). There were no significant differences in the luminal diameter measurements in male and female subjects (Table 3). Age correlated significantly positively with luminal diameter ($r=0.90$) of the AA in both gender. BMI showed weak significant correlation with luminal diameter ($r=0.136$) of the AA in female healthy subjects under study (Table 4).

Discussion

In this study, 422 subjects were recruited, which consisted of 211 male healthy subjects representing 50% of the studied population and 211 female subjects also representing another 50% of the

Table 1 Variations in Luminal diameter of male and female subjects.

Age range (years)	Luminal Diameter in Male Subjects (mm)		Luminal Diameter in Female Subjects (mm)		T-test
	Range	Mean ± SD	Range	Mean ± SD	
18-32	14.01-14.40	14.97 ± 0.27	14.00-14.40	14.28 ± 0.14	0.869
33-47	14.20-15.20	14.97 ± 0.27	14.20-15.20	14.96 ± 0.28	0.908
48-62	15.21-15.40	15.31 ± 0.88	15.20-15.40	15.31 ± 0.085	0.726
63-77	15.40-16.40	15.50 ± 0.29	15.40-16.40	15.52 ± 0.33	0.618
78-92	15.52-16.50	15.89 ± 0.40	15.50-16.50	15.84 ± 0.38	0.874
Total		15.16 ± 0.55		15.15 ± 0.55	0.931

*significant mean difference at $p < 0.05$

Table 2 The Percentile values of Abdominal Aorta diameter in healthy subjects.

Parameter	Mean (SD)	Percentile range in healthy subjects						
		5	10	25	50	75	90	95
LD (mm)	15.16 ± 0.55	14.200	14.300	14.875	14.200	14.400	15.500	16.100

*n=number

Table 3 Age, BMI and Gender distribution of the Subjects.

Age range	Male subjects				Female subjects			
	*n	Age(years)	BMI		*n	Age (years)	BMI	
		mean	Range	mean		mean	range	Mean
18-32	(37)	25.54 ± 4.63	16.58-32.90	26.07 ± 3.37	(37)	25.54 ± 4.63	20.20-36.90	25.73 ± 4.06
33-47	(52)	40.19 ± 4.54	14.80-33.31	24.01 ± 4.50	(53)	40.22 ± 4.50	14.80-32.83	24.79 ± 4.45
48-62	(58)	34.22 ± 3.79	19.85-42.40	27.31 ± 4.75	(57)	54.31 ± 3.77	17.90-42.40	27.21 ± 5.05
63-76	(33)	68.30 ± 4.40	23.23-45.20	29.43 ± 5.75	(34)	69.21 ± 4.33	20.70-45.20	28.05 ± 5.27
78-90	(31)	82.65 ± 3.19	23.20-38.20	27.20 ± 3.23	(30)	82.63 ± 3.25	20.90-30.10	25.80 ± 2.28
Total	(50)	52.27 ± 19.02	14.80-45.20	26.59 ± 4.79	(50)	52.15 ± 18.94	14.80-45.20	26.59 ± 4.80

Table 4 Relationship between Age, Body Mass Index and Luminal Diameter.

Parameters	Luminal diameter	
	Male	Female
Age (r)	0.902	0.899
Body mass index (r)	0.214	0.136*

*significant mean difference at $P < 0.05$. r = Pearson's correlation coefficient

studied population thereby giving a male to female ratio of 1:1.

The normal mean value of the luminal diameter in the present study is 15.16 ± 0.55 mm in males and 15.15 ± 0.55 mm in females (**Table 1**). The upper and lower normal reference limits were 14.20 mm-16.10 mm representing the 5th and 95th percentiles respectively (**Table 2**). These are similar to the aortic diameter measurements reported in another Nigerian population [13] but higher than the values reported in a related study in a Sudanese population [17]. Usman et al. [18] reported a mean transverse infra-renal outer to outer abdominal aorta diameter of 16.3 ± 2.3 mm although the AA was measured using the outer to outer method instead of the inner to inner method used in the present study. The reference values in the present study were less than that reported in healthy African - American population and other Caucasians in the multi-ethnic study of atherosclerosis (MESA) [19] but higher than the measurements obtained in an Indian population [20] using computed tomography. The MESA study reported that the abdominal aortic diameter of African Americans was smaller than those of other Caucasians. The fact

that ultrasound measurements consistently underestimates aortic size up to 5mm compared to computed tomography measurements [21] implies that ultrasound equivalent of the computed tomography measurements will be much higher especially in Caucasians. Recent studies however suggest that there were no significant differences in abdominal aortic diameter measurements between computed tomography and ultrasonography [22]. The differences between the present study and the previous studies were attributed to differences in levels of measurement, methodology and racial factors [19,23]. These regional and racial differences therefore suggest that genetic and racial factors play important roles in influencing abdominal aorta diameter. Also, another factor responsible for the widening of the abdominal aorta in the population was age. In the present study, we observed that the abdominal aorta increased in thickness with age and were more pronounced in subjects above 48 years with maximum luminal diameter dilatation seen in subjects above 90 years of age (**Table 3**). The luminal diameter of the AA also widened with increasing age in both male and female healthy subjects. This was depicted by the strong positive correlation and association between age and luminal diameter measurements (**Table 4**). These findings have been collaborated by related studies [17,20]. Therefore, increasing age especially old age seem to play a role in abdominal aorta dilatations and stiffness. Healthy male subjects have statistically non-significant wider luminal diameter than healthy female subjects (**Table 1**). Other related studies have also found significant differences in the abdominal aorta diameters of male and female subjects contrary

to the findings of the present study [8,17]. The differences between the earlier studies and the present study are attributed to differences in methodology. The fact that the widening of luminal diameter in both gender occurred simultaneously implies that the development of aortic atherosclerotic lesions which is a risk factor of cardiovascular disease may predispose both male and female adult's subjects in the locality to early onset of cardiovascular diseases and aneurismal dilatations.

Body mass index showed weak association with luminal diameter of the abdominal aorta in both male and female healthy subjects (Table 4) and this has been collaborated by related studies [18]. There were significant mean differences in the body mass index and luminal diameter in female subjects but not in male subjects (Table 4). This implies that BMI is an important factor to consider in the clinical evaluation of luminal dilatations of the AA in female subjects in the present study. This agrees with the findings of another related study which documented that the indices of body size such as height, weight and BMI influences abdominal aorta diameter more in female subjects than in male subjects [24]. Another study opined that body mass index is significantly associated with increases in abdominal aorta

diameter in both male and female subjects at the bifurcation level of the abdominal aorta by ultrasound unlike in the present study where we observed weak positive correlation between luminal diameter of the abdominal aorta and body mass index with significant correlations seen only in female subjects.

The difference between the result of the present study and earlier studies may be attributed to race and environmental factors. Age and BMI significantly and collectively predicted widening of the luminal diameter in healthy volunteer subjects by 81% ($R^2=0.811$) by multiple regression analysis. However, only age remained the single independent predictor of AA luminal dilatations ($\beta=0.594$) in stepwise regression analysis.

Conclusion

The normal reference values for luminal diameters of the abdominal aorta in the locality were 15.16 ± 0.55 mm in males and 15.15 ± 0.55 mm in females. Age is the only significant independent predictor of the luminal diameter of the AA. The luminal diameter for males and females is presented as the reference values for sonographic scans in the population of study.

Conflict of Interest: Non-declared.

References

- Hussain AY, Dakpa T, Fardous M, Melo F, Matinez F, et al. (2018) Role of ultrasound in the diagnosis of abdominal aortic aneurysm. *EC Cardiology* 5: 955-968.
- Schlatmann TIM, Becker AR (1977) Histologic changes in the normal aging aorta: implication for dissecting aortic aneurysm. *Am J Cardiol* 39: 13-21.
- Leopold GR (1970) Ultrasonic abdominal aortography. *Radiology* 96: 9-14.
- Webster MW, Ferrel RE, St Jean PL, Majumder PP, Forgel SR, et al. (1991) Ultrasound screening of first-degree relatives of patients with an abdominal aortic aneurysm. *J Vasc Surg* 13: 9-14.
- Cronenwett JL, Murphy TF, Zelenek GB, Whitehouse Jr WM, Lindenauer SM, et al. (1985) Actuarial analysis of variables associated with rupture of small abdominal aortic aneurysm. *Surgery* 98: 472-483.
- Lederle FA, Walker JM, Rainke DB (1988) Selective screening for abdominal aortic aneurysms with physical and ultrasound. *Arch Intern Med* 148: 1753-1756.
- Brown LC, Powell JT (1999) Risk factors for aneurysm rupture in patients kept under ultrasound surveillance. UK small aneurysm trial participants. *Ann Surg* 230: 289-296.
- Mbaba AN, Ogolodom MP, Abam R, Nengi A, Chiegwu HU, et al. (2019) Ultrasonographic and Retrograde Urethrographic Assessment of Aetiological Factors of Bladder Outlet Obstruction in Adult Males in Port Harcourt, Nigeria. *Health Sci J* 13:680.
- Dance DR, Christofides S, Maldment ADA, Mclean ID, Ng KN (2014) Diagnostic radiology physics: A handbook for teachers and students. International atomic energy agency, Vienna.
- Moll FL, Powell JT, Fraedrich G, Verzini F, Haulon S, et al. (2011) Management of Abdominal Aortic Aneurysms Clinical practice guidelines of the European Society for Vascular Surgery. *Eur J Vasc Endovasc Surg* 41: S1-S58.
- Becker F, Baud JM (2006) Screening for abdominal aortic aneurysms and monitoring of small abdominal aortic aneurysms: arguments and recommendations from the French society of vascular medicine: Final report. *J Vas Dis* 31:260-276.
- Ogunleye EO, Adekola OO, Dada OI (2019) Aortic aneurysm: A life-threatening condition in a low-resource nation. *J Clin Sci* 16: 15-19.
- Dokunmu T, Yakubu OF, Adebayo AF, Oleshinde GI, Chinedu SW (2018) Cardiovascular risk factor in suburban community in Nigeria. *Int J Hypertens* 2018: 527-533.
- Chinakwana GU, Odike MAC, Nwafor AME (2014) Problems and prospects of managing thoracic aortic aneurysm at NnamdiAzikiwe University Teaching Hospital, Nnewi Nigeria. *World J Surg* 28: 288-290.
- OgberaAO, Ekpebegh C (2014) Diabetes Mellitus in Nigeria: The past, present and future. *World J Diabetes* 5: 905-911.
- Reardon RF, Clinton ME, Madore F, Cook TP (2014) Abdominal aortic aneurysm. In: Ma O, Mater JR, Reardon RF, Joing SA (Editors). *Emergency ultrasound* (3rd edn). New York; McGraw – Hill.
- Gameraddin M (2019) Normal abdominal aorta diameter on abdominal sonography in healthy asymptomatic adult: the impact of age and gender. *J Radiat Res Appl Sci* 12: 186-191.
- Usman BO, Lawal S, Ibinaiye PO, Chom ND, UmarA (2014) Determination of normal supra and Infra Renal aortic diameter on ultrasound in Zaria, Nigeria. *West Afr J Ultrasound* 15:1-24.
- Laughlin GA, Allison MA, Jensky NE, Aboyans V, Wong ND, et al. (2011) Abdominal aortic diameter and vascular atherosclerosis: The Multi-Ethnic Study of Atherosclerosis. *Eur J Vasc Endovasc Surg* 41: 481-487.
- Jasper A, Harshe G, Keshava SN, Kulkarni G, Stephen E, et al. (2014) Evaluation of normal abdominal aortic diameters in the Indian population using computed tomography. *J Postgrad Med* 60: 57-60.
- Chiu K, Lung L, Tripathi V, Ahmed M, Shrivastira V (2014) Ultrasound measurement for abdominal aortic aneurysm screening; a direct

- comparison of three leading leading methods. *Eur J Vasc Endovasc Surg* 47:367-373.
- 22 Liisberg M, Diederichsen AC, Lindholt JS (2017) Abdominal ultrasound scanning versus non-contrast computed tomography screening method for abdominal aortic aneurysm- a validation study from the randomized DANCAVAS study. *BMC Medical Imaging* 17.
- 23 Tarnoki AD, Tarnoki DL, Littvay L, Garami Z, Karlinger K, et al. (2016) Genetic and environmental effects on the abdominal aortic diameter development. *Arq Bras Cardiol* 106: 13-17.
- 24 Lo RC, LU B, Fokkema M, Conrad M, Patel V, et al. (2014) Relative importance of aneurysm diameter and body size for predicting abdominal aortic aneurysm rupture in men and women. *J Vasc Surg* 59:1209-1206.