

DOI: 10.21767/2386-5180.1000129

The Gold Miners Neuroretinitis

Saidatul Akma Sharif, Mohanarasan Ratanam and Nurliyana Ain Abdul Ghani

Ophthalmology Department, Sultan Haji Ahmad Shah Hospital, Temerloh, Pahang, Malaysia

Corresponding author: Mohanarasan Ratanam, Ophthalmology Department, Sultan Haji Ahmad Shah Hospital, Temerloh, Pahang, Malaysia, Tel: 60 9-295 5333; E-mail: mohanslayer@gmail.com

Received: 07 October 2016; **Accepted:** 10 October 2016; **Published:** 14 October 2016

Citation: Sharif SA, Ratanam M, Abdul Ghani NA. The Gold Miners Neuroretinitis. Ann Clin Lab Res. 2016, 4: 4.

Case Blog

Objective

To describe the potential hazards to traditional gold miners without personal protective equipment in the gold mines of Raub district, Pahang, Malaysia.

Case Summary

A 21 years old traditional gold miner presented with fever and subsequently seizures for a week duration. Clinical examinations and lab investigations led to a diagnosis of Leptospirosis Meningitis and the gentleman was treated with intravenous Amoxy-Clavulanic Acid. During the course of treatment, the gentleman noticed progressive blurring of vision of the left eye.

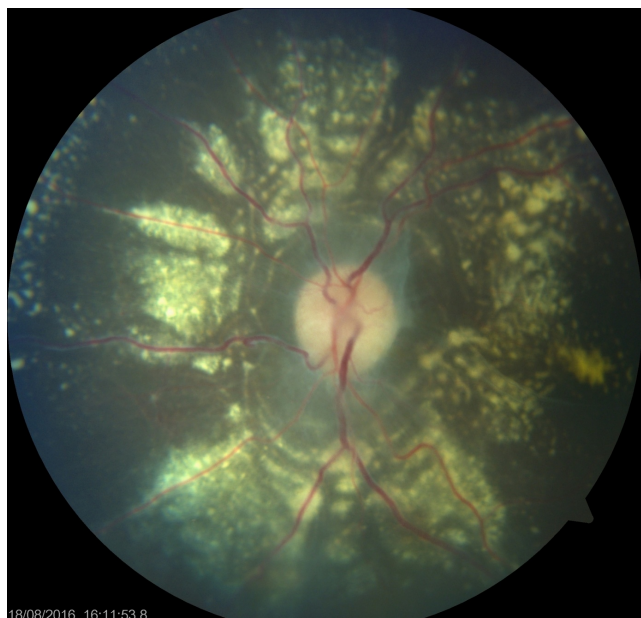


Figure 1 Fundus photograph of the left eye showing gross optic disc swelling and extensive choroiditis in a radius around the optic disc.

Visual acuity when first examined was 6/60 with fundus examination showing gross optic disc swelling with extensive choroiditis forming a perfect radius surrounding the optic disc. A diagnosis of neuroretinitis secondary to Leptospirosis was made and oral Doxycycline was given. Once the infection was under control oral Prednisolone was started to keep retinal inflammation at bay (**Figure 1 and Figure 2**).

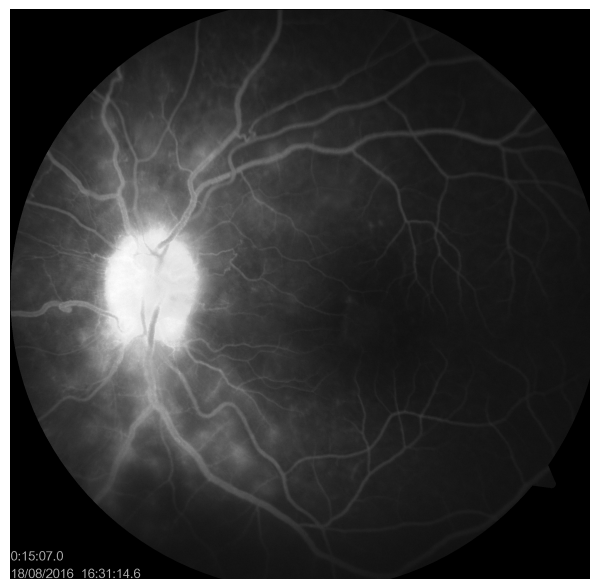

Figure 2 Fundus photograph of the left eye of the same patient in the early venous phase of fluorescein angiography. There are numerous choroiditic lesions seen as subretinal blots in this photograph. The retinal vessels appears intact with no signs of leakages.

Conclusion

Traditional gold mining remains an important source of income in some parts of the world such as in the Raub district of Pahang, Malaysia. These miners are exposed to infectious diseases such as Leptospirosis in this case due to the lack of awareness in using proper personal protective equipments.