

DOI: 10.21767/2171-6625.1000118

The Role of Peritumoral Perfusion Values in Differentiation of Multicentric Glial Tumors and Cranial Metastasis

Kaan Meric, Ceren Yalnız, Hasan Gundogdu, Sibel Aydın, Zeynep Gamze Kılıçoglu and Mehmet Masum Simsek

Haydarpaşa Numune Training and Research Hospital Radiology, Tibbiye, Uskudar/Istanbul, Turkey

Corresponding author: Ceren Yalnız, Haydarpaşa Numune Training and Research Hospital Radiology, Tibbiye Cad. No: 23 34668 Uskudar/Istanbul, Turkey, Tel: 00905057084210; Fax: 00902163360565; E-mail: cerenyalniz@gmail.com

Received: May 19, 2016; **Accepted:** Jun 27, 2016; **Published:** Jun 30, 2016

Abstract

Introduction: Although MRI is the primary modality in the diagnosis of cranial metastasis, advanced MRI techniques such as spectroscopy, perfusion, diffusion weighted imaging, and diffusion tensor imaging are used to distinguish cranial metastasis from other pathologies. Since cranial metastasis are often highly vascular lesions, on perfusion examination they tend to exhibit elevated cerebral blood volume (rCBV). However since high-grade glial tumors also exhibit elevated rCBV, perfusion imaging cannot accurately differentiate between these two groups. Peritumoral rCBV values are actually more reliable in differential diagnosis of multicentric glial tumors and cranial metastasis.

Case report: A fifty-six-year-old male presented with progressive weakness in his left arm. MRI revealed multiple, different-sized lesions with a wide range of intensity changes. Some of the lesions displayed substantial peritumoral vasogenic edema. On DWI sequences, lesions demonstrated peripheral restricted diffusion. MRP sequences didn't show elevated rCBV values in T2-hyperintense peritumoral edema areas. The excisional biopsy of the lesion in left occipital lobe performed and the lesion's pathology result was reported as small-cell lung carcinoma metastasis, supporting our primary radiologic diagnosis.

Discussion: Advanced MRI techniques such as perfusion, spectroscopy, diffusion-weighted imaging (DWI) and diffusion tensor imaging (DTI) are used in the context of distinguishing cranial metastasis from high-grade glial tumors. Perfusion parameters like rCBV and rCBF are important to distinguish metastatic lesions from cranial lymphoma and benign cranial masses like abscess. However, since both cranial metastasis and high-grade glial lesions are both hypervascular, comparison of rCBV of the enhancing component of lesions cannot differentiate between these two groups. In such cases, rCBV values obtained from the peritumoral T2 hyperintense edema component of the lesion can help us.

Conclusion: Multicentric glial tumors are on the differential diagnosis list of cranial metastasis. When

conventional MRI techniques are insufficient to differentiate these two entities, perfusion values obtained from the peritumoral edema areas might be helpful.

Keywords: Cranial metastasis; Magnetic resonance perfusion; rCBV; rCBF

Introduction

Although magnetic resonance imaging (MRI) is the primary modality in the diagnosis of cranial metastasis, advanced MRI techniques such as magnetic resonance spectroscopy (MRS), magnetic resonance perfusion (MRP), diffusion weighted imaging (DWI), and diffusion tensor imaging (DTI) are used to distinguish ambiguous cranial metastasis from other pathologies. Since cranial metastasis are often highly vascular lesions, on MRP examination they tend to exhibit elevated cerebral blood volume (rCBV) compared with contralateral normal white matter. However since high-grade glial tumors also exhibit elevated rCBV, perfusion imaging cannot accurately differentiate between these two groups. Peritumoral rCBV values are sometimes more reliable in differential diagnosis of multicentric glial tumors and cranial metastasis.

Case Report

A fifty-six-year-old male presented with progressive weakness in his left arm. Cranial computed tomography (CT) scans revealed multiple cerebral and cerebellar hypodense cystic lesions. The biggest one on the right hemisphere was 18 × 20 mm, located subcortically in the parietal lobe and the biggest one on the left hemisphere was 40 × 42 mm, located cortically and subcortically in the occipital lobe.

MRI revealed infra/supratentorially located multiple, different-sized lesions with a wide range of intensity changes on T1 (**Figure 1**) and T2-weighted images (**Figure 2**). Some of the lesions displayed substantial peritumoral edema. On DWI sequences, lesions demonstrated peripheral restricted diffusion (**Figure 3**).

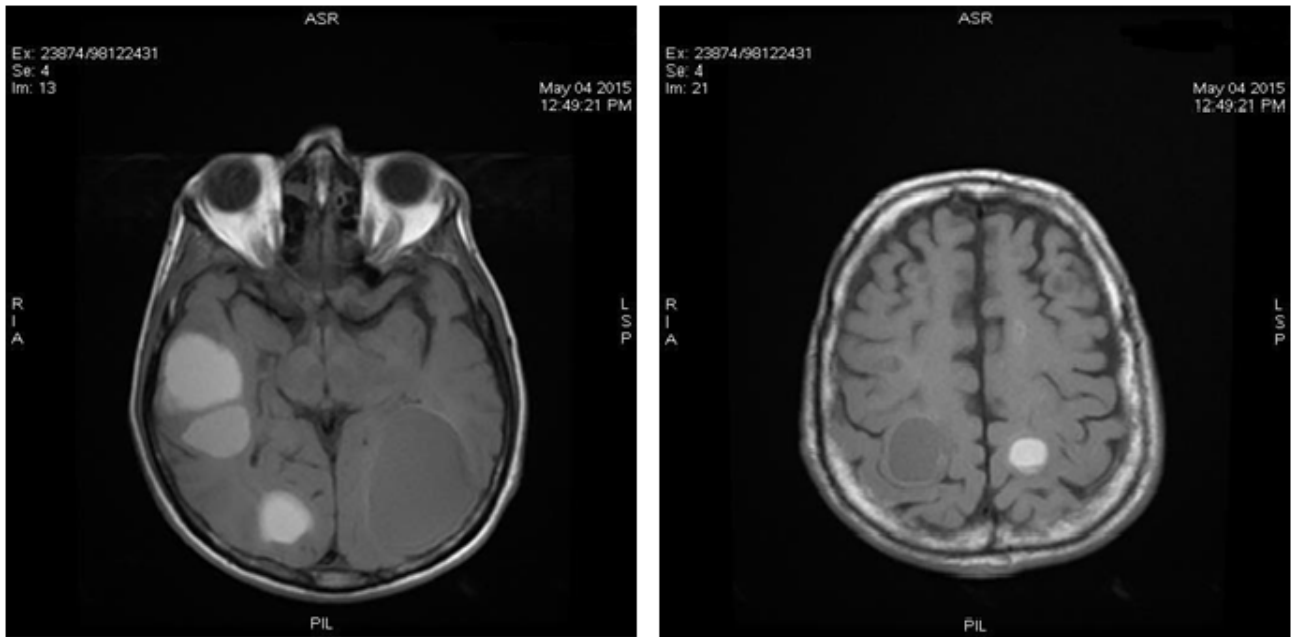


Figure 1 Infra/supratentorially located multiple, different-sized lesions with a wide range of intensity changes on T1 weighted images.

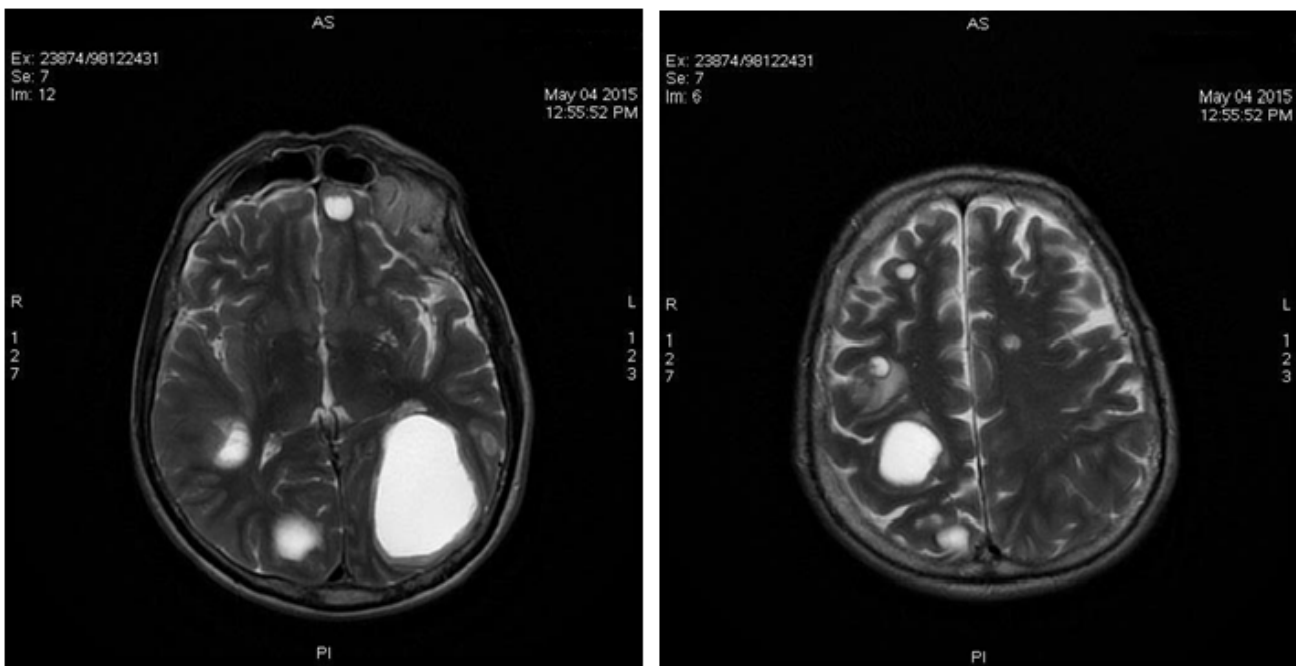


Figure 2 Infra/supratentorially located multiple, different-sized lesions with a wide range of intensity changes on T2 weighted images.

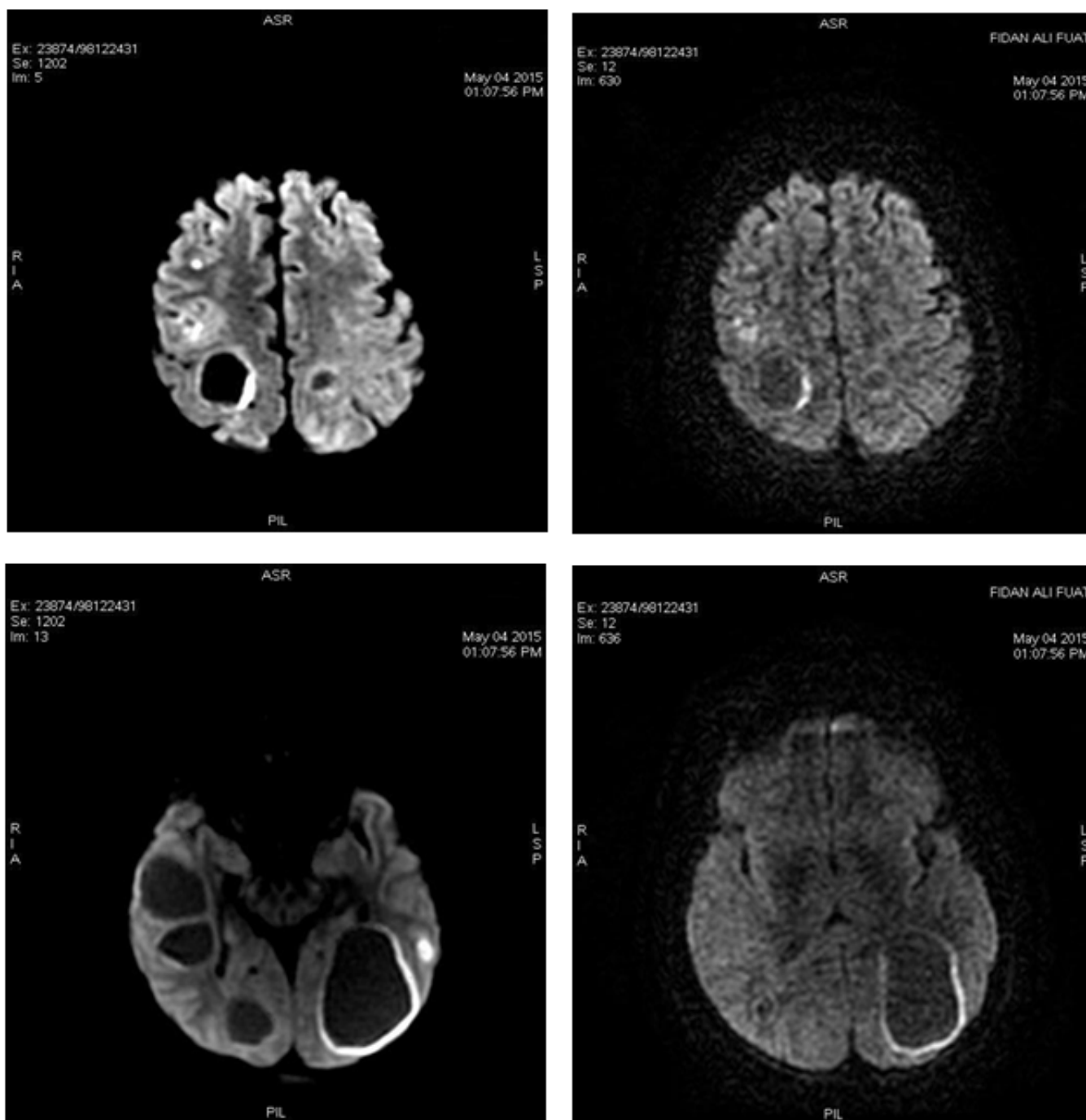


Figure 3 On DWI sequences, lesions demonstrated peripheral restricted diffusion.

MRP sequences didn't show elevated rCBV and cerebral blood flow (rCBF) values in T2-hyperintense peritumoral edema areas, compared with contralateral normal white matter.

Maximum rCBV values were 3.94 in the peritumoral area of the left occipital lesion and 3.09 in the contralateral normal-appearing white matter (**Figure 4**). Maximum rCBV value obtained from the peritumoral area around the right parietal lesion was 2.19 whereas rCBV value of the contralateral normal-appearing white matter was 2.64 (**Figure 5**).

Maximum rCBF values were 9.05 in the peritumoral area of the left occipital lesion and 9.17 in the contralateral normal-appearing white matter (**Figure 6**). Maximum rCBF value obtained from the peritumoral area around the left occipital lesion was 4.80 whereas rCBV value of the contralateral normal-appearing white matter was 6.56 (**Figure 7**).

DTI sequences showed that the lesions pushed the adjacent tracts without any sign of invasion (**Figure 8**). Since the patient didn't cooperate with the investigation, MRS imaging couldn't be performed.

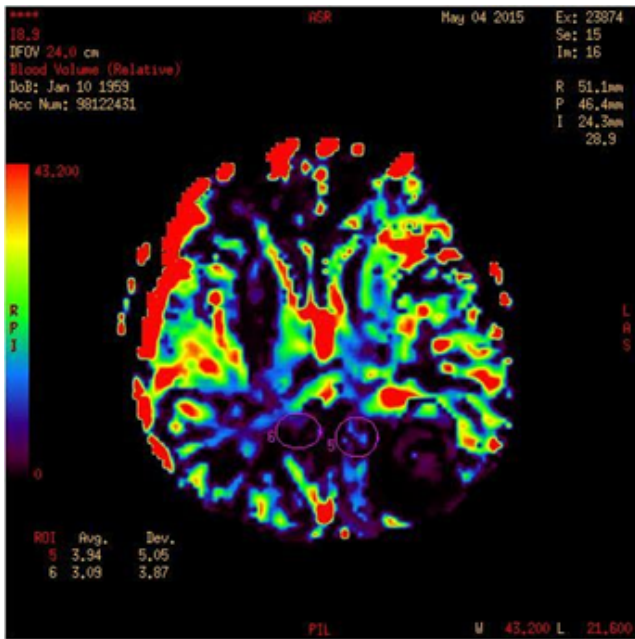


Figure 4 Maximum rCBV values were 3.94 in the peritumoral area of the left occipital lesion and 3.09 in the contralateral normal-appearing white matter.

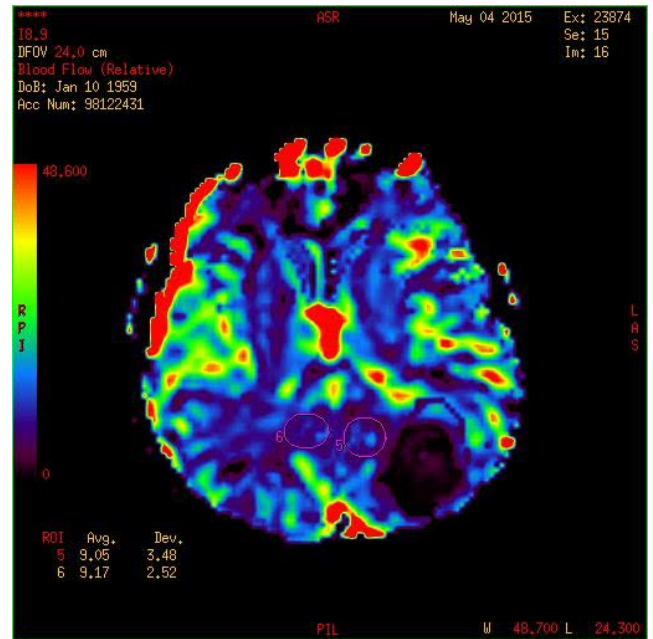


Figure 6 Maximum rCBF values were 9.05 in the peritumoral area of the left occipital lesion and 9.17 in the contralateral normal-appearing white matter.

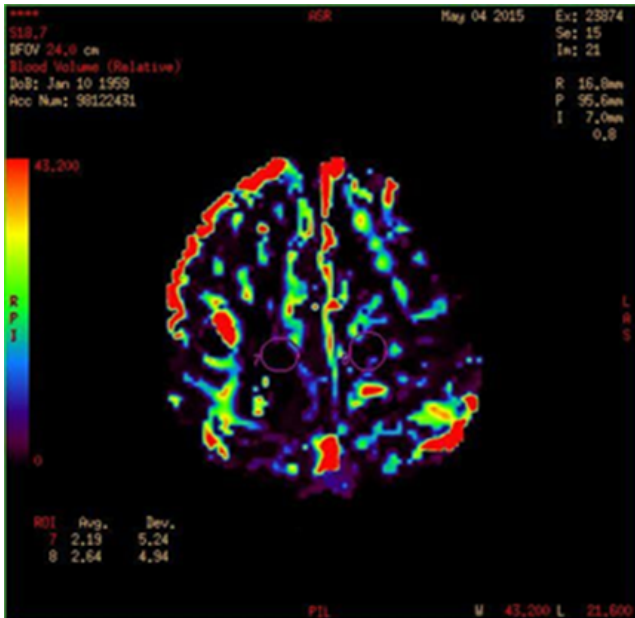


Figure 5 Maximum rCBV value obtained from the peritumoral area around the right parietal lesion was 2.19 whereas rCBV value of the contralateral normal-appearing white matter was 2.64.

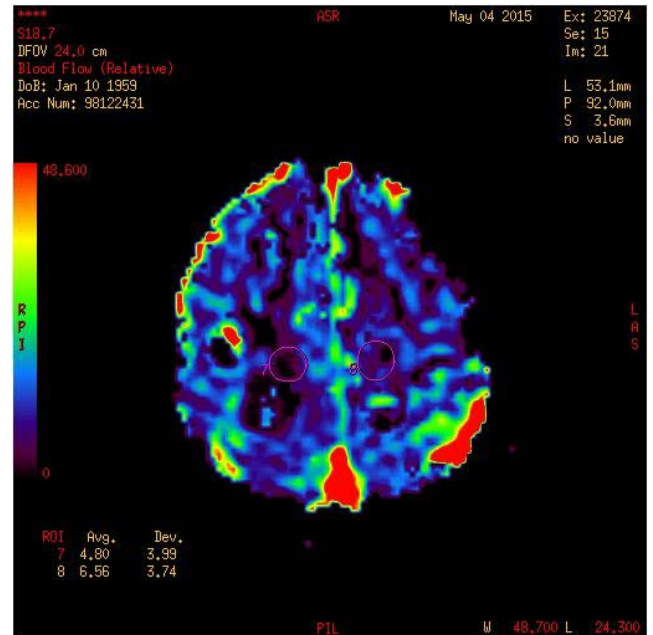


Figure 7 Maximum rCBF value obtained from the peritumoral area around the left occipital lesion was 4.80 whereas rCBV value of the contralateral normal-appearing white matter was 6.56.

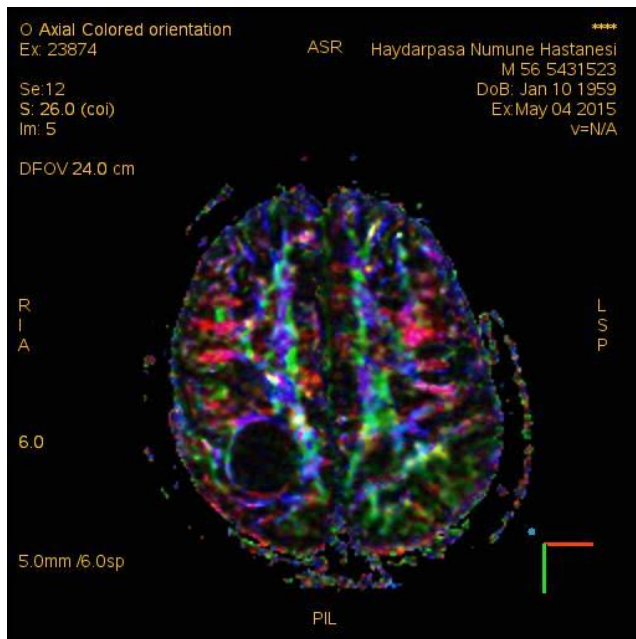


Figure 8 DTI sequences showed that the lesions pushed the adjacent tracts without any sign of invasion.

The excisional biopsy of the lesion in left occipital lobe was performed and the lesion's pathology result was reported as small-cell lung carcinoma metastasis, supporting our primary radiologic diagnosis.

Discussion

MRI is the primary modality used for the detection of cranial metastasis. However, conventional MRI is usually insufficient for the differentiation between high-grade glial tumors and cranial metastasis. Conventional MRI sequences provide information about the anatomic and morphological aspects of the lesions. Chemical composition, characteristics and effects in the adjacent tissues are important to distinguish metastasis from glial tumors. These aspects can only be generated by advanced MRI sequences.

Advanced MRI techniques such as perfusion, spectroscopy, diffusion-weighted imaging (DWI) and diffusion tensor imaging (DTI) are used in the context of distinguishing cranial metastasis from high-grade glial tumors [1]. In perfusion imaging the volume of blood passing through a portion of the brain is measured. In other words perfusion-weighted imaging provides noninvasive measurements of tumor vascularity and identifies areas of neovascularization. As a brain tumor outgrows its blood supply, it induces angiogenesis; as a result, perfusion values are elevated.

Perfusion parameters like rCBV and rCBF distinguish metastatic lesions from cranial lymphoma and other benign cranial masses such as abscess. Whereas cranial metastasis show elevated perfusion parameters as a result of high vascularisation due to tumoral neoangiogenesis, abscess demonstrates decreased rCBV and lymphoma demonstrates

lower rCBV values compared to glial tumors and metastasis [2]. However, since both cranial metastasis and high-grade glial lesions are both hypervascular, comparison of rCBV of the enhancing component of lesions cannot differentiate between these two groups [3-5]. In such cases, rCBV values obtained from the peritumoral T2 hyperintense edema component of the lesion can help us. Peritumoral signal represents interstitial water due to blood-brain barrier breakdown and capillary permeability changes. At pathologic examination, the peritumoral areas of primary high-grade gliomas contain infiltrating tumor cells in addition to interstitial water. However, the peritumoral area of metastasis doesn't demonstrate tumoral infiltration [6,7]. Due to infiltrative nature of high-grade glial neoplasms, peritumoral rCBV values in glial tumors are higher than the peritumoral rCBV values of cranial metastasis. The peritumoral hypoperfusion in metastases is thought to be due to absence of tumor cells, mass effect of vasogenic peritumoral edema and cerebral blood flow reduction in edematous areas [8,9].

Conclusion

Multicentric glial tumors are on the differential diagnosis list of cranial metastasis. When conventional MRI techniques are insufficient to differentiate these two entities, perfusion values obtained from the peritumoral edema areas might be helpful.

References

1. Fink KR, Fink JR (2013) Imaging of brain metastases. *Surgical Neurology International* 4: S209-S219.
2. Wetzel SG, Cha S, Johnson G (2002) Relative cerebral blood volume measurements in intracranial mass lesions: interobserver and intraobserver reproducibility study. *Radiology* 224: 797-803.
3. Bendini M, Marton E, Feletti A, Rossi S, Curtolo S, et al. (2011) Primary and metastatic intraaxial brain tumors: prospective comparison of multivoxel 2D chemical-shift imaging (CSI) proton MR spectroscopy, perfusion MRI, and histopathological findings in a group of 159 patients. *Acta Neurochir (Wien)* 153: 403-412.
4. Calli C, Kitis O, Yuntun N, Yurtseven T, Islekel S, et al. (2006) Perfusion and diffusion MR imaging in enhancing malignant cerebral tumors. *Eur J Radiol* 58: 394-403.
5. Wong JC, Provenzale JM, Petrella JR (2000) Perfusion MR imaging of brain neoplasms. *AJR Am J Roentgenol* 14: 1147-1157.
6. Meng Law, Soonmee Cha, Edmond AK, Johnson G, Arnett J, et al. (2002) High-grade gliomas and solitary metastases: Differentiation by using perfusion and proton spectroscopic MR imaging. *Radiology* 222: 715-721.
7. Burger P (1990) Classification, grading, and patterns of spread of malignant gliomas. In: Apuzzo ML, (ed). *Neurosurgical topics: malignant cerebral glioma*. Park Ridge, Ill: American Association of Neurological Surgeons 3-17.
8. Chiang IC, Kuo YT, Lu CY, Yeung KW, Lin WC, et al. (2004) Distinction between high-grade gliomas and solitary metastases using peritumoral 3-T magnetic resonance spectroscopy, diffusion, and perfusion imaging. *Neuroradiology* 46: 619-627.

9. Sugo N, Harada N, Yokota K, Miyazaki C, Ohtsuka T, et al. (2003) Determination of peritumoral hypoperfusion volumes surrounding brain tumors using three-dimensional spect. *CI Kenkyu* 25: 77-85.