

# Wound Curing Prospective of Copper (II) Bis[N' - ((5-Chloro-1H-Indol-3-yl Methylene Nicotino)hydrazide)] on Experimentation Provoke Cutting Out Injury in Rats

Morvarid Rahnama<sup>1</sup>, Nura Suleiman Gwaram<sup>2</sup>, Ibrahim Abdel Aziz Ibrahim<sup>3</sup>, Naiyer Shahzad<sup>3</sup>, Saeed S Al-Ghamdi<sup>3</sup>, Nahla Ayoub<sup>3</sup>, Nazia Abdul Majid<sup>3</sup>, Wijenthiran Kunasekaran<sup>4</sup>, Mahmood A Abdulla<sup>5</sup> and Nur'ain Salehen<sup>5\*</sup>

<sup>1</sup>Institute of Biological Sciences, Faculty of Science, University of Malaya, 50603 Kuala Lumpur, Malaysia

<sup>2</sup>Department of Chemistry, Faculty of Natural and Applied Sciences, Umaru Musa Yar'adua University, Katsina, Katsina State, Nigeria

<sup>3</sup>Department of Pharmacology and Toxicology, Faculty of Medicine, Umm al-Qura University, Makkah, Saudi Arabia

<sup>4</sup>CytonexSdn. Bhd. CytonexSdn. Bhd. A-16-17 Lvl 16 Menara UOA Bangsar, No.5 Jalan Bangsar Utama 59000, Kuala Lumpur, Malaysia

<sup>5</sup>Department of Biomedical Science, Faculty of Medicine, University of Malaysia, 50603 Kuala Lumpur, Malaysia

\*Corresponding author: Nur'ain Salehen, Department of Biomedical Science, Faculty of Medicine, University of Malaysia, 50603 Kuala Lumpur, Malaysia, Tel: 0060196634810; E-mail: [morvarid.rahnama@gmail.com](mailto:morvarid.rahnama@gmail.com)

Received January 15, 2018; Accepted January 21, 2018; Published January 27, 2018

## Abstract

Copper (II) Schiff base derived regularly utilized for healing of various disarray. The aspire of existing learn was to look into the consequence of Schiff base imitative on injury curative in rodents. Injure therapeutic activity of Cl-indole-nicotinic was check via stipulate the proportion of cut closing following contemporary appliance of the composite. Four collections of mammal were luxury correspondingly with CMC 2%, Intrasite gel, 20 and 40 mg/ml compound for 10 days appraise gross necropsy, histology and endogenous enzymes parameters of wound's sites. The outcome designates the emotional capability of Cl-indole-nicotinic in tissue renewal and remedial the wounded skin. Gross appearance on day 5 and day 10 affirmed that the complex extensively hasten the velocity of injure repairing. Histological studies indicated the small blood capillaries expansion and increase deposition of collagen configuration in addition to decline in provocative cells in compound extravagance cluster contrast to control set. Masson Trichrome showed well organized collagen fibers in treated wounds. Furthermore, the multipart characterized dosage needy raise action of superoxide dismutase (SOD) along with lipid peroxidation enzyme-malondialdehyde (MDA) lessening in granulation tissue homogenate. In finale, lesion curative capacity of composite may perhaps point to improve collagen evidence in granulation tissue as well as increased SOD antioxidant and reduced MDA level in wound homogenate.

**Keywords:** Cl-indole nicotinic; Wound healing; Gross; Histology; SOD; MDA

## Introduction

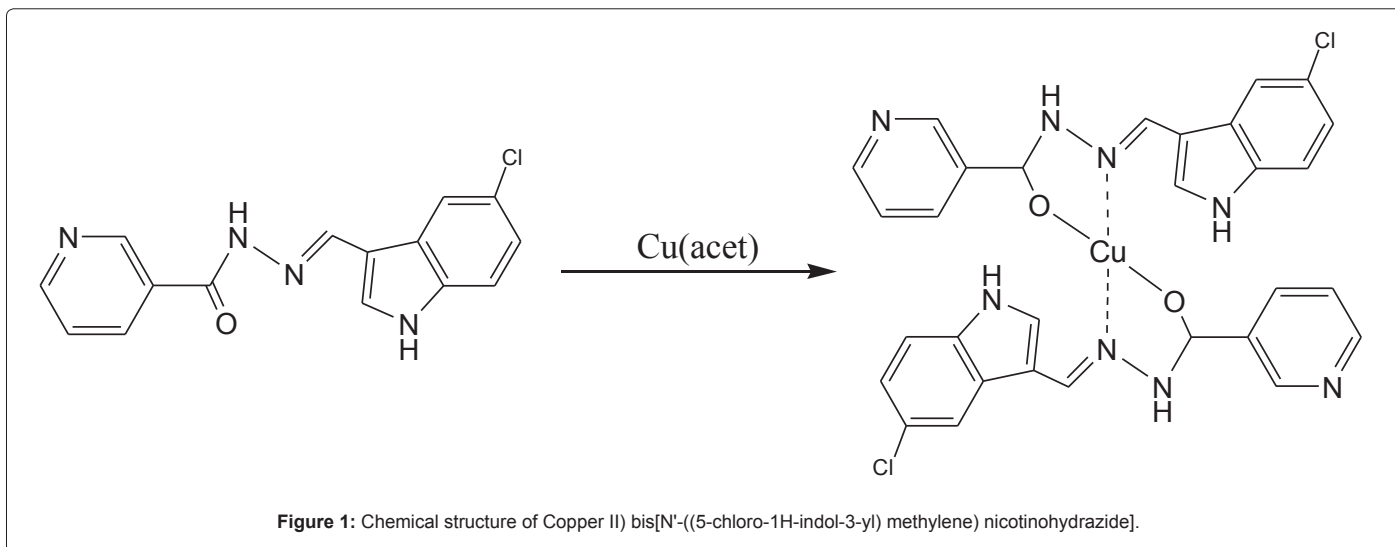
Injuries were by means of human race since the establishment of the past. Abundant pursue in addition to hard work contain been completed to recommend the injure concern and encourage management which are employed today [1]. Several deliberate or unplanned substantial disturbances in reliability and efficient organization of the skin is described abrasion or injury. Wounds grounds incise and hole of great division of the skin, the crucial protection fence in opposition to some outside mediator, which fallout in active purpose insufficiency, disability, and fatality in patients [2]. Hurt repairing procedure is considered as sequence of consecutive physiological proceedings initiated by means of granulation and trimmings in scar development [3]. In extremely prearranged method, little imperative in order phase of renovate take place in a injured position counting inflammation (0-3 days), cellular propagation (3 h 12 days), and refashion (3-6 months) [4]. The "repaired sore" refers to damage in which the connective tissue has entirely revamped along with reepithelialization created, and tissue recovered its anatomic construction and action devoid of involving identification and covering any longer [5]. Full restore to health is merely realized while the disturbed tissue is preserved by collagen [6]. In traditional medicine, information of manufactured complexes has been reported by several researchers for the therapy of wounds [7-10]. A lot of revisions have been assessed the beneficial appliance of a variety of metal-ligand complexes and Schiff base derived for a variety of disorders [11-15]. Cell passage inhibitory possible of Schiff base-Cu(II) multipart creation of benzyl dithiocarbazate and acetylpyridine

[16] physically powerful anti-cancer action of a novel Schiff base copper multifaceted [17,18]. In current study, Cl-indole-nicotinic includes chemical purposeful nicotino)hydrazide and indole faction, wherever nicotinic acid in addition to nicotinamide are conventional substance utilized in remedy, with their extraordinary antibacterial range [19]. Carboxylic acid hydrazides and their resultant have applied to resolve ecological harms in expertise as well as chemistry [20]. Indole consequential as well disclose antioxidant and antiulcer prospective; anticancer. No available data were found about this compound. Therefore, the present work was designed to figure out the activity of the compound on injury curing and histology of granulation tissue in animal representation.

## Methods

### Synthesis of copper (II) bis[N-((5-chloro-1H-indole-3-yl)methylene) nicotino)hydrazide]

Nicotinic acid hydrazide (0.0035 mol) was precisely calculated on a digital sense of balance within 100 ml beaker as well as liquefied in acidified alcohol (50 mL) as well 5'-chloro indole-3- carboxaldehydes (0.0035 mol) was deliberated in an additional beaker and soften with acidified ethanol (50 mL) the two solutions were mix up into a 500 mL flat bottom flask and put in a agitator. The flat bottom flask was after that hold tightly on a water bath and refluxed on a stirring hot plate for 2 hours which gave yellow impulsive which is filtered addicted to a conical flask moreover the yellow solid was re-crystallized in Ethanol to pale yellow crystals. To the produced ligand was supplementary a solution of copper (II) acetate tetrahydrate (0.007 mol) in a smallest amount quantity of water. The resultant solution was refluxed for 5 hours followed by re-crystallized in DMSO (Figure 1).



## Wound curing study

**Intrasite gel:** Intrasite gel was acquired from Pharmacy and employed as positive control [21].

**Laboratory animals:** Mature male rats were taken from the investigational animal quarters. This trial was agreed by the Ethics board {Ethic No. PM 21/03/2016 MR (R)}. The animals were separated arbitrarily into 4 clusters of 6 rats [22]. Every one standard heaviness flanked by 240-280 g and was residence singly. The rodents were sustained on ordinary diet and tap water. Every single one obtained human being concern based on the standard delineate in the "Direct for the Care plus employ of Experimental Animals" organized via the Countrywide College of Sciences and Available via the Nationwide Institution of Healthiness.

**Induction of injury:** The rats were sedated by means of Ketamine and Xylazine. The skin clipped with electrical cutter, sterilized with 70% Absolute alcohol. A region of identical 2.00 cm in width on the upper collar of every rat was stained utilizing a circle close and the cutting out persuaded [23]. The skin reserved stable throughout method and wound area was calculated instantly after wound formation via insertion a visible drawing paper in excess of the cut and outlining it out. The marking out paper afterward located on mill metric diagram page, the squares were calculated, and the vicinity was evidence as explained by Abdulla et al. [24].

**Topical application of wounds:** Injuries of cluster 1 were indulgence by 0.2 ml CMC 2% (w/v), two times per day, and marker as negative control set [25]. Cut of collection 2 were extravagance with 0.2 ml of Intrasite gel, two times daily, served as remedy cluster. Additionally, injuries of faction 3 and 4 were treated with 0.2 ml of 20 mg/ml and 40 mg/ml of compound twice a day, correspondingly [22].

**Abrasions closing evaluation:** The assessment of cut close up vicinity of every rat were evaluated via outlining the injury on day 5 and 10 after injuries employing clearness paper and a stable indicator beneath low dosage of ketamine and xylazine anesthesia as illustrated by Abood et al. [4]. The verification lesion regions were calculated utilizing a grid paper. The proportion of gash repairing on desired day was resolute [9].

**Histology of injury tissues:** Sampling of injured district was detached on day 10 after give up of rats, in addition to fix in 10%

buffered formalin and process by tissue dealing out apparatus (Leica Microsystems, Wetzlar, Germany). Slices of 5  $\mu$  thickness were blemish by means of Hematoxyline and Eosin, as well as Masson's trichrome stain. MT marked the collagen fiber in granulation tissue with bluish green color under light microscopy [26].

**Wound tissue homogenate:** Wounded areas 10% (w/v) was arranged in ice-cold 50 mM phosphate buffer (pH 7.4) including a mammalian protease inhibitor cocktail. Tissue homogenate arranged by aid of teflon homogenizer device. Suspension afterward spine in 4°C, 3500 rpm, 20 minutes, in addition to the supernatant was employed to appraise antioxidant action and lipid peroxidation intensity [27].

**Superoxide dismutase:** SOD action of the cut homogenate in granulation tissue was assessing employing commercial kits (Cayman Chemical Co., Ann Arbor, MI, USA). The produce trials were exercised for the verification of behaviors in wound tissue supernatant of every test [11].

**Malondialdehyde:** Lipid peroxidation level of wound homogenate was deliberated the malondialdehyde (MDA) applying marketable kits (Cayman Chemical Co.) according to manufacture instruction [28].

**Statistical data study:** Whole data were evaluated by means of One-Way ANOVA in SPSS and stated as mean  $\pm$  S.D. significance of  $p < 0.05$  were believed arithmetical considerable.

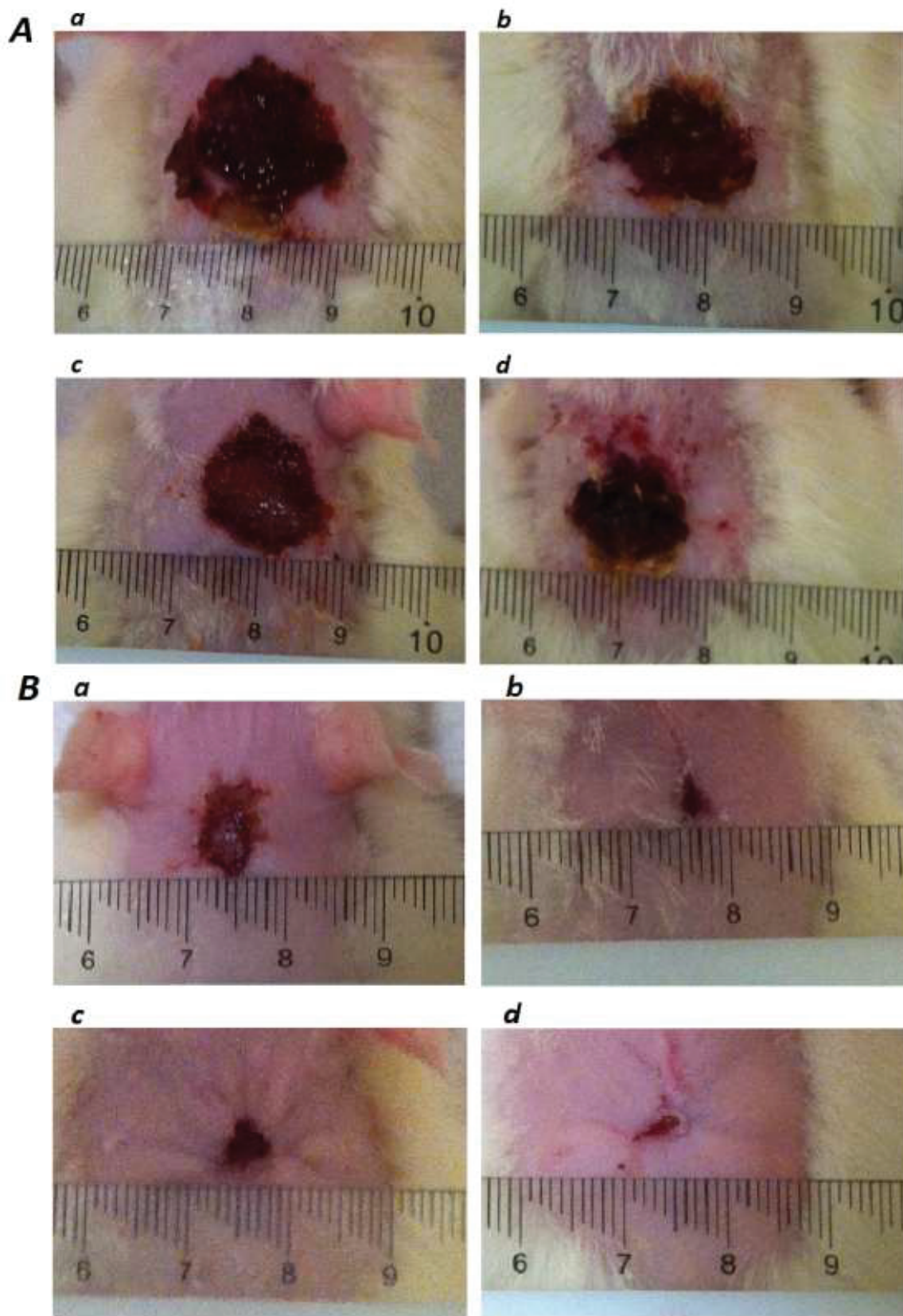
## Results

Cl-indole-nicotinic effect on wound closure measurement macroscopically

Gross assessment confirmed that injuries extravagance with 0.2 ml of 20 mg/ml and 40 mg/ml Cl- indole-nicotinic, or by Intrasite gel, reproduced appreciably decrease wound area as well as substantial symbols of repairing with quicker enclosed space than negative control wounds. Cl-indole-nicotinic luxury wounds have extensively lesser abrasion vicinity on day 10 post-wounding of curing, judge against to negative control cluster (Figures 2 and 3) (There were no major variation involving hurt treated with compound as well as 2 and 3).

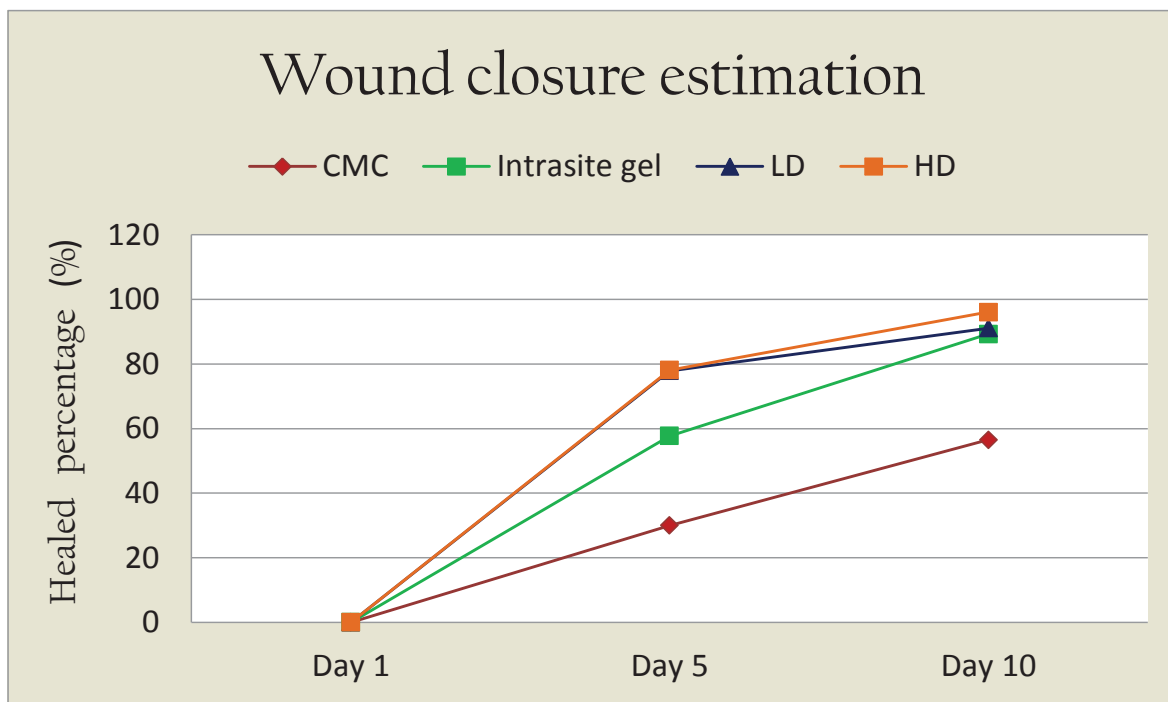
Effect of Cl-indole-nicotinic on histology of wound are and granulation tissue on day 10 post- surgery:

**H&E stain:** Wounds dressed with Cl-indole-Nicotinic or intrasite



**Figure 2:** Effect of Cl-indole-Nicotinic on gross manifestation of excision cut remedial region on day 5 (A) and day 10 (B) post-wounding. a) 0.2 mL of CMC; b) 0.2 mL Intrastite; c) 0.2 mL of 20 mg/ml of Cl-indole-Nicotinic; d) 0.2 mL of 40 mg/ml of Cl-indole-Nicotinic.





**Figure 3:** Mean  $\pm$  S.E.M. of percentage of wound healing in rats after treatment with CMC, Intrasite gel, Cl-indole-Nicotinic (20 mg/ml), and Cl-indole-Nicotinic (40 mg/ml).

gel were evidently smaller wound area compared to those treated with negative control (Figure 4). The granulation tissues demonstrated remarkably fewer inflammatory cells, and extra fibroblast, collage and angiogenesis comparatively to wound luxury by 2% CMC (Figure 5).

**Masson's trichrome stain:** In CMC indulgence injure, the collagen were exemplify with reduced direction in addition to disorganize. There were more inflammatory cells with less fibroblast and collagen fibers in granulation tissue. On the other hand Cl-indole-Nicotinic treated wound illustrated obviously improved the evidence fibroblast, collagen fibers and angiogenesis in granulation tissue which were analogous with intrasite gel (Figure 6).

**Effect of Cl-indole-nicotinic on the SOD activity in wound tissue homogenate:** Wounds topically applied with Cl-indole-nicotinic or intrasitegel significantly increased the well-known action of SOD in wound tissue homogenate compared to CMC-treated wounds (Figure 7A). The considerable elevated in SOD activity emerge self defensive technique to encourage the hurt curing practice in rodents.

**Effect of Cl-indole-nicotinic on lipid peroxidation level (MDA) in wound tissue homogenate:** Wounds dressed with Cl-indole-nicotinic or intrasite gel established considerable reduction of MDA in wound tissue homogenate contrast to vehicle treated wounds (Figure 7B). This outcome powerfully proposes attenuated lipid peroxidation in hurt position of rats.

## Discussion

Rats topically dressed with Cl-indole-nicotinic for 10 days did not cause any signs of frustration, ache, restiveness and scraping/biting of wound location. Injury repairing is a multifaceted plus self-motivated scheme of reestablish cellular organization and tissue covering injured tissue intimately as likely to its ordinary condition. Injure contraction takes place during remedial course, commencement in fibroblastic

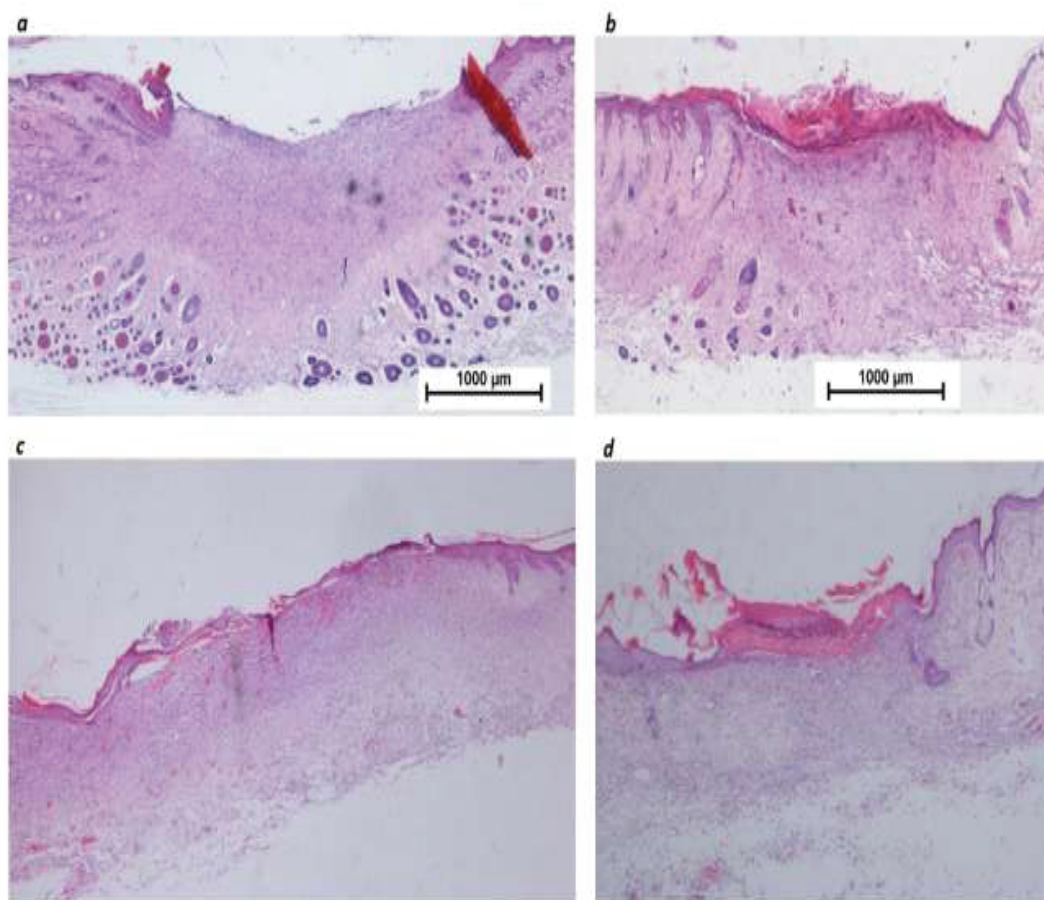
phase where the wound vicinity undertakes decrease. The propagate stage is described with angiogenesis, collagen evidence, granulation tissue development, epithelialization, and gash tightening ensuing in lesser quantity of noticeable scar tissue [29].

In this research, the outcome demonstrated that compound treated wounds established significantly hasten the speed of wound healing and prominent reduced lesion vicinity at day 10 following cutting contrast with vehicle indulgence wounds. Correspondingly, earlier research confirmed that speed up cut curing is probably owing to diminution of provocative step and its fast change to reproduce period; through improved injury reduction [26,30,31].

In the present revise, histology of injury area dressed with Cl-indole-nicotinic demonstrated increase in cellular infiltration in granulation tissue which comprised the raise in fibroblasts, well-organized buildup of collagen fibers and angiogenesis, and smaller number inflammatory cells. With the consistence to outcome of our findings, numerous co-researcher exhibited that histology assessment of dressed abrasion consist of a vast quantity of fibroblast and collagen creation, and revascularization, which effect enhanced injury tensile power with amplify speed of curative cut [23,32,33]. Likewise, superior repairing action accredited to collagen configuration and angiogenesis [24]. Injury restorative consequence may probably owed to directive of collagen manifestation and augment in tensile potency of the sore [30].

Collagen participate a vital position in the medicinal of cut and chief constituent of connective tissue and offer a organization structure for renew tissue [21,34]. Blood capillaries in granulation tissues progress flow to the injury place therefore provide oxygen and nutrients necessary for the repairing method that comprise re-epithelization [25,31,35]. Encourage epithelial cell multiplying and blood vessels are essential for injury curing progression [36].

Masson's trichrome tarnish wound part make known extraordinary



**Figure 4:** Histology slices of the injury neighborhood on day 10 after wounding (H&E mark, 2x). **a)** Topical applications of 0.2 ml CMC 2%; **(b)** Intrasite gel; **(c)** CI-indole-Nicotinic (20 mg/ml) and **(d)** CI-indole-Nicotinic (40 mg/ml). Outcome comparatively lesser sore area to negative control wounds.

enhancements in collagen evidence density and well arrangement subsequent the appliance of CI-indole-nicotinic to the wound's vicinity and was relatively superior when compared to wounds treated with vehicle. Fibroblasts create collagen in skin which acting an imperative responsibility in protecting the anatomic integrity of wound healing. Comparable outcome have been accounted by countless researchers somewhere else [4,6,26,37].

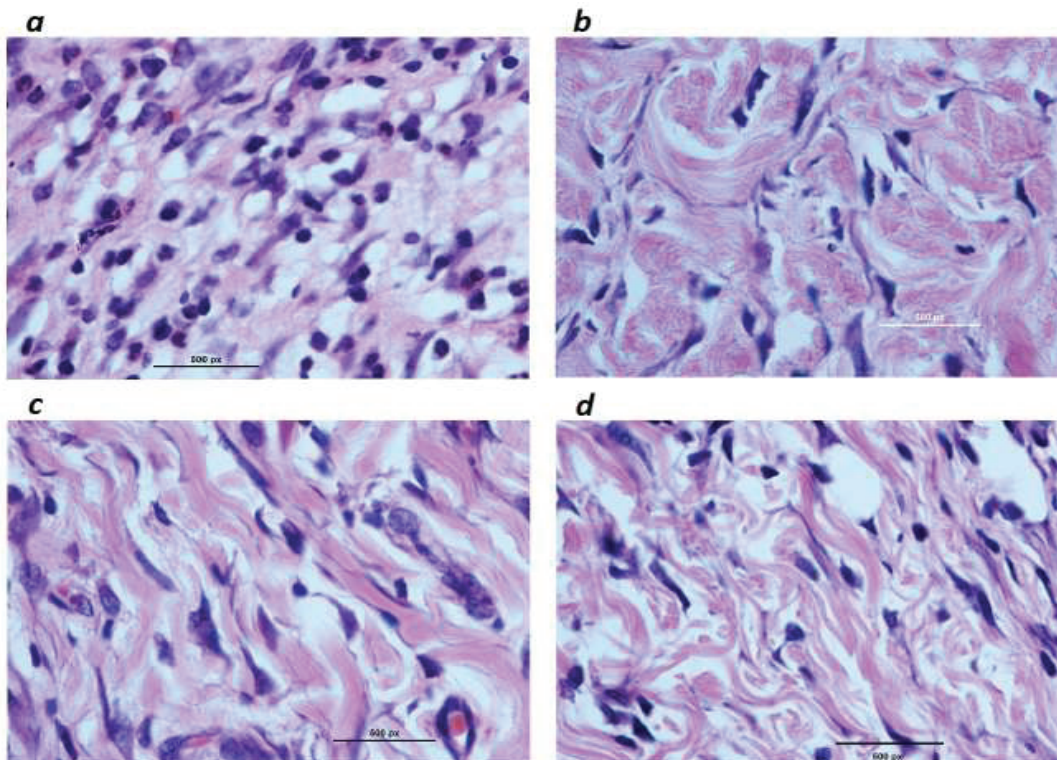
The result of our study discovered that wound tissue homogenate from rats treated with compound confirmed considerable antioxidant possessions by means of declined MDA level and by prominent activity of SOD endogenous enzyme in reply to oxidative tension. These results approved with those of preceding revision [4,10]. The decreased SOD action in the injure homogenates acquired from the vehicle extravagance wound was ascribed to the amplified construction of reactive oxygen radicals, which may possibly reduce the antioxidant motion of this enzyme [38,39]. Free radical scavenge enzymes are cytoprotective enzymes that cooperate crucial function in the decrease, neutralization and elimination of ROS, with the ruling of the hurt curing. SOD, participate a significant function reduction of oxidative anxiety persuaded via reactive oxygen species during dismutation of  $O_2$  [40]. The first protective method in opposition to reactive oxygen species is making available by SOD. SOD changed superoxide to hydrogen peroxide, which is next altered into the water by CAT in lysosomes [41]. Existence of the antioxidant properties perhaps amongst the

issues that donated to the injury repairing prospective of compound. Methods of gash curing possibly added to excite the invention of antioxidants in injure place and afford a positive surroundings for tissue curing. It has been statement that antioxidants take part in a important responsibility in the lesion therapeutic course and perhaps essential contributing issue in the cut repairing possessions, and defend tissues from oxidative injure [32,42,43].

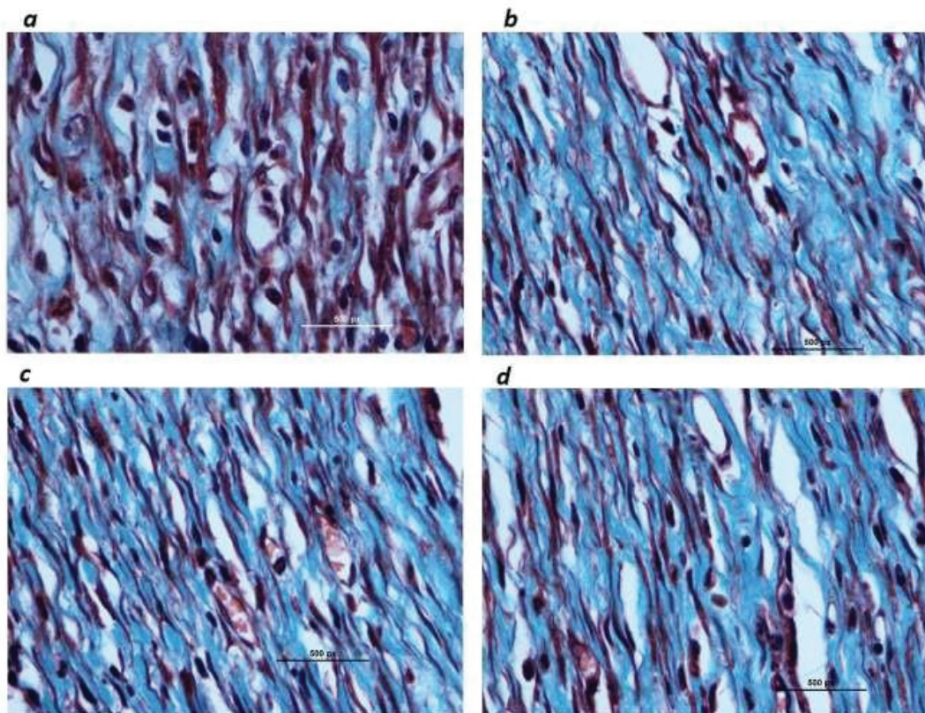
Therefore, any compounds that reduced lipid peroxidation is thought to raise the feasibility of collagen fibers by rising the power of collagen fibers, enhancing the distribution avoiding the cell harm and by encouraging the DNA production [44]. ROS are harmful to the injury curing method since of their damaging property on cells and tissues. The extreme manufacture of ROS and oxidative tension in injure locate is recognized to result lipid peroxidation in the particular tissue [11,45,46]. Lipid peroxidation of organelle and cellular membranes, being single of the harsh outcomes of oxygen radicals, is accountable deficiency in endothelial cells, fibroblast and collagen metabolism also keratinocyte capillary permeability. Additionally, the high lipid peroxidation in the cut tissue have been a causative issue injury of the gash curative process [3,47,48]. The chief oxidation result of peroxidized poly unsaturated fatty acids, MDA is a vital biomarker for lipid peroxidation [37,49].

## Conclusion

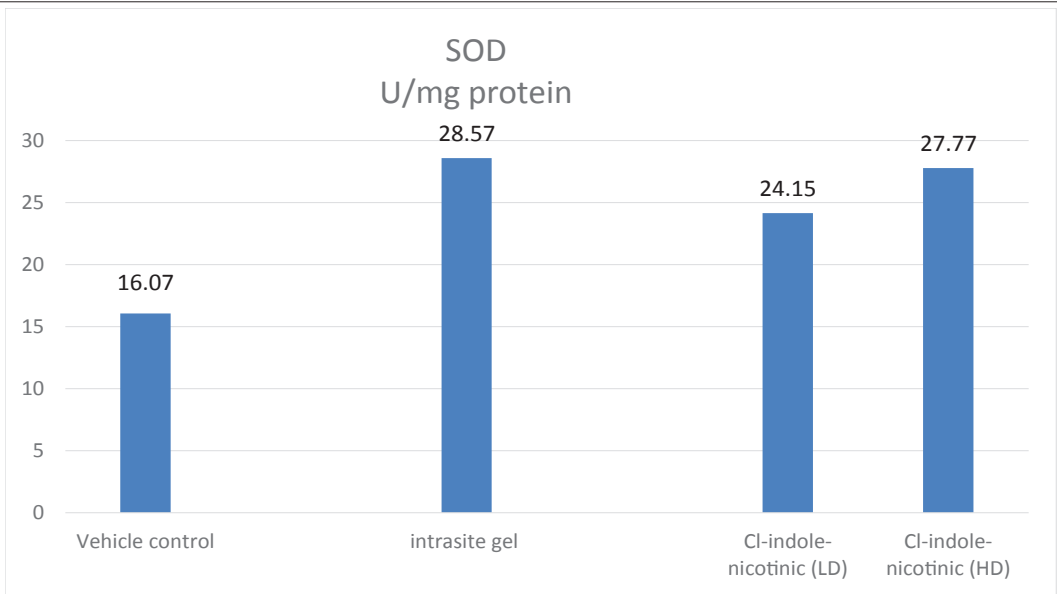




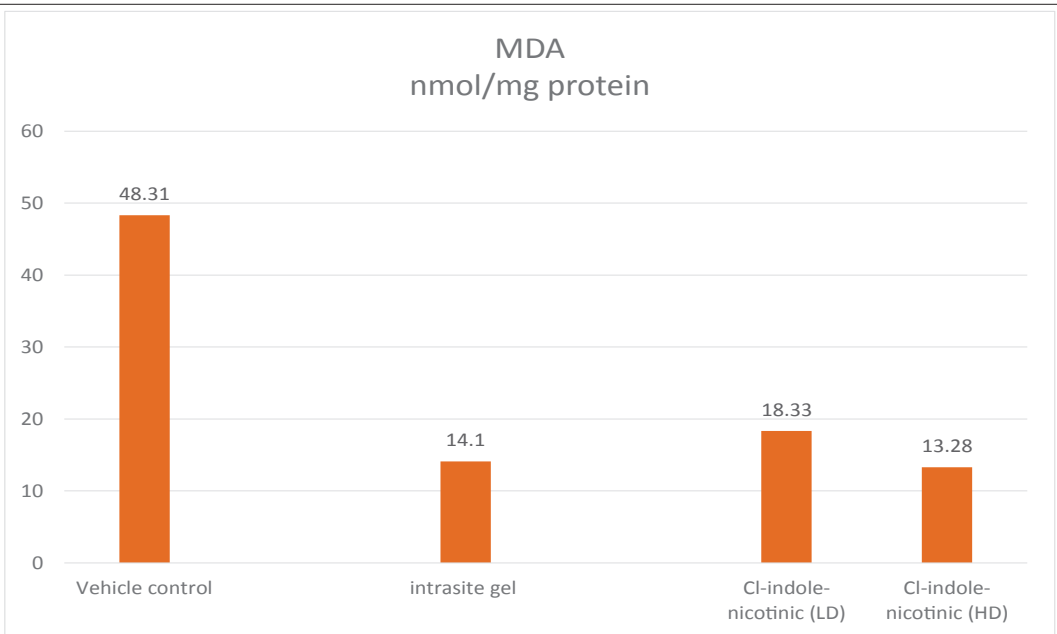
**Figure 5:** Histology segment of the repaired injury area on day 10 post-wounding (H&E stain, 100x). **a)** CMC 2%; **b)** Intracite gel; **c)** Cl-indole-Nicotinic (20 mg/ml) and **d)** Cl-indole-Nicotinic (40 mg/ml). Granulation tissue has comparatively additional collagen, fibroblasts and angiogenesis, with fewer inflammatory cells compared to CMC treated wounds.



**Figure 6:** Masson's trichrome mark of granulation tissue in the abrasion district at day 10 post-surgery (100x magnification). **a)** CMC; **b)** Intracite gel; **c)** Cl-indole-Nicotinic (20 mg/ml) and **d)** Cl-indole-Nicotinic (40 mg/ml).



**Figure 7A:** Effects of CI-indole-nicotinic on SOD activity in wound homogenate at day 10 post-wounding in the rats. All values are stated as mean  $\pm$  SD. \*Significant ( $p \leq 0.05$ ) contrast with negative control.



**Figure 7B:** Consequences of CI-indole-nicotinic on MDA level in homogenate of gash region at day 10 after surgery in rats. All values are articulated as mean  $\pm$  SD. \*Significant ( $p \leq 0.05$ ) judged against CMC cluster.

Our consequences specify that CI-indole-nicotinic improved the speed of wound healing and histology verified reasonably raises fibroblast buildup, well-organized collagen statement and additional blood capillaries, and fewer inflammatory cells in granulation tissue judge against to CMC luxury injury. Additionally, compound gets better the action endogenous antioxidant enzyme (SOD) and declines lipid peroxidation (MDA) in the injury tissue homogenate [50-52].

#### Acknowledgements

The instigators would akin to show appreciation University of Malaya for monetary sustain IPPP grant number (P0029/2012A) and UMRG grant (RPO21A-14AFR and RPO21D-14AFR) for provide grant financial support to carry out this revision.

#### References

1. Robson MC, Steed DL, Franz MG (2001) Wound healing: Biologic features and approaches to maximize healing trajectories. *Current Problems in Surgery* 38: 72-140.
2. Kumar B, Vijayakumar M, Govindarajan R, Pushpangadan P (2007) Ethnopharmacological approaches to wound healing - exploring medicinal plants of India. *Journal of Ethnopharmacology* 114: 103-113.
3. Moghadamtousi SZ, Rouhollahi E, Hajrezaie M, Karimian H, Abdulla MA, et al. (2015) *Annona muricata* leaves accelerate wound healing in rats via involvement of Hsp70 and antioxidant defense. *International Journal of Surgery* 18: 110-117.
4. Abood WN, Al-Henhena NA, Abood AN, Al-Obaidi MMJ, Ismail S, et al. (2015)

- Wound healing potential of the fruit extract of *Phaleria macrocarpa*. *Bosnia Journal of Basic Sciences* 15: 25-30.
5. Enoch S, Leaper DJ (2008) Basic science of wound healing. *Surgery (Oxford)* 26: 31-37.
  6. Amin ZA, Ali HM, Alshawsh MA, Darvish PH, Mahmood A, et al. (2015) Application of *Antrodia camphorate* Promotes Rat's Wound Healing In Vivo and Facilitates Fibroblast Cell Proliferation *In Vitro*. Evidence-Based Complementary and Alternative Medicine.
  7. Mughrabi FF, Hashim H, Mahmood AA, Khaldi H, Ali HM, et al. (2011) Effect of Bis [benzyl N'-(indol-3-ylmethylene)-hydrazinecarbodithioato]-zinc(II) derivatives on wound healing in Sprague Dawley rats. *Indian Journal of Experimental Biology* 9: 50-55.
  8. Al-Bayatya F, Abdulla MA (2012) A comparison of wound healing rate following treatment with aftamed and chlorine dioxide gels in streptozotocin-induced diabetic rats. Evidence-Based Complementary and Alternative Medicine.
  9. Al-Bayatya FH, Abdulla MA, Abu Hassana MI, Ali HM (2012) Effect of *Andrographis paniculata* leaf extract on wound healing in rats. *Natural Product Research* 26: 423-429.
  10. Dhiyaaldeen SM, Alshawsh MA, Salama SM, Al-wajeeh NSI, Al-Batran R, et al. (2014) Potential activity of 3-(2-Chlorophenyl)-1-phenyl-propenonein accelerating wound healing in rats. *BioMed Research International*.
  11. Salga MS, Ali HM, Abdulla MA, Abdelwahab SI, Hussain PD, et al. (2011) Mechanistic studies of the anti-ulcerogenic activity and acute toxicity evaluation of dichlorido-copper (II)-4-(2-5-bromobenzylideneamino) ethyl) piperazin-1-ium phenolate complex against ethanol- induced gastric injury in rats. *Molecules* 16: 8654-8669.
  12. Gwaram NS, Musalam L, Ali HM, Abdulla MA (2012) Synthesis of 2'-(5-Chloro-2-Hydroxybenzylidene) Benzenesulfanohydrazone Schiff Base and its Anti-Ulcer Activity in Ethanol- Induced Gastric Mucosal Lesions in Rats. *Tropical Journal of Pharmaceutical Research* 11: 251- 257.
  13. Hashim H, Mughrabi FF, Abdulla MA, Khaledi H, Ali HM (2012) Cytoprotective Effect of Benzyl N'-(5-Chloro-indol-3-ylmethylidene)-hydrazinecar-bodithioate Against Ethanol-Induced Gastric Mucosal Injury in Rats. *Molecules* 17: 9306-9320.
  14. Golbabapour S, Gwaram NS, Hassandarvish P, Hajrezaie M, Kamalidehghan B, et al. (2013) Gastroprotection Studies of Schiff Base Zinc (II) Derivative Complex against Acute Superficial Hemorrhagic Mucosal Lesions in Rats. *PLoS ONE* 8: e75036.
  15. Halabi MF, Shakir RM, Bardi DA, Al-Wajeeh NS, Ablat A, et al. (2014) Gastroprotective Activity of Ethyl-4-[(3,5-di-tert-butyl-2- hydroxybenzylidene) Amino]benzoate against Ethanol-Induced Gastric Mucosal Ulcer in Rats. *PLoS ONE* 9: e95908.
  16. Beshir AB, Guchhait SK, Gascón JA, Fenteany G (2008) Synthesis and structure-activity relationships of metal-ligand complexes that potently inhibit cell migration. *Bioorganic & Medicinal Chemistry Letters* 18: 498-504.
  17. Chakraborty A, Kumar P, Ghosh K, Roy P (2010) Evaluation of a Schiff base copper complex compound as potent anticancer molecule with multiple targets of action. *European Journal of Pharmacology* 647: 1-12.
  18. Hajrezaie M, Paydar MJ, Moghadamtousi SZ, Hassandarvish P, Gwaram NS, et al. (2014) A Schiff Base-Derived Copper (II) Complex Is a Potent Inducer of Apoptosis in Colon Cancer Cells by Activating the Intrinsic Pathway. *The Scientific World Journal*.
  19. Khattab SN (2005) Synthesis and Biological Activity of Novel Amino Acid-(N'-Benzoyl) Hydrazide and Amino Acid-(N'-Nicotinoyl) Hydrazide Derivatives. *Molecules* 10: 1218-1228.
  20. Odunola OA, Adeoye IO, Woods JAO (2002) Synthesis and Structural Features of Copper(II) complexes of Benzoic Acid and Methyl Substituted Benzoic Acid Hydrazides and X-Ray Structure of Cu[C<sub>6</sub>H<sub>5</sub>CONHNH<sub>2</sub>]<sub>2</sub>(NO<sub>3</sub>)<sub>2</sub>. Synthesis and Reactivity in Inorganic and Metal-Organic Chemistry 32: 801-817.
  21. Tan MK, Hasan Adli DS, Tumiran MA, Abdulla MA, Yusoff KM (2012) The efficacy of Gelam honey dressing towards excisional wound healing. Evidence-Based Complementary and Alternative Medicine. Volume 2012.
  22. Abdulla MA, Ahmed KAA, Abu-Luhoom FM, Muhanid M (2010) Role of *Ficus deltoidea* extract in the enhancement of wound healing in experimental rats. *Biomedical Research* 21: 241- 245.
  23. Mahmood AA, Mariod AA, Abdelwahab SI, Ismail S, Al-Bayatya F (2010) Potential activity of ethanolic extract of *Boesenbergia rotunda* (L.) rhizomes extract in accelerating wound healing in rats. *Journal of Medicinal Plants Research* 4: 1570-1576.
  24. Abdulla MA, Fard AA, Sabaratnam V, Wong KH, Kuppusamy UR, et al. (2011) Potential activity of aqueous extract of culinary-medicinal Lion's Mane mushroom, *Hericium erinaceus* (Bull.: Fr.) Pers. (Aphyllophoromycetideae) in accelerating wound healing in rats. *International Journal of Medicinal Mushrooms* 13: 33-39.
  25. Al-Henhena N, Mahmood AA, Al-magrami A, Syuhada ABN, Zahra AA, et al. (2011) Histological study of wound healing potential by ethanol leaf extract of *Strobilanthes crispus* in rats. *Journal of Medicinal Plant Research* 5: 3660-3666.
  26. Cheng PG, Phan CW, Sabaratnam V, Abdullah N, Abdulla MA, et al. (2013) Polysaccharides-Rich Extract of *Ganoderma lucidum* (M.A. Curtis:Fr) P. Karst Accelerates Wound Healing in Streptozotocin-Induced Diabetic Rats. Evidence-Based Complementary and Alternative Medicine.
  27. Hajrezaie M, Golbabapour S, Hassandarvish P, Gwaram NS, Hadi AHA, et al. (2011) Acute Toxicity and Gastroprotection Studies of a New Schiff Base Derived Copper (II) Complex against Ethanol-Induced Acute Gastric Lesions in Rats. *PLoS ONE* 7: e51537.
  28. Hajrezaie M, Salehen NA, Karimian H, Zahedifard M, Shams K, et al. (2015) Biochanin A Gastroprotective Effects in Ethanol-Induced Gastric Mucosal Ulceration in Rats. *PLoS ONE* 10: e0121529.
  29. Hajiaghaalipour F, Kanthimathi MS, Abdulla MA, Sanusi J (2013) The Effect of *Camellia sinensis* on Wound Healing Potential in an Animal Mode. Evidence-Based Complementary and Alternative Medicine.
  30. Abdulla MA, Ahmed KA, Ali HM, Noor SM, Ismail S (2009) Wound Healing Activities of *Rafflesia Hasseltii* Extract in Rats. *Journal of Clinical Biochemistry and Nutrition*. 45: 304-308.
  31. Zahra AA, Kadir FA, Mahmood AA, Al Hadi AA, Suzy SM, et al. (2011) Acute toxicity study and wound healing potential of *Gynura procumbens* leaf extract in rats. *Journal of Medicinal Plant Research* 5: 2551-2558.
  32. Habibipour S, Oswald TM, Zhang F, Joshi P, Zhou XC, et al. (2003) Effect of sodium diphenylhydantoin on skin wound healing in rats. *Plastic and Reconstructive Surgery* 112: 1620-1627.
  33. Mughrabi FF, Hashim H, Mahmood AA, Suzy SM, Salmah I, et al. (2014) Acceleration of wound healing activity by *Polygonatum odoratum* leaf extract in rats. *Journal of Medicinal Plant Research* 8: 523-528.
  34. Bonte F, Dumas M, Chaudagne C, Meybeck A (1994) Influence of asiatic acid, madecassic acid, and asiaticoside on human collagen I synthesis. *Planta Medica*. 60: 133-135.
  35. Suguna L, Sivakumar P, Chandrakasan G (1996) Effects of *Centella asiatica* extract on dermal wound healing in rats. *Indian Journal of Experimental Biology* 34: 1208-1211.
  36. Cohen IK, Diegelmann FR, Lindblad JW (1992) Wound healing: biochemical and clinical aspects. *Plastic and Reconstructive Surgery*. 90: 926.
  37. Rouhollahi E, Moghadamtousi SZ, Hajiaghaalipour F, Zahedifard M, Tayeb F, et al. (2015) *Curcuma purpurascens* Bi. rhizome accelerates rat excisional wound healing: involvement of hsp70/Bax proteins, antioxidant defense, and angiogenesis activity. *Drug Design, Development and Therapy* 9: 5805-5813.
  38. El-Razek FHA, El- Metwally EM, Shehab GMG, Hassan AA, Gomaa, AM (2012) Effects of cactus pear (*Opuntia ficus indica*) juice on oxidative stress in diabetic cataract rats. *Saudi Journal of Health Sciences* 1: 23-29.
  39. Salama SM, Gwaram NS, AlRashdi AS, Khalifa SAM, Abdulla MA, et al. (2016) A zinc morpholine complex prevents HCl/ethanol-induced gastric ulcers in a rat model. *Scientific Reports*. 6: 29646.
  40. Singh M, Sandhir R, Kiran R (2011) Effects on antioxidant status of liver following atrazine exposure and its attenuation by vitamin E. *Experimental Toxicology Pathology* 63: 269-276.
  41. Johansen JS, Harris AK, Rychly DJ, Ergul A (2005) Oxidative stress and the use of antioxidants in diabetes: linking basic science to clinical practice. *Cardiovascular Diabetology* 4: 5.
  42. Shukla A, Rasik AM, Dhawan BN (1999) Asiaticoside induced elevation of antioxidant levels in healing wounds. *Phytotherapy Research* 13: 50-54.
  43. Ketuly KA, Hadi AHA, Golbabapour S, Hajrezaie M, Hassandarvish P, et al. (2013) Acute toxicity and gastroprotection studies with a newly synthesized



- steroid. *PLoS ONE* 8: e59296.
44. Buntrock P, Jentsch KD, Heder G (1982) Stimulation of wound healing, using brain extracts with fibroblast growth factor (FGF) activity II. Histological and morphometric examination of cells and capillaries. *Experimental Pathology*. 21: 62-67.
45. Adibhatla RM, Hatcher JF (2006) Phospholipase A2, reactive oxygen species, and lipid peroxidation in cerebral ischemia. *Free Radical Biology and Medicine* 40: 376-387.
46. Tayeb F, Salman AAA, Kamran S, Khaing SL, Salehen NA, et al. (2018) Ulcer Prevention Effect of 3,4,5-Trihydroxy-N0-[(2-Methyl-1H-Indol-3yl)Methylidene] Benzohydrazide in HCl/Ethanol-Induced Gastric Mucosal Damage in Rats. *International Journal of Medical Sciences* 14: 1317-1326.
47. Altavilla D, Saitta A, Cucinotta D, Galeano M, Deodato B, et al. (2001) Inhibition of lipid peroxidation restores impaired vascular endothelial growth factor expression and stimulates wound healing and angiogenesis in the genetically diabetic mouse. *Diabetes* 50: 667-674.
48. Gwaram NS, Musalam L, Ali HM, Abdulla MA, Shaker SA (2016) Synthesis, spectral characterization and biological activity of Zn(II) complex with 2'-[1-(2-hydroxyphenyl) ethylidene] benzenesulfanohydrazide. *Arabian Journal of Chemistry* 9: S1197-S1207.
49. Elia A, Waller W, Norton S (2002) Biochemical responses of Bluegill Sunfish (*Lepomis macrochirus*, Rafinesque) to atrazine induced oxidative stress. *Bulletin of Environmental Contamination and Toxicology* 68: 809-816.
50. Hajiaghaalipour F, Faraj FL, Bagherie E, Khaledi H, Ali HM, et al. (2018) Synthesis and Characterization of a New Benzo Indole Derivative with Apoptotic Activity Against Colon Cancer Cells. *Current Pharmaceutical Design* 23: 1-10.
51. Ibrahim MM, Ali HM, Abdulla MA, Hassandarvish P (2012) Acute Toxicity and Gastroprotective Effect of the Schiff Base Ligand 1H-Indole-3-ethylene-5-nitrosalicylalimine and Its Nickel (II) Complex on Ethanol-Induced Gastric Lesions in Rats. *Molecules* 17: 12449-12459.
52. Mustafa IM, Hapipah MA, Abdulla MA, Ward TR (2009) Synthesis, structural characterization, and anti-ulcerogenic activity of Schiff base ligands derived from tryptamine and 5-chloro, 5-nitro, 3,5-ditertiarybutyl salicylaldehyde and their nickel (II), copper (II), and zinc (II) complexes. *Polyhedron* 28: 3993-3998.